

# Oral Cavity and Gastrointestinal Tract

## CHAPTER CONTENTS

### **ORAL CAVITY 551**

Oral Inflammatory Lesions	552
Aphthous Ulcers (Canker Sores)	552
Herpes Simplex Virus Infections	552
Oral Candidiasis (Thrush)	552
Proliferative and Neoplastic Lesions of the Oral Cavity	552
Fibrous Proliferative Lesions	552
Leukoplakia and Erythroplakia	553
Squamous Cell Carcinoma	554
Diseases of Salivary Glands	555
Xerostomia	555
Sialadenitis	555
Neoplasms	555
Odontogenic Cysts and Tumors	557
<b>ESOPHAGUS 558</b>	
Obstructive and Vascular Diseases	558
Mechanical Obstruction	558
Functional Obstruction	558
Ectopia	558
Esophageal Varices	559
Esophagitis	559
Lacerations	559

Chemical and Infectious Esophagitis	560
Reflux Esophagitis	560
Eosinophilic Esophagitis	561
Barrett Esophagus	561
Esophageal Tumors	562
Adenocarcinoma	562
Squamous Cell Carcinoma	563

### **STOMACH 564**

Inflammatory Disease of the Stomach	564
Acute Gastritis	564
Acute Peptic Ulceration	565
Chronic Gastritis	566
Peptic Ulcer Disease	568
Neoplastic Disease of the Stomach	569
Gastric Polyps	569
Gastric Adenocarcinoma	570
Lymphoma	571
Carcinoid Tumor	571
Gastrointestinal Stromal Tumor	572

### **SMALL AND LARGE INTESTINES 573**

Intestinal Obstruction	573
------------------------	-----

Hirschsprung Disease	573
Abdominal Hernia	574
Vascular Disorders of Bowel	574
Ischemic Bowel Disease	574
Hemorrhoids	576
Diarrheal Disease	576
Malabsorptive Diarrhea	576
Infectious Enterocolitis	580
Inflammatory Intestinal Disease	586
Sigmoid Diverticulitis	586
Inflammatory Bowel Disease	587
Colonic Polyps and Neoplastic Disease	592
Inflammatory Polyps	592
Hamartomatous Polyps	592
Hyperplastic Polyps	593
Adenomas	593
Familial Syndromes	595
Adenocarcinoma	596
<b>APPENDIX 600</b>	
Acute Appendicitis	600
Tumors of the Appendix	601

The gastrointestinal tract is a hollow tube consisting of the esophagus, stomach, small intestine, colon, rectum, and anus. Each region has unique, complementary, and highly integrated functions that together serve to regulate the intake, processing, and absorption of ingested nutrients and the disposal of waste products. The intestines also are the principal site at which the immune system interfaces with a diverse array of antigens present in food and gut microbes. Thus, it is not surprising that the

small intestine and colon frequently are involved by infectious and inflammatory processes. Finally, the colon is the most common site of gastrointestinal neoplasia in Western populations. In this chapter we discuss the diseases that affect each section of the gastrointestinal tract. Disorders that typically involve more than one segment, such as Crohn disease, are considered with the most frequently involved region.

## **ORAL CAVITY**

Pathologic conditions of the oral cavity can be broadly divided into diseases affecting the oral mucosa, salivary glands, and jaws. Discussed next are the more common conditions affecting these sites. Although common,

disorders affecting the teeth and supporting structures are not considered here. Reference should be made to specialized texts. Odontogenic cysts and tumors (benign and malignant), which are derived from the epithelial and/or

mesenchymal tissues associated with tooth development, also are discussed briefly.

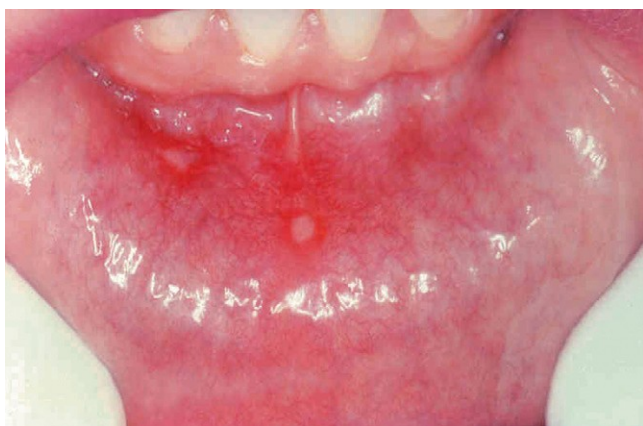## ORAL INFLAMMATORY LESIONS

### Aphthous Ulcers (Canker Sores)

These common superficial mucosal ulcerations affect up to 40% of the population. They are more common in the first two decades of life, extremely painful, and recurrent. Although the cause of aphthous ulcers is not known, they do tend to be more prevalent within some families and may be associated with celiac disease, inflammatory bowel disease (IBD), and Behçet disease. Lesions can be solitary or multiple; typically, they are shallow, hyperemic ulcerations covered by a thin exudate and rimmed by a narrow zone of erythema (Fig. 14-1). In most cases they resolve spontaneously in 7 to 10 days but can recur.

### Herpes Simplex Virus Infections

Most orofacial herpetic infections are caused by herpes simplex virus type 1 (HSV-1), with the remainder being caused by HSV-2 (genital herpes). With changing sexual practices, oral HSV-2 is increasingly common. Primary infections typically occur in children between 2 and 4 years of age and are often asymptomatic. However, in 10% to 20% of cases the primary infection manifests as *acute herpetic gingivostomatitis*, with abrupt onset of vesicles and ulcerations throughout the oral cavity. Most adults harbor latent HSV-1, and the virus can be reactivated, resulting in a so-called “cold sore” or *recurrent herpetic stomatitis*. Factors associated with HSV reactivation include trauma, allergies, exposure to ultraviolet light, upper respiratory tract infections, pregnancy, menstruation, immunosuppression, and exposure to extremes of temperature. These recurrent lesions, which occur at the site of primary inoculation or in adjacent mucosa innervated by the same ganglion, typically appear as groups of small (1 to 3 mm) vesicles. The lips (herpes labialis), nasal orifices, buccal mucosa, gingiva, and hard palate are the most common locations. Although



**Figure 14-1** Aphthous ulcer. Single ulceration with an erythematous halo surrounding a yellowish fibrinopurulent membrane.

lesions typically resolve within 7 to 10 days, they can persist in immunocompromised patients, who may require systemic antiviral therapy. Morphologically, the lesions resemble those seen in esophageal herpes (see Fig. 14-8) and genital herpes (Chapter 17). The infected cells become ballooned and have large eosinophilic intranuclear inclusions. Adjacent cells commonly fuse to form large multinucleated polykaryons.

### Oral Candidiasis (Thrush)

Candidiasis is the most common fungal infection of the oral cavity. *Candida albicans* is a normal component of the oral flora and only produces disease under unusual circumstances. Modifying factors include:

- Immunosuppression
- The strain of *C. albicans*
- The composition of the oral microbial flora (microbiota)

Broad-spectrum antibiotics that alter the normal microbiota can also promote oral candidiasis. The three major clinical forms of oral candidiasis are pseudomembranous, erythematous, and hyperplastic. The pseudomembranous form is most common and is known as *thrush*. This condition is characterized by a superficial, curdlike, gray to white inflammatory membrane composed of matted organisms enmeshed in a fibrinosuppurative exudate that can be readily scraped off to reveal an underlying erythematous base. In mildly immunosuppressed or debilitated individuals, such as diabetics, the infection usually remains superficial, but can spread to deep sites in association with more severe immunosuppression, including that seen in organ or hematopoietic stem cell transplant recipients, as well as patients with neutropenia, chemotherapy-induced immunosuppression, or AIDS.

## SUMMARY

### Oral Inflammatory Lesions

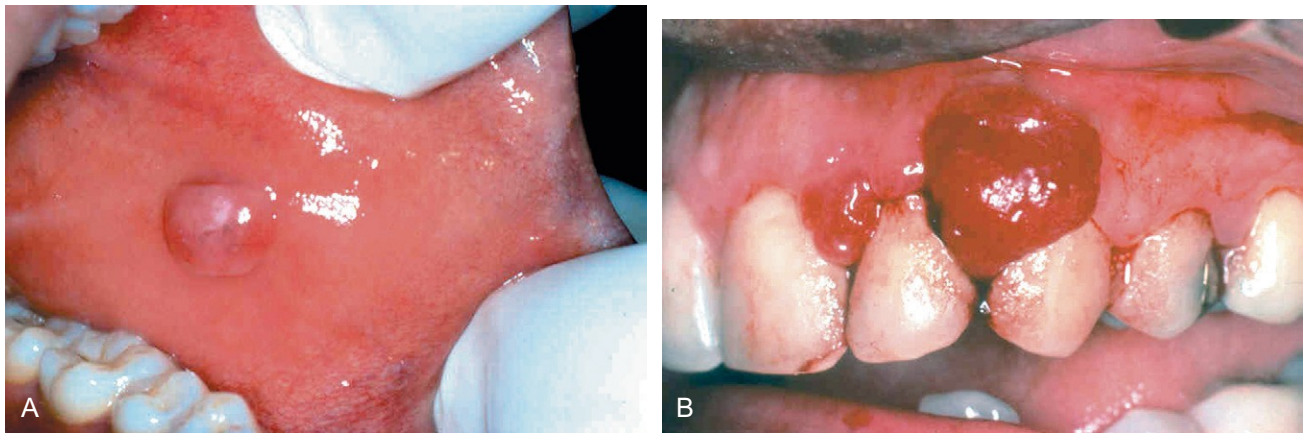
- *Aphthous ulcers* are painful superficial ulcers of unknown etiology that may be associated with systemic diseases.
- *Herpes simplex virus* causes a self-limited infection that presents with vesicles (cold sores, fever blisters) that rupture and heal, without scarring, and often leave latent virus in nerve ganglia. Reactivation can occur.
- *Oral candidiasis* may occur when the oral microbiota is altered (e.g., after antibiotic use). Invasive disease may occur in immunosuppressed individuals.

## PROLIFERATIVE AND NEOPLASTIC LESIONS OF THE ORAL CAVITY

### Fibrous Proliferative Lesions

*Fibromas* (Fig. 14-2, A) are submucosal nodular fibrous tissue masses that are formed when chronic irritation results in reactive connective tissue hyperplasia. They





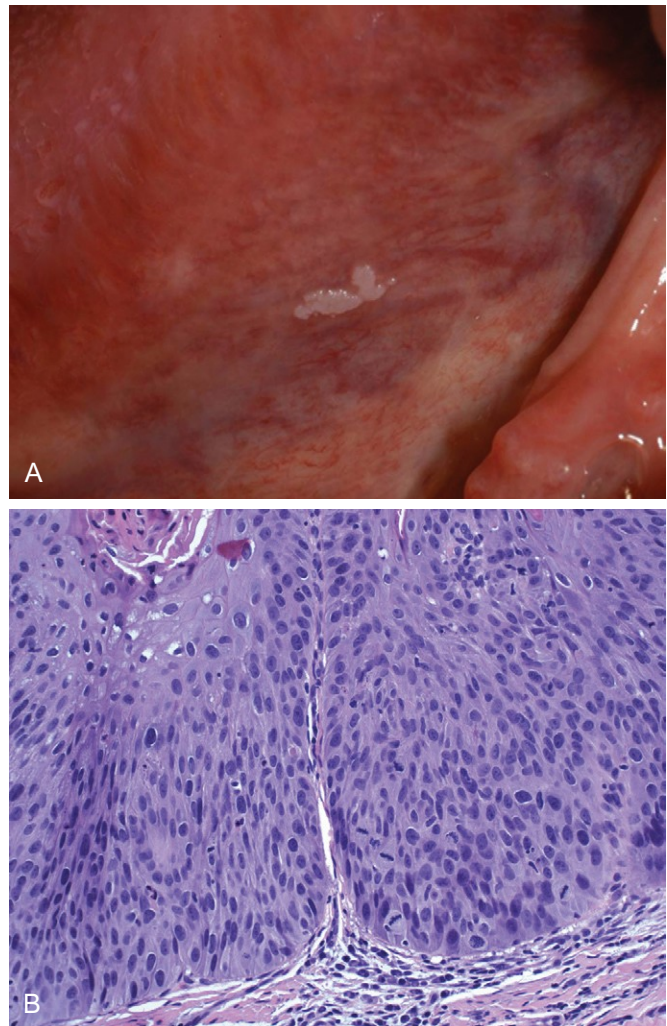
**Figure 14-2** Fibrous proliferations. **A**, Fibroma. Smooth pink exophytic nodule on the buccal mucosa. **B**, Pyogenic granuloma. Erythematous hemorrhagic exophytic mass arising from the gingival mucosa.

occur most often on the buccal mucosa along the bite line and are thought to be reactions to chronic irritation. Treatment is complete surgical excision and removal of the source of irritation.

*Pyogenic granulomas* (Fig. 14-2, B) are pedunculated masses usually found on the gingiva of children, young adults, and pregnant women. These lesions are richly vascular and typically are ulcerated, which gives them a red to purple color. In some cases, growth can be rapid and raise fear of a malignant neoplasm. However, histologic examination demonstrates a dense proliferation of immature vessels similar to that seen in granulation tissue. Pyogenic granulomas can regress, mature into dense fibrous masses, or develop into a peripheral ossifying fibroma. Complete surgical excision is definitive treatment.

### Leukoplakia and Erythroplakia

*Leukoplakia* is defined by the World Health Organization as “a white patch or plaque that cannot be scraped off and cannot be characterized clinically or pathologically as any other disease.” This clinical term is reserved for lesions that arise in the oral cavity in the absence of any known etiologic factor (Fig. 14-3, A). Accordingly, white patches caused by obvious irritation or entities such as lichen planus and candidiasis are not considered leukoplakia. Approximately 3% of the world’s population has leukoplakic lesions, of which 5% to 25% are premalignant and may progress to squamous cell carcinoma. Thus, until proved otherwise by means of histologic evaluation, all leukoplakias must be considered precancerous. A related but less common lesion, *erythroplakia*, is a red, velvety, possibly eroded area that is flat or slightly depressed relative to the surrounding mucosa. Erythroplakia is associated with a much greater risk of malignant transformation than leukoplakia. While leukoplakia and erythroplakia may be seen in adults at any age, they typically affect persons between the ages of 40 and 70 years, with a 2:1 male preponderance. Although the etiology is multifactorial, tobacco use (cigarettes, pipes, cigars, and chewing tobacco) is the most common risk factor for leukoplakia and erythroplakia.



**Figure 14-3** Leukoplakia. **A**, Clinical appearance of leukoplakia is highly variable. In this example, the lesion is smooth with well-demarcated borders and minimal elevation. **B**, Histologic appearance of leukoplakia showing dysplasia, characterized by nuclear and cellular pleomorphism and loss of normal maturation.

## MORPHOLOGY

**Leukoplakia** includes a spectrum of histologic features ranging from **hyperkeratosis** overlying a thickened, acanthotic, but orderly mucosal lesions with marked **dysplasia** that sometimes merges with **carcinoma in situ** (Fig. 14-3, B). The most severe dysplastic changes are associated with erythroplakia, and more than 50% of these cases undergo malignant transformation. With increasing dysplasia and anaplasia, a subjacent inflammatory cell infiltrate of lymphocytes and macrophages is often present.

## Squamous Cell Carcinoma

Approximately 95% of cancers of the oral cavity are squamous cell carcinomas, with the remainder largely consisting of adenocarcinomas of salivary glands, as discussed later. This aggressive epithelial malignancy is the sixth most common neoplasm in the world today. Despite numerous advances in treatment, the overall long-term survival rate has been less than 50% for the past 50 years. This dismal outlook is due to several factors, most notably the fact that oral cancer often is diagnosed at an advanced stage.

Multiple primary tumors may be present at initial diagnosis but more often are detected later, at an estimated rate of 3% to 7% per year; patients who survive 5 years after diagnosis of the initial tumor have up to a 35% chance of developing at least one new primary tumor within that interval. The development of these secondary tumors can be particularly devastating for persons whose initial lesions were small. Thus, despite a 5-year survival rate greater than 50% for patients with small tumors, these patients often die of second primary tumors. Therefore, surveillance and early detection of new premalignant lesions are critical for the long-term survival of patients with oral squamous cell carcinoma.

The elevated risk of additional primary tumors in these patients has led to the concept of “field cancerization.” This hypothesis suggests that multiple primary tumors develop independently as a result of years of chronic mucosal exposure to carcinogens such as alcohol or tobacco (described next).

## PATHOGENESIS

Squamous cancers of the oropharynx arise through two distinct pathogenic pathways. One group of tumors in the oral cavity occurs mainly in persons who are chronic alcohol and tobacco (both smoked and chewed) users. Deep sequencing of these cancers has revealed frequent mutations that bear a molecular signature consistent with exposure to carcinogens in tobacco. These mutations frequently involve *TP53* and genes that regulate the differentiation of squamous cells, such as *p63* and *NOTCH1*. The second group of tumors tends to occur in the tonsillar crypts or the base of the tongue and harbor oncogenic variants of human papillomavirus (HPV), particularly HPV-16. These tumors carry far fewer mutations than those associated with tobacco exposure and often overexpress p16, a cyclin-dependent kinase inhibitor. It is

predicted that the incidence of HPV-associated oropharyngeal squamous cell carcinoma will surpass that of cervical cancer in the next decade, in part because the anatomic sites of origin—tonsillar crypts, base of tongue, and oropharynx—are not readily accessible or amenable to cytologic screening (unlike the cervix). Notably, the **prognosis for patients with HPV-positive tumors is better than for those with HPV-negative tumors**. The HPV vaccine, which is protective against cervical cancer, offers hope to limit the increasing frequency of HPV-associated oropharyngeal squamous cell carcinoma.

In India and southeast Asia, chewing of betel quid and paan are important predisposing factors. Betel quid is a “witch’s brew” containing araca nut, slaked lime, and tobacco, all wrapped in betel nut leaf. It is likely that these tumors arise by a pathway similar to that characterized for tobacco use-associated tumors in the West.

## MORPHOLOGY

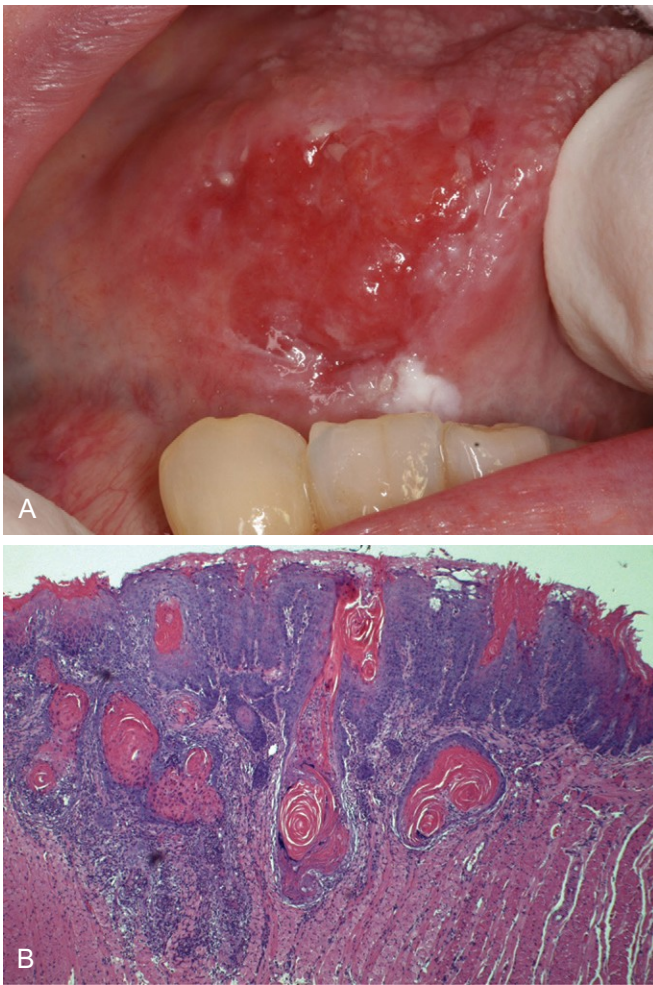
Squamous cell carcinoma may arise anywhere in the oral cavity. However, **the most common locations are the ventral surface of the tongue, floor of the mouth, lower lip, soft palate, and gingiva** (Fig. 14-4, A). In early stages, these cancers can appear as raised, firm, pearly plaques or as irregular, roughened, or verrucous mucosal thickenings. Either pattern may be superimposed on a background of a leukoplakia or erythroplakia. As these lesions enlarge, they typically form ulcerated and protruding masses that have irregular and indurated or rolled borders. Histopathologic analysis has shown that **squamous cell carcinoma develops from dysplastic precursor lesions**. Histologic patterns **range from well-differentiated keratinizing neoplasms** (Fig. 14-4, B) **to anaplastic, sometimes sarcomatoid tumors**. However, the degree of histologic differentiation, as determined by the relative degree of keratinization, does not necessarily correlate with biologic behavior. Typically, oral squamous cell carcinoma infiltrates locally before it metastasizes. The cervical lymph nodes are the most common sites of regional metastasis; frequent sites of distant metastases include the mediastinal lymph nodes, lungs, and liver.

## SUMMARY

### Lesions of the Oral Cavity

- *Fibromas* and *pyogenic granulomas* are common reactive lesions of the oral mucosa.
- *Leukoplakias* are mucosal plaques that may undergo malignant transformation.
- The risk of malignant transformation is greater in *erythroplakia* (relative to leukoplakia).
- A majority of oral cavity cancers are *squamous cell carcinomas*.
- Oral squamous cell carcinomas are classically linked to tobacco and alcohol use, but the incidence of HPV-associated lesions is rising.





**Figure 14-4** Oral squamous cell carcinoma. **A**, Clinical appearance demonstrating ulceration and induration of the oral mucosa. **B**, Histologic appearance demonstrating numerous nests and islands of malignant keratinocytes invading the underlying connective tissue stroma.

## DISEASES OF SALIVARY GLANDS

There are three major salivary glands—parotid, submandibular, and sublingual—as well as innumerable minor salivary glands distributed throughout the oral mucosa. Inflammatory or neoplastic disease may develop within any of these.

### Xerostomia

Xerostomia is defined as a *dry mouth* resulting from a decrease in the production of saliva. Its incidence varies among populations, but has been reported in more than 20% of individuals above the age of 70 years. It is a major feature of the autoimmune disorder Sjögren syndrome, in which it usually is accompanied by dry eyes (Chapter 4). A lack of salivary secretions is also a major complication of radiation therapy. However, xerostomia is most frequently observed as a result of many commonly prescribed classes of medications including anticholinergic, antidepressant/antipsychotic, diuretic, antihypertensive, sedative, muscle

relaxant, analgesic, and antihistaminic agents. The oral cavity may merely reveal dry mucosa and/or atrophy of the papillae of the tongue, with fissuring and ulcerations, or, in Sjögren syndrome, concomitant inflammatory enlargement of the salivary glands. Complications of xerostomia include increased rates of dental caries and candidiasis, as well as difficulty in swallowing and speaking.

### Sialadenitis

Sialadenitis, or inflammation of the salivary glands, may be induced by trauma, viral or bacterial infection, or autoimmune disease. The most common form of *viral sialadenitis* is *mumps*, which may produce enlargement of all salivary glands but predominantly involves the parotids. The mumps virus is a paramyxovirus related to the influenza and parainfluenza viruses. Mumps produces interstitial inflammation marked by a mononuclear inflammatory infiltrate. While mumps in children is most often a self-limited benign condition, in adults it can cause pancreatitis or orchitis; the latter sometimes causes sterility.

The *mucocele* is the most common inflammatory lesion of the salivary glands, and results from either blockage or rupture of a salivary gland duct, with consequent leakage of saliva into the surrounding connective tissue stroma. Mucocele occurs most often in toddlers, young adults, and the aged, and typically manifests as a fluctuant swelling of the lower lip that may change in size, particularly in association with meals (Fig. 14-5, A). Histologic examination demonstrates a cystlike space lined by inflammatory granulation tissue or fibrous connective tissue that is filled with mucin and inflammatory cells, particularly macrophages (Fig. 14-5, B). Complete excision of the cyst and the minor salivary gland lobule constitutes definitive treatment.

*Bacterial sialadenitis* is a common infection that most often involves the major salivary glands, particularly the submandibular glands. The most frequent pathogens are *Staphylococcus aureus* and *Streptococcus viridans*. Duct obstruction by stones (*sialolithiasis*) is a common antecedent to infection; it may also be induced by impacted food debris or by edema consequent to injury. Dehydration and decreased secretory function also may predispose to bacterial invasion and sometimes are associated with long-term phenothiazine therapy, which suppresses salivary secretion. Systemic dehydration, with decreased salivary secretions, may predispose to suppurative bacterial parotitis in elderly patients following major thoracic or abdominal surgery. This obstructive process and bacterial invasion lead to a nonspecific inflammation of the affected glands that may be largely interstitial or, when induced by staphylococcal or other pyogens, may be associated with overt suppurative necrosis and abscess formation.

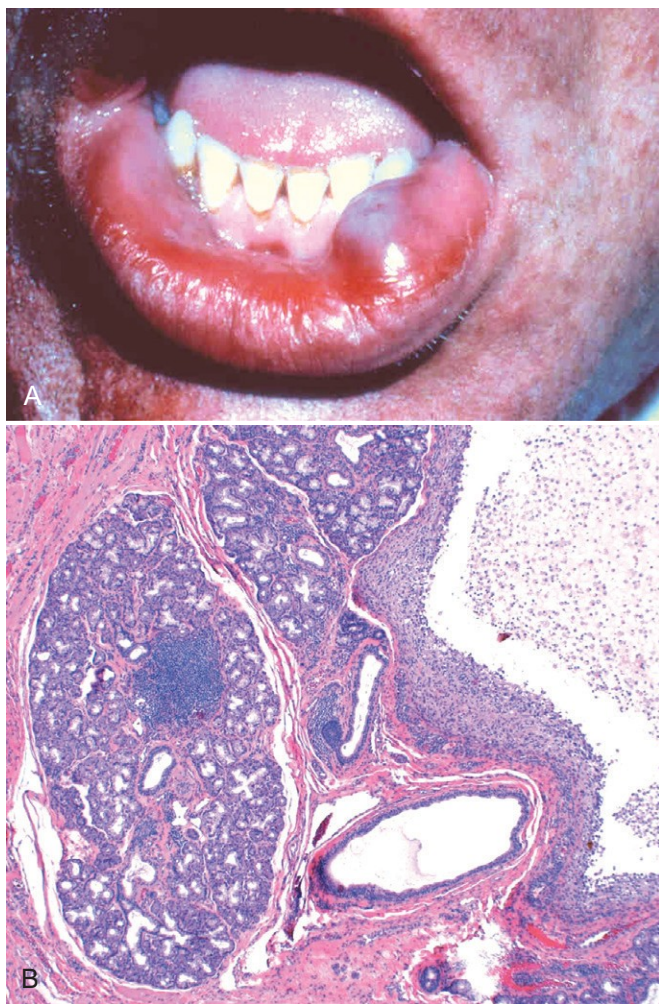
Autoimmune sialadenitis, also called Sjögren syndrome, is discussed in Chapter 4.

### Neoplasms

Despite their relatively simple morphology, the salivary glands give rise to at least 30 histologically distinct tumors. As indicated in Table 14-1, a small number of these neoplasms account for more than 90% of tumors. Overall,

salivary gland tumors are relatively uncommon and represent less than 2% of all human tumors. Approximately 65% to 80% arise within the parotid, 10% in the submandibular gland, and the remainder in the minor salivary glands, including the sublingual glands. Approximately 15% to 30% of tumors in the parotid glands are malignant. By contrast, approximately 40% of submandibular, 50% of minor salivary gland, and 70% to 90% of sublingual tumors are cancerous. Thus, the likelihood that a salivary gland tumor is malignant is inversely proportional, roughly, to the size of the gland.

Salivary gland tumors usually occur in adults, with a slight female predominance, but about 5% occur in children younger than 16 years of age. Whatever the histologic pattern, parotid gland neoplasms produce swelling in front of and below the ear. In general, when they are first diagnosed, both benign and malignant lesions are usually 4 to 6 cm in diameter and are mobile on palpation except in the case of neglected malignant tumors. Benign tumors may be present for months to several years before coming to clinical attention, while cancers more often come to attention promptly, probably because of their more rapid growth. However, there are no reliable criteria to differentiate



**Figure 14-5** Mucocele. **A**, Fluctuant fluid-filled lesion on the lower lip subsequent to trauma. **B**, Cystlike cavity (right) filled with mucinous material and lined by organizing granulation tissue.

**Table 14-1** Histopathologic Classification and Prevalence of the Most Common Benign and Malignant Salivary Gland Tumors

Benign	Malignant
Pleomorphic adenoma (50%)	Mucoepidermoid carcinoma (15%)
Warthin tumor (5%)	Acinic cell carcinoma (6%)
Oncocytoma (2%)	Adenocarcinoma NOS (6%)
Cystadenoma (2%)	Adenoid cystic carcinoma (4%)
Basal cell adenoma (2%)	Malignant mixed tumor (3%)

NOS, not otherwise specified.

Data from Ellis GL, Auclair PL, Gnepp DR: Surgical Pathology of the Salivary Glands, Vol 25: Major Problems in Pathology, Philadelphia, WB Saunders, 1991.

benign from malignant lesions on clinical grounds, and histopathologic evaluation is essential.

### Pleomorphic Adenoma

Pleomorphic adenomas present as painless, slow-growing, mobile discrete masses. They represent about 60% of tumors in the parotid, are less common in the submandibular glands, and are relatively rare in the minor salivary glands. Pleomorphic adenomas are benign tumors that consist of a mixture of ductal (epithelial) and myoepithelial cells, so they exhibit both epithelial and mesenchymal differentiation. Epithelial elements are dispersed throughout the matrix, which may contain variable mixtures of myxoid, hyaline, chondroid (cartilaginous), and even osseous tissue. In some pleomorphic adenomas, the epithelial elements predominate; in others, they are present only in widely dispersed foci. This histologic diversity has given rise to the alternative, albeit less preferred name *mixed tumor*. The tumors consistently overexpress the transcription factor PLAG1, often because of chromosomal rearrangements involving the PLAG1 gene, but how PLAG1 contributes to tumor development is unknown.

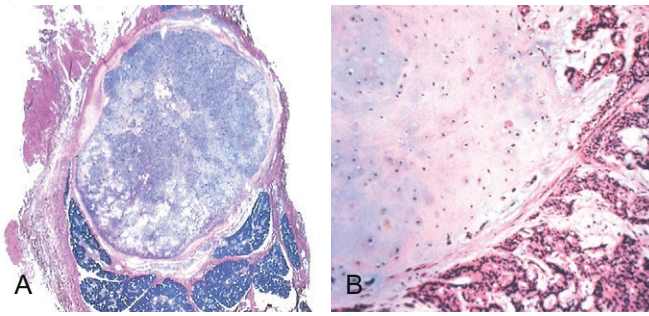
Pleomorphic adenomas recur if incompletely excised: Recurrence rates approach 25% after simple enucleation of the tumor, but are only 4% after wider resection. In both settings, recurrence stems from a failure to recognize minute extensions of tumor into surrounding soft tissues.

Carcinoma arising in a pleomorphic adenoma is referred to variously as a *carcinoma ex pleomorphic adenoma* or *malignant mixed tumor*. The incidence of malignant transformation increases with time from 2% of tumors present for less than 5 years to almost 10% for those present for more than 15 years. The cancer usually takes the form of an adenocarcinoma or undifferentiated carcinoma. Unfortunately, these are among the most aggressive malignant neoplasms of salivary glands, with mortality rates of 30% to 50% at 5 years.

### MORPHOLOGY

Pleomorphic adenomas typically manifest as rounded, well-demarcated masses rarely exceeding 6 cm in the greatest dimension. Although they are encapsulated, in some locations (particularly the palate), the capsule is not fully developed, and expansile growth produces protrusions into the surrounding tissues. The cut surface is gray-white and typically contains myxoid and blue translucent chondroid (cartilage-like) areas. **The most striking histologic feature is their characteristic heterogeneity.** Epithelial





**Figure 14-6** Pleomorphic adenoma. **A**, Low-power view showing a well-demarcated tumor with adjacent normal salivary gland parenchyma. **B**, High-power view showing epithelial cells as well as myoepithelial cells within chondroid matrix material.

elements resembling ductal or myoepithelial cells are arranged in **ducts, acini, irregular tubules, strands, or even sheets**. These typically are dispersed within a **mesenchyme-like background of loose myxoid tissue** containing **islands of chondroid** and, rarely, foci of bone (Fig. 14-6). Sometimes the epithelial cells form well-developed ducts lined by cuboidal to columnar cells with an underlying layer of deeply chromatic, small myoepithelial cells. In other instances there may be strands or sheets of myoepithelial cells. Islands of well-differentiated squamous epithelium also may be present. In most cases, no epithelial dysplasia or mitotic activity is evident. No difference in biologic behavior has been observed between the tumors composed largely of epithelial elements and those composed largely of mesenchymal elements.

### Mucoepidermoid Carcinoma

Mucoepidermoid carcinomas are composed of variable mixtures of squamous cells, mucus-secreting cells, and intermediate cells. These neoplasms represent about 15% of all salivary gland tumors, and while they occur mainly (60% to 70%) in the parotids, they account for a large fraction of salivary gland neoplasms in the other glands, particularly the minor salivary glands. Overall, mucoepidermoid carcinoma is the most common form of primary *malignant* tumor of the salivary glands. It is commonly associated with chromosome rearrangements involving *MAML2*, a gene that encodes a signaling protein in the Notch pathway.

### MORPHOLOGY

Mucoepidermoid carcinomas can grow as large as 8 cm in diameter and, although they are apparently circumscribed, they lack well-defined capsules and often are infiltrative. The cut surface is pale gray to white and frequently demonstrates small, mucinous cysts. On histologic examination, these tumors contain **ords, sheets, or cysts lined by squamous, mucous, or intermediate cells**. The latter is a hybrid cell type with both squamous features and mucus-filled vacuoles, which are most easily detected with mucin stains. Cytologically, tumor cells may be benign-appearing or highly anaplastic and unmistakably malignant. On this basis, mucoepidermoid carcinomas are subclassified as low-, intermediate-, or high-grade.

Clinical course and prognosis depend on histologic grade. Low-grade tumors may invade locally and recur in about 15% of cases but metastasize only rarely and afford a 5-year survival rate over 90%. By contrast, high-grade neoplasms and, to a lesser extent, intermediate-grade tumors are invasive and difficult to excise. As a result, they recur in 25% to 30% of cases, and about 30% metastasize to distant sites. The 5-year survival rate is only 50%.

### SUMMARY

#### Diseases of Salivary Glands

- *Sialadenitis* (inflammation of the salivary glands) can be caused by trauma, infection (such as mumps), or an autoimmune reaction.
- *Pleomorphic adenoma* is a slow-growing neoplasm composed of a heterogeneous mixture of epithelial and mesenchymal cells.
- *Mucoepidermoid carcinoma* is a malignant neoplasm of variable biologic aggressiveness that is composed of a mixture of squamous and mucous cells.

## ODONTOGENIC CYSTS AND TUMORS

In contrast with other skeletal sites, epithelium-lined cysts are common in the jaws. A majority of these cysts are derived from remnants of odontogenic epithelium. In general, these cysts are subclassified as either inflammatory or developmental. Only the most common of these lesions are considered here.

The *dentigerous cyst* originates around the crown of an unerupted tooth and is thought to be the result of a degeneration of the dental follicle (primordial tissue that makes the enamel surface of teeth). On radiographic evaluation, these unilocular lesions most often are associated with impacted third molar (wisdom) teeth. They are lined by a thin, stratified squamous epithelium that typically is associated with a dense chronic inflammatory infiltrate within the underlying connective tissue. Complete removal is curative.

Odontogenic keratocysts can occur at any age but are most frequent in persons between 10 and 40 years of age, have a male predominance, and typically are located within the posterior mandible. Differentiation of the *odontogenic keratocyst* from other odontogenic cysts is important because it is locally aggressive and has a high recurrence rate. On radiographic evaluation, odontogenic keratocysts are seen as well-defined unilocular or multilocular radiolucencies. On histologic examination, the cyst lining consists of a thin layer of parakeratinized or orthokeratinized stratified squamous epithelium with a prominent basal cell layer and a corrugated luminal epithelial surface. Treatment requires aggressive and complete removal; recurrence rates of up to 60% are associated with inadequate resection. Multiple odontogenic keratocysts may occur, particularly in patients with the nevoid basal cell carcinoma syndrome (Gorlin syndrome).

In contrast with the developmental cysts just described, the *periapical cyst* has an inflammatory etiology. These



extremely common lesions occur at the tooth apex as a result of long-standing pulpitis, which may be caused by advanced caries or trauma. Necrosis of the pulpal tissue, which can traverse the length of the root and exit the apex of the tooth into the surrounding alveolar bone, can lead to a periapical abscess. Over time, granulation tissue (with or without an epithelial lining) may develop. These are often designated *periapical granuloma*. Although the lesion does not show true granulomatous inflammation, old terminology, like bad habits, is difficult to shed. Periapical inflammatory lesions persist as a result of bacteria or other offensive agents in the area. Successful treatment, therefore, necessitates the complete removal of the offending material followed by restoration or extraction of the tooth.

*Odontogenic tumors* are a complex group of lesions with diverse histologic appearances and clinical behaviors. Some are true neoplasms, either benign or malignant, while others are thought to be hamartomatous. Odontogenic tumors are derived from odontogenic epithelium, ectomesenchyme, or both. The two most common and clinically significant tumors are ameloblastoma and odontoma.

*Ameloblastomas* arise from odontogenic epithelium and do not demonstrate chondroid or osseous differentiation. These typically cystic lesions are slow-growing and, despite being locally invasive, have an indolent course.

*Odontoma*, the most common type of odontogenic tumor, arises from epithelium but shows extensive deposition of enamel and dentin. Odontomas are cured by local excision.

## SUMMARY

### Odontogenic Cysts and Tumors

- The jaws are a common site of epithelium-lined cysts derived from odontogenic remnants.
- The *odontogenic keratocyst* is locally aggressive, with a high recurrence rate.
- The *periapical cyst* is a reactive, inflammatory lesion associated with caries or dental trauma.
- The most common *odontogenic tumors* are *ameloblastoma* and *odontoma*.

## ESOPHAGUS

The esophagus develops from the cranial portion of the foregut. It is a hollow, highly distensible muscular tube that extends from the epiglottis to the gastroesophageal junction, located just above the diaphragm. Acquired diseases of the esophagus run the gamut from lethal cancers to “heartburn,” with clinical manifestations ranging from chronic and incapacitating disease to mere annoyance.

### OBSTRUCTIVE AND VASCULAR DISEASES

#### Mechanical Obstruction

Atresia, fistulas, and duplications may occur in any part of the gastrointestinal tract. When they involve the esophagus, they are discovered shortly after birth, usually because of regurgitation during feeding, and must be corrected promptly. Absence, or *agenesis*, of the esophagus is extremely rare. *Atresia*, in which a thin, noncanalized cord replaces a segment of esophagus, is more common. *Atresia* occurs most commonly at or near the tracheal bifurcation and usually is associated with a *fistula* connecting the upper or lower esophageal pouches to a bronchus or the trachea. This abnormal connection can result in aspiration, suffocation, pneumonia, or severe fluid and electrolyte imbalances.

Passage of food can be impeded by esophageal *stenosis*. The narrowing generally is caused by fibrous thickening of the submucosa, atrophy of the muscularis propria, and secondary epithelial damage. *Stenosis most often is due to inflammation and scarring, which may be caused by chronic gastroesophageal reflux, irradiation, or caustic injury*. Stenosis-associated dysphagia usually is progressive; difficulty eating solids typically occurs long before problems with liquids.

#### Functional Obstruction

Efficient delivery of food and fluids to the stomach requires a coordinated wave of peristaltic contractions. Esophageal dysmotility interferes with this process and can take several forms, all of which are characterized by disorganized contraction or spasm of the muscularis. Because it increases esophageal wall stress, spasm also can cause small *diverticula* to form.

Increased *lower esophageal sphincter* (LES) tone can result from impaired smooth muscle relaxation with consequent functional esophageal obstruction. *Achalasia is characterized by the triad of incomplete LES relaxation, increased LES tone, and esophageal aperistalsis*. Primary achalasia is caused by failure of distal esophageal inhibitory neurons and is, by definition, idiopathic. Degenerative changes in neural innervation, either intrinsic to the esophagus or within the extraesophageal vagus nerve or the dorsal motor nucleus of the vagus, also may occur. Secondary achalasia may arise in Chagas disease, in which *Trypanosoma cruzi* infection causes destruction of the myenteric plexus, failure of LES relaxation, and esophageal dilatation. Duodenal, colonic, and ureteric myenteric plexuses also can be affected in Chagas disease. Achalasia-like disease may be caused by diabetic autonomic neuropathy; infiltrative disorders such as malignancy, amyloidosis, or sarcoidosis; and lesions of dorsal motor nuclei, which may be produced by polio or surgical ablation.

#### Ectopia

Ectopic tissues (*developmental rests*) are common in the gastrointestinal tract. The most frequent site of *ectopic gastric mucosa* is the upper third of the esophagus, where it is referred to as an *inlet patch*. Although the presence of such tissue generally is asymptomatic, acid released by gastric

mucosa within the esophagus can result in dysphagia, esophagitis, Barrett esophagus, or, rarely, adenocarcinoma. *Gastric heterotopia*, small patches of ectopic gastric mucosa in the small bowel or colon, may manifest with occult blood loss secondary to peptic ulceration of adjacent mucosa.

## Esophageal Varices

Instead of returning directly to the heart, venous blood from the gastrointestinal tract is delivered to the liver via the portal vein before reaching the inferior vena cava. This circulatory pattern is responsible for the *first-pass effect*, in which drugs and other materials absorbed in the intestines are processed by the liver before entering the systemic circulation. Diseases that impede this flow cause portal hypertension, which can lead to the development of esophageal varices, an important cause of esophageal bleeding.

### PATHOGENESIS

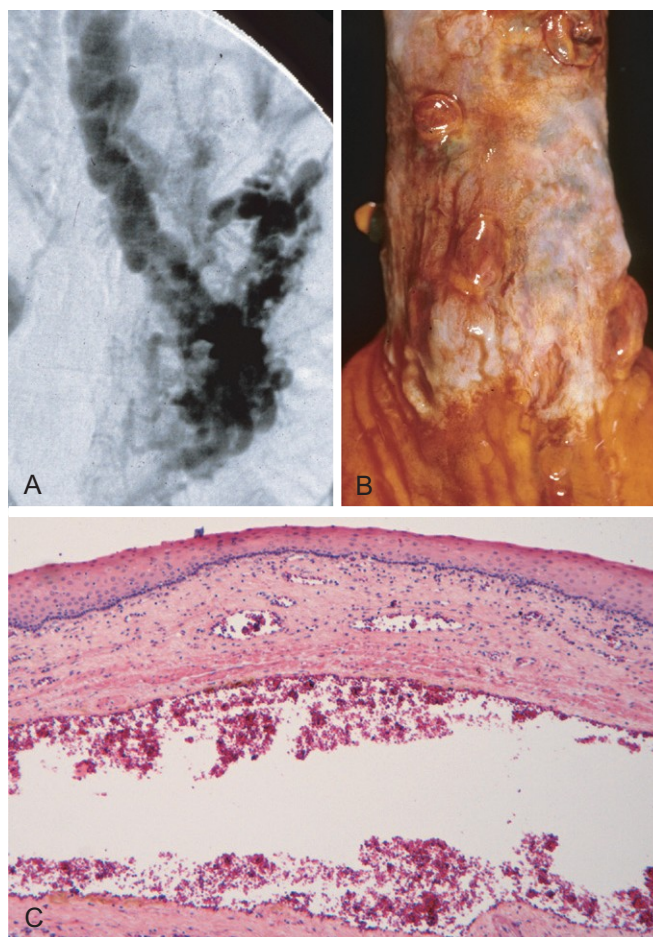
One of the few sites where the splanchnic and systemic venous circulations can communicate is the esophagus. Thus, portal hypertension induces development of collateral channels that allow portal blood to shunt into the caval system. However, these collateral veins enlarge the subepithelial and submucosal venous plexi within the distal esophagus. These vessels, termed **varices**, develop in 90% of cirrhotic patients, most commonly in association with alcoholic liver disease. Worldwide, hepatic schistosomiasis is the second most common cause of varices. A more detailed consideration of portal hypertension is given in Chapter 15.

### MORPHOLOGY

Varices can be detected by angiography (Fig. 14-7, A) and appear as tortuous dilated veins lying primarily within the submucosa of the distal esophagus and proximal stomach. Varices may not be obvious on gross inspection of surgical or postmortem specimens, because they collapse in the absence of blood flow (Fig. 14-7, B). The overlying mucosa can be intact (Fig. 14-7, C) but is ulcerated and necrotic if rupture has occurred.

### Clinical Features

Varices often are asymptomatic, but their rupture can lead to massive hematemesis and death. Variceal rupture therefore constitutes a medical emergency. Despite intervention, as many as half of the patients die from the first bleeding episode, either as a direct consequence of hemorrhage or due to hepatic coma triggered by the protein load that results from intraluminal bleeding and hypovolemic shock. Among those who survive, additional episodes of hemorrhage, each potentially fatal, occur in more than 50% of cases. As a result, greater than half of the deaths associated with advanced cirrhosis result from variceal rupture.



**Figure 14-7** Esophageal varices. **A**, Angiogram showing several tortuous esophageal varices. Although the angiogram is striking, endoscopy is more commonly used to identify varices. **B**, Collapsed varices are present in this postmortem specimen corresponding to the angiogram in **A**. The polypoid areas are sites of variceal hemorrhage that were ligated with bands. **C**, Dilated varices beneath intact squamous mucosa.

## ESOPHAGITIS

### Lacerations

The most common esophageal lacerations are *Mallory-Weiss tears*, which are often associated with severe retching or vomiting, as may occur with acute alcohol intoxication. Normally, a reflex relaxation of the gastroesophageal musculature precedes the antiperistaltic contractile wave associated with vomiting. This relaxation is thought to fail during prolonged vomiting, with the result that refluxing gastric contents overwhelm the gastric inlet and cause the esophageal wall to stretch and tear. Patients often present with hematemesis.

The roughly linear lacerations of *Mallory-Weiss syndrome* are longitudinally oriented, range in length from millimeters to several centimeters, and usually cross the gastroesophageal junction. These tears are superficial and do not generally require surgical intervention; healing tends to be rapid and complete. By contrast, *Boerhaave syndrome*, characterized by transmural esophageal tears and mediastinitis, occurs rarely and is a catastrophic event. The factors



giving rise to this syndrome are similar to those for Mallory-Weiss tears, but more severe.

## Chemical and Infectious Esophagitis

The stratified squamous mucosa of the esophagus may be damaged by a variety of irritants including alcohol, corrosive acids or alkalis, excessively hot fluids, and heavy smoking. Medicinal pills may lodge and dissolve in the esophagus, rather than passing into the stomach intact, resulting in a condition termed *pill-induced esophagitis*. Esophagitis due to chemical injury generally causes only self-limited pain, particularly *odynophagia* (pain with swallowing). Hemorrhage, stricture, or perforation may occur in severe cases. Iatrogenic esophageal injury may be caused by cytotoxic *chemotherapy*, *radiation therapy*, or *graft-versus-host disease*. The morphologic changes are nonspecific with ulceration and accumulation of neutrophils. Irradiation causes blood vessel thickening adding some element of ischemic injury.

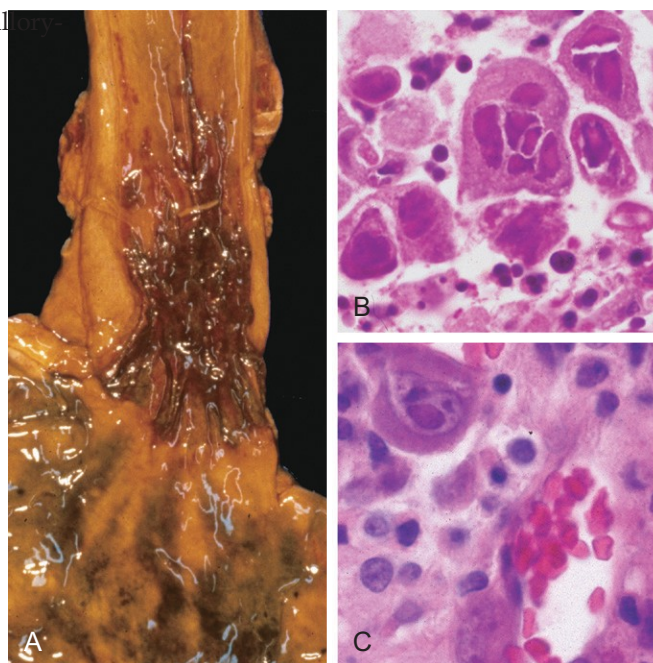
Infectious esophagitis may occur in otherwise healthy persons but is most frequent in those who are debilitated or immunosuppressed. In these patients, esophageal infection by *herpes simplex viruses*, *cytomegalovirus* (CMV), or *fungal organisms* is common. Among fungi, *Candida* is the most common pathogen, although *mucormycosis* and *aspergillosis* may also occur. The esophagus may also be involved in desquamative skin diseases such as *bullous pemphigoid* and *epidermolysis bullosa* and, rarely, *Crohn disease*.

Infection by fungi or bacteria can be primary or complicate a preexisting ulcer. Nonpathogenic oral bacteria frequently are found in ulcer beds, while pathogenic organisms, which account for about 10% of infectious esophagitis cases, may invade the lamina propria and cause necrosis of overlying mucosa. Candidiasis, in its most advanced form, is characterized by adherent, gray-white pseudomembranes composed of densely matted fungal hyphae and inflammatory cells covering the esophageal mucosa.

The endoscopic appearance often provides a clue to the identity of the infectious agent in viral esophagitis. Herpesviruses typically cause punched-out ulcers (Fig. 14-8, A), and histopathologic analysis demonstrates nuclear viral inclusions within a rim of degenerating epithelial cells at the ulcer edge (Fig. 14-8, B). By contrast, CMV causes shallower ulcerations and characteristic nuclear and cytoplasmic inclusions within capillary endothelium and stromal cells (Fig. 14-8, C). Immunohistochemical staining for viral antigens can be used as an ancillary diagnostic tool.

## Reflux Esophagitis

The stratified squamous epithelium of the esophagus is resistant to abrasion from foods but is sensitive to acid. The submucosal glands of the proximal and distal esophagus contribute to mucosal protection by secreting mucin and bicarbonate. More important, constant LES tone prevents reflux of acidic gastric contents, which are under positive pressure. Reflux of gastric contents into the lower esophagus is the most frequent cause of esophagitis and the most common outpatient gastrointestinal diagnosis in the United



**Figure 14-8** Viral esophagitis. **A**, Postmortem specimen with multiple herpetic ulcers in the distal esophagus. **B**, Multinucleate squamous cells containing herpesvirus nuclear inclusions. **C**, Cytomegalovirus-infected endothelial cells with nuclear and cytoplasmic inclusions.

States. The associated clinical condition is termed *gastroesophageal reflux disease* (GERD).

## PATHOGENESIS

Reflux of gastric juices is central to the development of mucosal injury in GERD. In severe cases, duodenal bile reflux may exacerbate the damage. Conditions that decrease LES tone or increase abdominal pressure contribute to GERD and include alcohol and tobacco use, obesity, central nervous system depressants, pregnancy, hiatal hernia (discussed later), delayed gastric emptying, and increased gastric volume. In many cases, no definitive cause is identified.

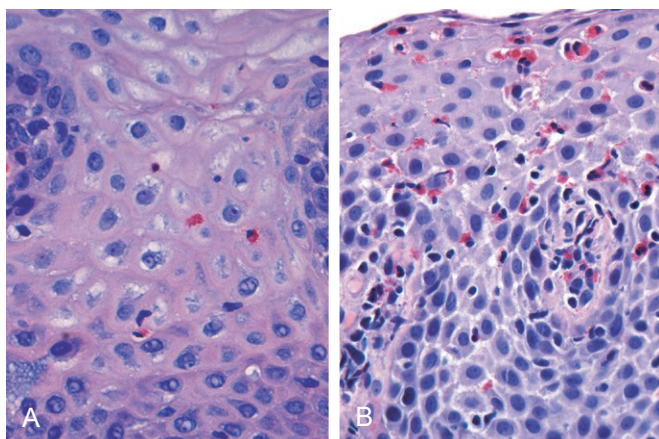
## MORPHOLOGY

Simple **hyperemia**, evident to the endoscopist as redness, may be the only alteration. In mild GERD the mucosal histology is often unremarkable. With more significant disease, **eosinophils** are recruited into the squamous mucosa, followed by neutrophils, which usually are associated with more severe injury (Fig. 14-9, A). **Basal zone hyperplasia** exceeding 20% of the total epithelial thickness and elongation of lamina propria papillae, such that they extend into the upper third of the epithelium, also may be present.

## Clinical Features

GERD is most common in adults older than 40 years of age but also occurs in infants and children. The most frequently reported symptoms are heartburn, dysphagia, and, less often, noticeable regurgitation of sour-tasting gastric contents. Rarely, chronic GERD is punctuated by attacks of





**Figure 14-9** Esophagitis. **A**, Reflux esophagitis with scattered intraepithelial eosinophils. **B**, Eosinophilic esophagitis with numerous intraepithelial eosinophils.

severe chest pain that may be mistaken for heart disease. Treatment with proton pump inhibitors reduces gastric acidity and typically provides symptomatic relief. While the severity of symptoms is not closely related to the degree of histologic damage, the latter tends to increase with disease duration. Complications of reflux esophagitis include esophageal ulceration, hematemesis, melena, stricture development, and Barrett esophagus.

*Hiatal hernia* is characterized by separation of the diaphragmatic crura and protrusion of the stomach into the thorax through the resulting gap. Congenital hiatal hernias are recognized in infants and children, but many are acquired in later life. Hiatal hernia is asymptomatic in more than 90% of adult cases. Thus, symptoms, which are similar to GERD, are often associated with other causes of LES incompetence.

### Eosinophilic Esophagitis

The incidence of eosinophilic esophagitis is increasing markedly. Symptoms include food impaction and dysphagia in adults and feeding intolerance or GERD-like symptoms in children. The cardinal histologic feature is epithelial infiltration by large numbers of eosinophils, particularly superficially (Fig. 14-9, B) and at sites far from the gastroesophageal junction. Their abundance can help to differentiate eosinophilic esophagitis from GERD, Crohn disease, and other causes of esophagitis. Certain clinical characteristics, particularly failure of high-dose proton pump inhibitor treatment and the absence of acid reflux, are also typical. A majority of persons with eosinophilic esophagitis are atopic, and many have atopic dermatitis, allergic rhinitis, asthma, or modest peripheral eosinophilia. Treatments include dietary restrictions to prevent exposure to food allergens, such as cow milk and soy products, and topical or systemic corticosteroids.

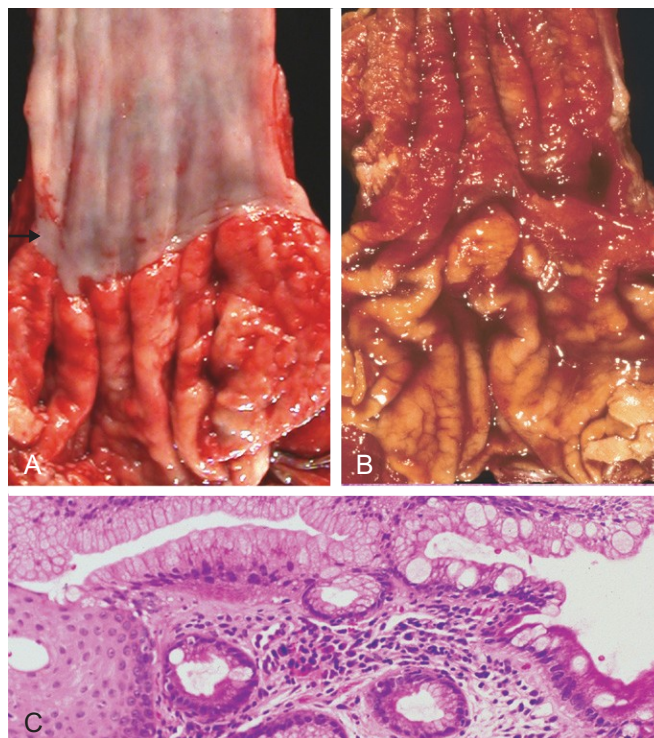
### Barrett Esophagus

*Barrett esophagus* is a complication of chronic GERD that is characterized by *intestinal metaplasia within the esophageal*

*squamous mucosa*. The incidence of Barrett esophagus is rising; it is estimated to occur in as many as 10% of persons with symptomatic GERD. White males are affected most often and typically present between 40 and 60 years of age. The greatest concern in Barrett esophagus is that *it confers an increased risk of esophageal adenocarcinoma*. Molecular studies suggest that Barrett epithelium may be more similar to adenocarcinoma than to normal esophageal epithelium, consistent with the view that Barrett esophagus is a premalignant condition. In keeping with this, epithelial *dysplasia*, considered to be a preinvasive lesion, develops in 0.2% to 1.0% of persons with Barrett esophagus each year; its incidence increases with duration of symptoms and increasing patient age. Although the vast majority of esophageal adenocarcinomas are associated with Barrett esophagus, it should be noted that most persons with Barrett esophagus do not develop esophageal cancer.

### MORPHOLOGY

Barrett esophagus is recognized endoscopically as tongues or patches of red, velvety mucosa extending upward from the gastroesophageal junction. This metaplastic mucosa alternates with residual smooth, pale squamous (esophageal) mucosa proximally and interfaces with light-brown columnar (gastric) mucosa distally (Fig. 14-10, A and B). High-resolution endoscopes have increased the sensitivity of Barrett esophagus detection.



**Figure 14-10** Barrett esophagus. **A**, Normal gastroesophageal junction. **B**, Barrett esophagus. Note the small islands of paler squamous mucosa within the Barrett mucosa. **C**, Histologic appearance of the gastroesophageal junction in Barrett esophagus. Note the transition between esophageal squamous mucosa (left) and metaplastic mucosa containing goblet cells (right).

Most authors require both endoscopic evidence of abnormal mucosa above the gastroesophageal junction and histologically documented gastric or intestinal metaplasia for diagnosis of Barrett esophagus. **Goblet cells**, which have distinct mucous vacuoles that stain pale blue by H&E and impart the shape of a wine goblet to the remaining cytoplasm, define intestinal metaplasia and are a feature of Barrett esophagus (Fig. 14–10, C). Dysplasia is classified as low-grade or high-grade on the basis of morphologic criteria. Intramucosal carcinoma is characterized by invasion of neoplastic epithelial cells into the lamina propria.

### Clinical Features

Diagnosis of Barrett esophagus requires endoscopy and biopsy, usually prompted by GERD symptoms. The best course of management is a matter of debate. While many investigators agree that periodic endoscopy with biopsy, for detection of dysplasia, is reasonable, uncertainties about the frequency with which dysplasia occurs and whether it can regress spontaneously complicate clinical decision making. By contrast, intramucosal carcinoma requires therapeutic intervention. Treatment options include surgical resection (*esophagectomy*), and newer modalities such as photodynamic therapy, laser ablation, and endoscopic mucosectomy. Multifocal high-grade dysplasia, which carries a significant risk of progression to intramucosal or invasive carcinoma, may be treated in a fashion similar to intramucosal carcinoma.

## ESOPHAGEAL TUMORS

Two morphologic variants account for a majority of esophageal cancers: adenocarcinoma and squamous cell carcinoma. Worldwide, squamous cell carcinoma is more common, but in the United States and other Western countries adenocarcinoma is on the rise. Other rare tumors occur but are not discussed here.

### Adenocarcinoma

Esophageal adenocarcinoma typically arises in a background of Barrett esophagus and long-standing GERD. Risk of adenocarcinoma is greater in patients with documented dysplasia and is further increased by tobacco use, obesity, and previous radiation therapy. Conversely, reduced adenocarcinoma risk is associated with diets rich in fresh fruits and vegetables.

Esophageal adenocarcinoma occurs most frequently in whites and shows a strong gender bias, being seven times more common in men than in women. However, the incidence varies by a factor of 60 worldwide, with rates being highest in developed Western countries, including the United States, the United Kingdom, Canada, Australia, and the Netherlands, and lowest in Korea, Thailand, Japan, and Ecuador. In countries where esophageal adenocarcinoma is more common, the incidence has increased markedly since 1970, more rapidly than for almost any other cancer. As a result, esophageal adenocarcinoma, which represented less than 5% of esophageal cancers before 1970, now

accounts for half of all esophageal cancers in the United States.

### PATHOGENESIS

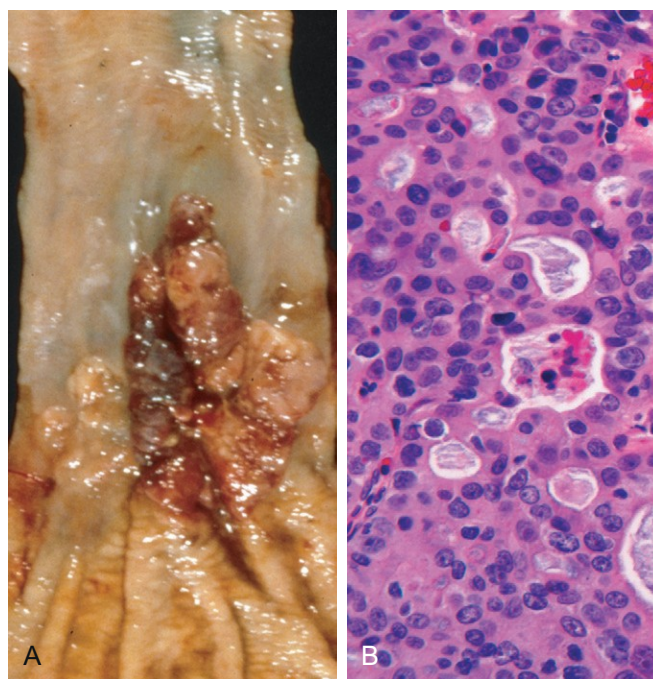
Molecular studies suggest that the progression of Barrett esophagus to adenocarcinoma occurs over an extended period through the stepwise acquisition of genetic and epigenetic changes. This model is supported by the observation that epithelial clones identified in nondysplastic Barrett metaplasia persist and accumulate mutations during progression to dysplasia and invasive carcinoma. Chromosomal abnormalities and *TP53* mutation are often present at early stages of esophageal adenocarcinoma. Additional genetic changes and inflammation also are thought to contribute to neoplastic progression.

### MORPHOLOGY

Esophageal adenocarcinoma usually occurs in the distal third of the esophagus and may invade the adjacent gastric cardia (Fig. 14–11, A). While early lesions may appear as flat or raised patches in otherwise intact mucosa, tumors may form large exophytic masses, infiltrate diffusely, or ulcerate and invade deeply. On microscopic examination, Barrett esophagus frequently is present adjacent to the tumor. Tumors typically produce mucin and form glands (Fig. 14–11, B).

### Clinical Features

Although esophageal adenocarcinomas are occasionally discovered during evaluation of GERD or surveillance of Barrett esophagus, they more commonly manifest with



**Figure 14–11** Esophageal adenocarcinoma. **A**, Adenocarcinoma usually occurs distally and, as in this case, often involves the gastric cardia. **B**, Esophageal adenocarcinoma growing as back-to-back glands.



pain or difficulty in swallowing, progressive weight loss, chest pain, or vomiting. By the time symptoms and signs appear, the tumor usually has spread to submucosal lymphatic vessels. As a result of the advanced stage at diagnosis, the overall 5-year survival rate is less than 25%. By contrast, 5-year survival approximates 80% in the few patients with adenocarcinoma limited to the mucosa or submucosa.

## Squamous Cell Carcinoma

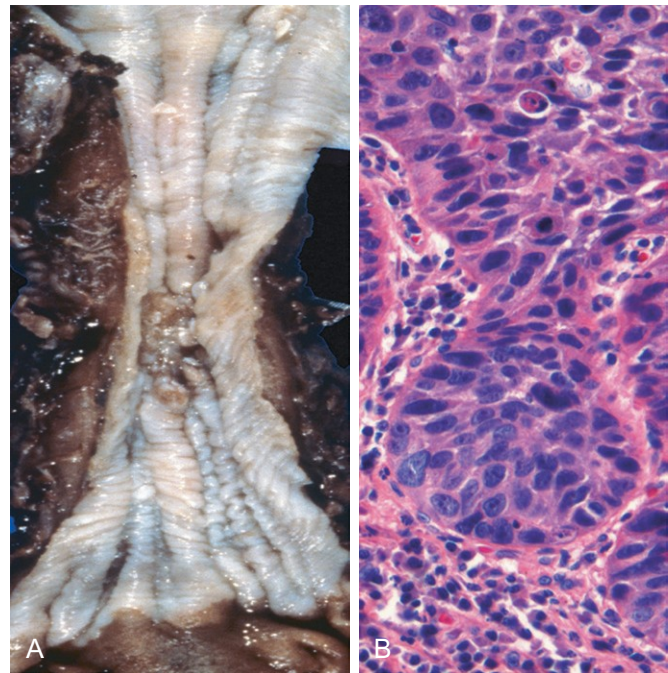
In the United States, esophageal squamous cell carcinoma typically occurs in adults older than 45 years of age and affects males four times more frequently than females. Risk factors include alcohol and tobacco use, poverty, caustic esophageal injury, achalasia, Plummer-Vinson syndrome, frequent consumption of very hot beverages, and previous radiation therapy to the mediastinum. It is nearly 6 times more common in African Americans than in whites—a striking risk disparity that cannot be accounted for by differences in rates of alcohol and tobacco use. The incidence of esophageal squamous cell carcinoma can vary by more than 100-fold between and within countries, being more common in rural and underdeveloped areas. The countries with highest incidences are Iran, central China, Hong Kong, Argentina, Brazil, and South Africa.

### PATHOGENESIS

A majority of esophageal squamous cell carcinomas in Europe and the United States are at least partially attributable to the use of alcohol and tobacco, the effects of which synergize to increase risk. However, esophageal squamous cell carcinoma also is common in some regions where alcohol and tobacco use is uncommon. Thus, nutritional deficiencies, as well as polycyclic hydrocarbons, nitrosamines, and other mutagenic compounds, such as those found in fungus-contaminated foods, have been considered as possible risk factors. HPV infection also has been implicated in esophageal squamous cell carcinoma in high-risk but not in low-risk regions. The molecular pathogenesis of esophageal squamous cell carcinoma remains incompletely defined.

### MORPHOLOGY

In contrast to the distal location of most adenocarcinomas, half of squamous cell carcinomas occur in the middle third of the esophagus (Fig. 14–12, A). Squamous cell carcinoma begins as an *in situ* lesion in the form of **squamous dysplasia**. Early lesions appear as small, gray-white plaquelike thickenings. Over months to years they grow into tumor masses that may be polypoid and protrude into and obstruct the lumen. Other tumors are either ulcerated or diffusely infiltrative lesions that spread within the esophageal wall, where they cause thickening, rigidity, and luminal narrowing. These cancers may invade surrounding structures including the respiratory tree, causing pneumonia; the aorta, causing catastrophic exsanguination; or the mediastinum and pericardium.



**Figure 14–12** Esophageal squamous cell carcinoma. **A**, Squamous cell carcinoma most frequently is found in the midesophagus, where it commonly causes strictures. **B**, Squamous cell carcinoma composed of nests of malignant cells that partially recapitulate the stratified organization of squamous epithelium.

Most squamous cell carcinomas are moderately to well differentiated (Fig. 14–12, B). Less common histologic variants include verrucous squamous cell carcinoma, spindle cell carcinoma, and basaloid squamous cell carcinoma. Regardless of histologic type, symptomatic tumors are generally very large at diagnosis and have already invaded the esophageal wall. The rich submucosal lymphatic network promotes circumferential and longitudinal spread, and intramural tumor nodules may be present several centimeters away from the principal mass. The sites of lymph node metastases vary with tumor location: Cancers in the upper third of the esophagus favor cervical lymph nodes; those in the middle third favor mediastinal, paratracheal, and tracheobronchial nodes; and those in the lower third spread to gastric and celiac nodes.

### Clinical Features

Clinical manifestations of squamous cell carcinoma of the esophagus begin insidiously and include dysphagia, odynophagia (pain on swallowing), and obstruction. As with other forms of esophageal obstruction, patients may unwittingly adjust to the progressively increasing obstruction by altering their diet from solid to liquid foods. Extreme weight loss and debilitation result from both impaired nutrition and effects of the tumor itself. Hemorrhage and sepsis may accompany tumor ulceration. Occasionally, the first symptoms are caused by aspiration of food through a tracheoesophageal fistula.

Increased use of endoscopic screening has led to earlier detection of esophageal squamous cell carcinoma. The



timing is critical, because 5-year survival rates are 75% for patients with superficial esophageal carcinoma but much lower for patients with more advanced tumors. Lymph node metastases, which are common, are associated with poor prognosis. The overall 5-year survival rate remains a dismal 9%.

## SUMMARY

### Diseases of the Esophagus

- *Esophageal obstruction* may occur as a result of mechanical or functional anomalies. Mechanical causes include developmental defects, fibrotic strictures, and tumors.

- *Achalasia*, characterized by incomplete LES relaxation, increased LES tone, and esophageal aperistalsis, is a common form of *functional esophageal obstruction*.
- *Esophagitis* can result from chemical or infectious mucosal injury. Infections are most frequent in immunocompromised persons.
- The most common cause of esophagitis is *gastroesophageal reflux disease (GERD)*, which must be differentiated from *eosinophilic esophagitis*.
- *Barrett esophagus*, which may develop in patients with chronic GERD, is associated with increased risk of esophageal adenocarcinoma.
- *Esophageal squamous cell carcinoma* is associated with alcohol and tobacco use, poverty, caustic esophageal injury, achalasia, tylosis, and Plummer-Vinson syndrome.

## STOMACH

Disorders of the stomach are a frequent cause of clinical disease, with inflammatory and neoplastic lesions being particularly common. In the United States, symptoms related to gastric acid account for nearly one third of all health care spending on gastrointestinal disease. In addition, despite a decreasing incidence in certain locales, including the United States, gastric cancer remains a leading cause of death worldwide.

The stomach is divided into four major anatomic regions: the cardia, fundus, body, and antrum. The cardia is lined mainly by mucin-secreting *foveolar cells* that form shallow glands. The antral glands are similar but also contain endocrine cells, such as *G cells*, that release gastrin to stimulate luminal acid secretion by *parietal cells* within the gastric fundus and body. The well-developed glands of the body and fundus also contain *chief cells* that produce and secrete digestive enzymes such as pepsin.

## INFLAMMATORY DISEASE OF THE STOMACH

### Acute Gastritis

Acute gastritis is a transient mucosal inflammatory process that may be asymptomatic or cause variable degrees of epigastric pain, nausea, and vomiting. In more severe cases there may be mucosal erosion, ulceration, hemorrhage, hematemesis, melena, or, rarely, massive blood loss.

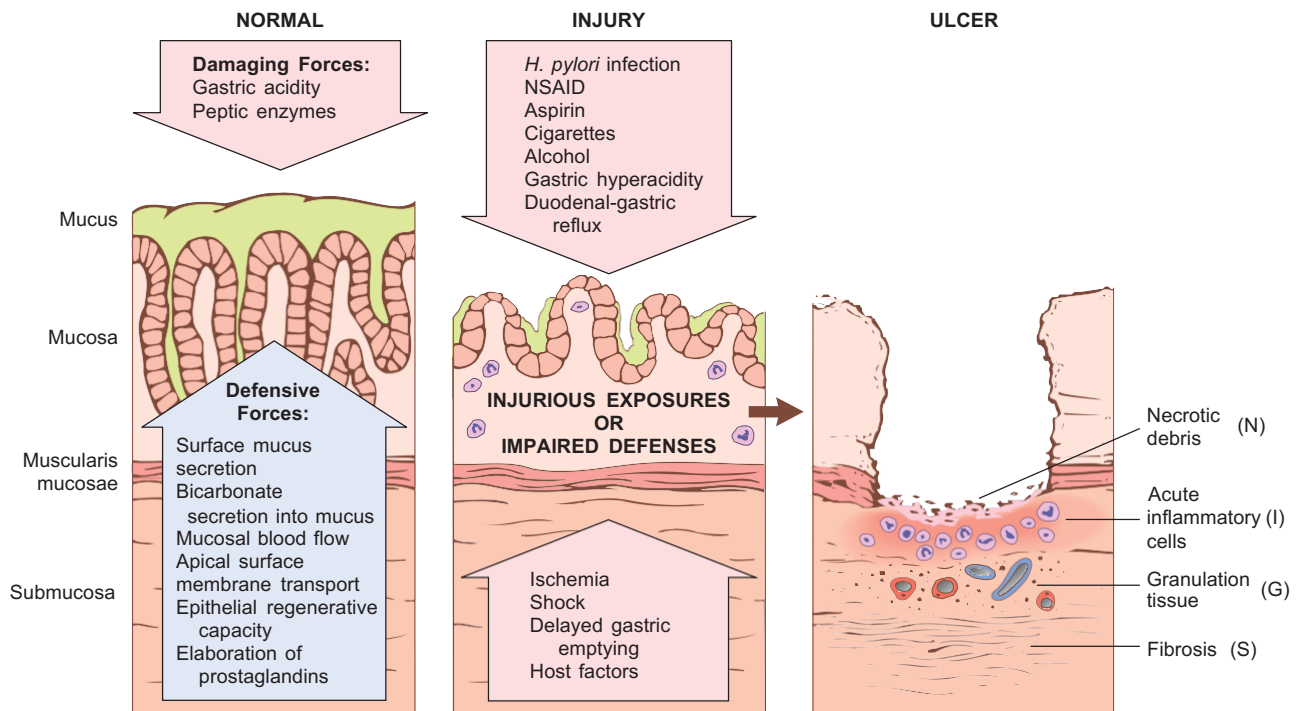
### PATHOGENESIS

The gastric lumen is strongly acidic, with a pH close to one—more than a million times more acidic than the blood. This harsh environment contributes to digestion but also has the potential to damage the mucosa. Multiple mechanisms have evolved to protect the gastric mucosa (Fig. 14–13). Mucin secreted by surface **foveolar cells** forms a thin layer of mucus that prevents large food particles from directly touching the epithelium. The mucus layer also promotes formation

of an “unstirred” layer of fluid over the epithelium that protects the mucosa and has a neutral pH as a result of bicarbonate ion secretion by surface epithelial cells. Finally, the rich vascular supply to the gastric mucosa delivers oxygen, bicarbonate, and nutrients while washing away acid that has back-diffused into the lamina propria. Acute or chronic gastritis can occur after disruption of any of these protective mechanisms. For example, reduced mucin synthesis in elderly persons is suggested to be one factor that explains their increased susceptibility to gastritis. Nonsteroidal anti-inflammatory drugs (NSAIDs) may interfere with cytoprotection normally provided by prostaglandins or reduce bicarbonate secretion, both of which increase the susceptibility of the gastric mucosa to injury. Ingestion of harsh chemicals, particularly acids or bases, either accidentally or as a suicide attempt, also results in severe gastric injury, predominantly as a consequence of direct damage to mucosal epithelial and stromal cells. Direct cellular injury also is implicated in gastritis due to excessive alcohol consumption, NSAIDs, radiation therapy, and chemotherapy.

### MORPHOLOGY

On histologic examination, mild acute gastritis may be difficult to recognize, since the lamina propria shows only moderate edema and slight vascular congestion. The **surface epithelium is intact**, although scattered neutrophils may be present. Lamina propria lymphocytes and plasma cells are not prominent. The presence of neutrophils above the basement membrane—specifically, in direct contact with epithelial cells—is abnormal in all parts of the gastrointestinal tract and signifies **active inflammation**. With more severe mucosal damage, *erosion*, or loss of the superficial epithelium, may occur, leading to formation of mucosal neutrophilic infiltrates and purulent exudates. Hemorrhage also may occur, manifesting as dark puncta in an otherwise hyperemic mucosa. Concurrent presence of erosion and hemorrhage is termed **acute erosive hemorrhagic gastritis**.



**Figure 14-13** Mechanisms of gastric injury and protection. This diagram illustrates the progression from more mild forms of injury to ulceration that may occur with acute or chronic gastritis. Ulcers include layers of necrotic debris (N), inflammation (I), and granulation tissue (G); a fibrotic scar (S), which develops over time, is present only in chronic lesions.

## Acute Peptic Ulceration

Focal, acute peptic injury is a well-known complication of therapy with NSAIDs as well as severe physiologic stress. Such lesions include

- *Stress ulcers*, most commonly affecting critically ill patients with shock, sepsis, or severe trauma
- *Curling ulcers*, occurring in the proximal duodenum and associated with severe burns or trauma
- *Cushing ulcers*, arising in the stomach, duodenum, or esophagus of persons with intracranial disease, have a high incidence of perforation

## PATHOGENESIS

The pathogenesis of acute ulceration is complex and incompletely understood. NSAID-induced ulcers are caused by direct chemical irritation as well as cyclooxygenase inhibition, which prevents prostaglandin synthesis. This eliminates the protective effects of prostaglandins, which include enhanced bicarbonate secretion and increased vascular perfusion. Lesions associated with intracranial injury are thought to be caused by direct stimulation of vagal nuclei, which causes gastric acid hypersecretion. Systemic acidosis, a frequent finding in critically ill patients, also may contribute to mucosal injury by lowering the intracellular pH of mucosal cells. Hypoxia and reduced blood flow caused by stress-induced splanchnic vasoconstriction also contribute to acute ulcer pathogenesis.

## MORPHOLOGY

Lesions described as acute gastric ulcers range in depth from shallow erosions caused by superficial epithelial damage to deeper lesions that penetrate the mucosa. Acute ulcers are rounded and typically are less than 1 cm in diameter. The ulcer base frequently is stained brown to black by acid-digested extravasated red cells, in some cases associated with transmural inflammation and local serositis. While these lesions may occur singly, more often multiple ulcers are present within the stomach and duodenum. Acute stress ulcers are sharply demarcated, with essentially normal adjacent mucosa, although there may be suffusion of blood into the mucosa and submucosa and some inflammatory reaction. The scarring and thickening of blood vessels that characterize chronic peptic ulcers are absent. Healing with complete reepithelialization occurs days or weeks after the injurious factors are removed.

## Clinical Features

Symptoms of gastric ulcers include nausea, vomiting, and coffee-ground hematemesis. Bleeding from superficial gastric erosions or ulcers that may require transfusion develops in 1% to 4% of these patients. Other complications, including perforation, can also occur. Proton pump inhibitors, or the less frequently used histamine H<sub>2</sub> receptor antagonists, may blunt the impact of stress ulceration, but the most important determinant of outcome is the severity of the underlying condition.

## Chronic Gastritis

The symptoms and signs associated with chronic gastritis typically are less severe but more persistent than those of acute gastritis. Nausea and upper abdominal discomfort may occur, sometimes with vomiting, but hematemesis is uncommon. *The most common cause of chronic gastritis is infection with the bacillus Helicobacter pylori.* Autoimmune gastritis, the most common cause of *atrophic gastritis*, represents less than 10% of cases of chronic gastritis and is the most common form of chronic gastritis in patients without *H. pylori* infection. Less common causes include radiation injury and chronic bile reflux.

### Helicobacter pylori Gastritis

The discovery of the association of *H. pylori* with peptic ulcer disease revolutionized the understanding of chronic gastritis. These spiral-shaped or curved bacilli are present in gastric biopsy specimens from almost all patients with duodenal ulcers and a majority of those with gastric ulcers or chronic gastritis. Acute *H. pylori* infection does not produce sufficient symptoms to require medical attention in most cases; rather the chronic gastritis ultimately causes the afflicted person to seek treatment. *H. pylori* organisms are present in 90% of patients with chronic gastritis affecting the antrum. In addition, the increased acid secretion that occurs in *H. pylori* gastritis may result in peptic ulcer disease of the stomach or duodenum; *H. pylori* infection also confers increased risk of gastric cancer.

### Epidemiology

In the United States, *H. pylori* infection is associated with poverty, household crowding, limited education, African American or Mexican American ethnicity, residence in areas with poor sanitation, and birth outside of the United States. Colonization rates exceed 70% in some groups and range from less than 10% to more than 80% worldwide. In high-prevalence areas, infection often is acquired in childhood and then persists for decades. Thus, the incidence of *H. pylori* infection correlates most closely with sanitation and hygiene during an individual's childhood.

## PATHOGENESIS

*H. pylori* infection most often manifests as a **predominantly antral gastritis with high acid production, despite hypogastrinemia.** The risk of duodenal ulcer is increased in these patients, and in most cases, gastritis is limited to the antrum.

*H. pylori* organisms have adapted to the ecologic niche provided by gastric mucus. Although *H. pylori* may invade the gastric mucosa, the contribution of invasion to disease pathogenesis is not known. Four features are linked to *H. pylori* virulence:

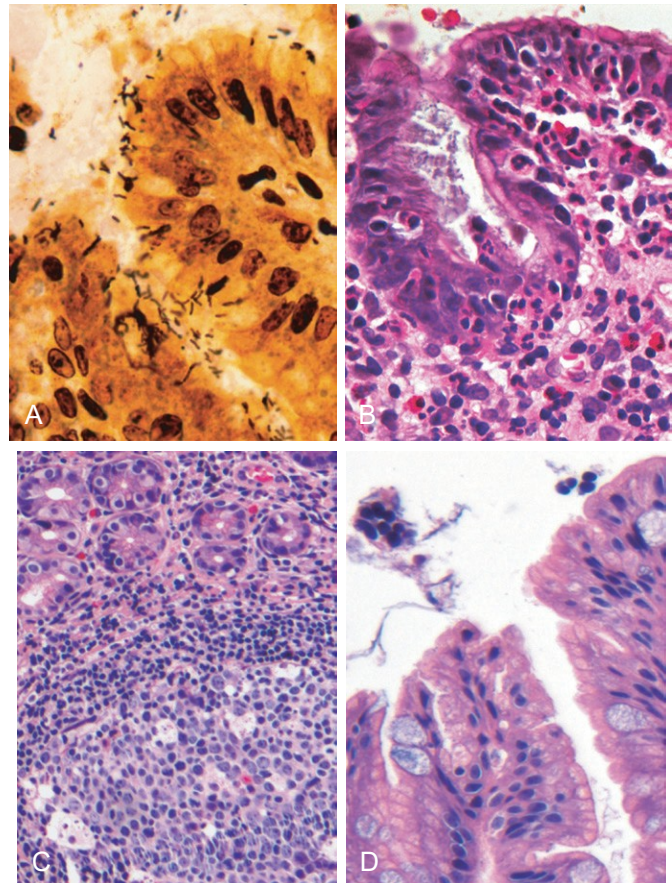
- **Flagella**, which allow the bacteria to be motile in viscous mucus
- **Urease**, which generates ammonia from endogenous urea, thereby elevating local gastric pH around the organisms and protecting the bacteria from the acidic pH of the stomach

- **Adhesins**, which enhance bacterial adherence to surface foveolar cells
- **Toxins**, such as that encoded by cytotoxin-associated gene A (*CagA*), that may be involved in ulcer or cancer development by poorly defined mechanisms

These factors allow *H. pylori* to create an imbalance between gastroduodenal mucosal defenses and damaging forces that overcome those defenses. Over time, chronic antral *H. pylori* gastritis may progress to **pangastritis**, resulting in **multifocal atrophic gastritis**, reduced acid secretion, intestinal metaplasia, and increased risk of gastric adenocarcinoma in a subset of patients. The underlying mechanisms contributing to this progression are not clear, but interactions between the host immune system and the bacterium seem to be critical.

## MORPHOLOGY

Gastric biopsy specimens generally demonstrate *H. pylori* in infected persons (Fig. 14–14, A). The organism is concentrated within the superficial mucus overlying epithelial cells in



**Figure 14–14** Chronic gastritis. **A**, Spiral-shaped *Helicobacter pylori* bacilli are highlighted in this Warthin-Starry silver stain. Organisms are abundant within surface mucus. **B**, Intraepithelial and lamina propria neutrophils are prominent. **C**, Lymphoid aggregates with germinal centers and abundant subepithelial plasma cells within the superficial lamina propria are characteristic of *H. pylori* gastritis. **D**, Intestinal metaplasia, recognizable as the presence of goblet cells admixed with gastric foveolar epithelium, can develop and is a risk factor for development of gastric adenocarcinoma.



the surface and neck regions. The inflammatory reaction includes a variable number of neutrophils within the lamina propria, including some that cross the basement membrane to assume an intraepithelial location (Fig. 14-14, B) and accumulate in the lumen of gastric pits to create pit abscesses. The superficial lamina propria includes large numbers of plasma cells, often in clusters or sheets, as well as increased numbers of lymphocytes and macrophages. When intense, inflammatory infiltrates may create thickened rugal folds, mimicking infiltrative lesions. Lymphoid aggregates, some with germinal centers, frequently are present (Fig. 14-14, C) and represent an induced form of **mucosa-associated lymphoid tissue (MALT)** that has the potential to transform into lymphoma. **Intestinal metaplasia**, characterized by the presence of goblet cells and columnar absorptive cells (Fig. 14-14, D), also may be present and is associated with increased risk of gastric adenocarcinoma. *H. pylori* shows tropism for gastric foveolar epithelium and generally is not found in areas of intestinal metaplasia, acid-producing mucosa of the gastric body, or duodenal epithelium. Thus, an antral biopsy is preferred for evaluation of *H. pylori* gastritis.

#### Clinical Features

In addition to histologic identification of the organism, several diagnostic tests have been developed including a noninvasive serologic test for anti-*H. pylori* antibodies, fecal bacterial detection, and the urea breath test based on the generation of ammonia by bacterial urease. Gastric biopsy specimens also can be analyzed by the rapid urease test, bacterial culture, or polymerase chain reaction (PCR) assay for bacterial DNA. Effective treatments include combinations of antibiotics and proton pump inhibitors. Patients with *H. pylori* gastritis usually improve after treatment, although relapses can follow incomplete eradication or reinfection.

#### Autoimmune Gastritis

*Autoimmune gastritis* accounts for less than 10% of cases of chronic gastritis. In contrast with that caused by *H. pylori*, autoimmune gastritis typically spares the antrum and induces *hypergastrinemia* (Table 14-2). Autoimmune gastritis is characterized by

- Antibodies to parietal cells and intrinsic factor that can be detected in serum and gastric secretions

- Reduced serum pepsinogen I levels
- Antral endocrine cell hyperplasia
- Vitamin B<sub>12</sub> deficiency
- Defective gastric acid secretion (*achlorhydria*)

#### PATHOGENESIS

Autoimmune gastritis is associated with loss of parietal cells, which secrete acid and intrinsic factor. Deficient acid production stimulates gastrin release, resulting in hypergastrinemia and hyperplasia of antral gastrin-producing G cells. Lack of intrinsic factor disables ileal vitamin B<sub>12</sub> absorption, leading to B<sub>12</sub> deficiency and megaloblastic anemia (**pernicious anemia**); reduced serum concentration of pepsinogen I reflects chief cell loss. Although *H. pylori* can cause hypochlorhydria, it is not associated with achlorhydria or pernicious anemia, because the parietal and chief cell damage is not as severe as in autoimmune gastritis.

#### MORPHOLOGY

Autoimmune gastritis is characterized by diffuse **damage of the oxyntic** (acid-producing) **mucosa** within the body and fundus. Damage to the antrum and cardia typically is absent or mild. With **diffuse atrophy**, the oxyntic mucosa of the body and fundus appears markedly thinned, and rugal folds are lost. Neutrophils may be present, but the inflammatory infiltrate more commonly is composed of lymphocytes, macrophages, and plasma cells; in contrast with ***H. pylori* gastritis**, the inflammatory reaction most often is deep and centered on the gastric glands. **Parietal and chief cell loss** can be extensive, and **intestinal metaplasia** may develop.

#### Clinical Features

Antibodies to parietal cells and intrinsic factor are present early in disease, but pernicious anemia develops in only a minority of patients. The median age at diagnosis is 60 years, and there is a slight female predominance. Autoimmune gastritis often is associated with other autoimmune diseases but is not linked to specific human leukocyte antigen (HLA) alleles.

**Table 14-2** Characteristics of *Helicobacter pylori*-Associated and Autoimmune Gastritis

Feature	Location	
	<i>H. pylori</i> -Associated: Antrum	Autoimmune: Body
Inflammatory infiltrate	Neutrophils, subepithelial plasma cells	Lymphocytes, macrophages
Acid production	Increased to slightly decreased	Decreased
Gastrin	Normal to decreased	Increased
Other lesions	Hyperplastic/inflammatory polyps	Neuroendocrine hyperplasia
Serology	Antibodies to <i>H. pylori</i>	Antibodies to parietal cells (H <sup>+</sup> ,K <sup>+</sup> -ATPase, intrinsic factor)
Sequelae	Peptic ulcer, adenocarcinoma, lymphoma	Atrophy, pernicious anemia, adenocarcinoma, carcinoid tumor
Associations	Low socioeconomic status, poverty, residence in rural areas	Autoimmune disease; thyroiditis, diabetes mellitus, Graves disease

## Peptic Ulcer Disease

*Peptic ulcer disease* (PUD) most often is associated with *H. pylori* infection or NSAID use. In the US, the latter is becoming the most common cause of gastric ulcers as *H. pylori* infection rates fall and low-dose aspirin use in the aging population increases. PUD may occur in any portion of the gastrointestinal tract exposed to acidic gastric juices but is most common in the gastric antrum and first portion of the duodenum. PUD also may occur in the esophagus as a result of GERD or acid secretion by ectopic gastric mucosa, and in the small intestine secondary to gastric heteropia within a Meckel diverticulum.

### Epidemiology

PUD is common and is a frequent cause of physician visits worldwide. It leads to treatment of over 3 million people, 190,000 hospitalizations, and 5000 deaths in the United States each year. The lifetime risk of developing an ulcer is approximately 10% for males and 4% for females.

### PATHOGENESIS

*H. pylori* infection and NSAID use are the primary underlying causes of PUD. **The imbalances of mucosal defenses and damaging forces that cause chronic gastritis (Fig. 14–13) are also responsible for PUD.** Thus, PUD generally develops on a background of chronic gastritis. Although more than 70% of PUD cases are associated with *H. pylori* infection, only 5% to 10% of *H. pylori*-infected persons develop ulcers. It is probable that host factors as well as variation among *H. pylori* strains determine the clinical outcomes.

Gastric hyperacidity is fundamental to the pathogenesis of PUD. The acidity that drives PUD may be caused by *H. pylori* infection, parietal cell hyperplasia, excessive secretory responses, or impaired inhibition of stimulatory mechanisms such as gastrin release. For example, **Zollinger-Ellison syndrome**, characterized by multiple peptic ulcerations in the stomach, duodenum, and even jejunum, is caused by uncontrolled release of gastrin by a tumor and the resulting massive acid production. Cofactors in peptic ulcerogenesis include chronic NSAID use, as noted; cigarette smoking, which impairs mucosal blood flow and healing; and high-dose corticosteroids, which suppress prostaglandin synthesis and impair healing. Peptic ulcers are more frequent in persons with alcoholic cirrhosis, chronic obstructive pulmonary disease, chronic renal failure, and hyperparathyroidism. In the latter two conditions, hypercalcemia stimulates gastrin production and therefore increases acid secretion. Finally, psychologic stress may increase gastric acid production and exacerbate PUD.

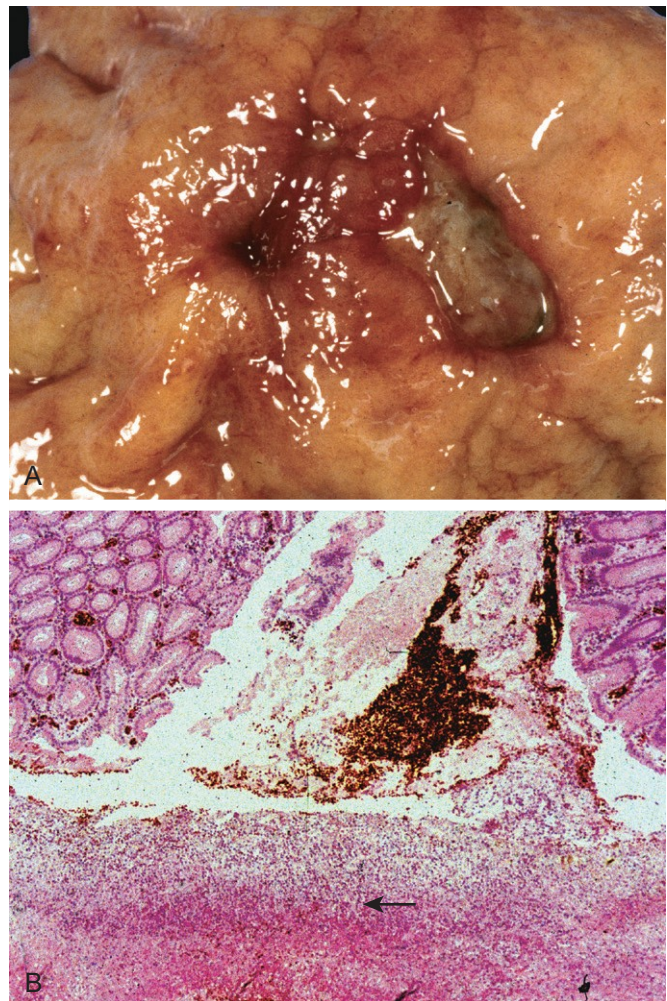
### MORPHOLOGY

Peptic ulcers are four times more common in the proximal duodenum than in the stomach. Duodenal ulcers usually occur within a few centimeters of the pyloric valve and involve the anterior duodenal wall. Gastric peptic ulcers are predominantly located near the interface of the body and antrum.

Peptic ulcers are solitary in more than 80% of patients. Lesions less than 0.3 cm in diameter tend to be shallow, whereas those over 0.6 cm are likely to be deeper. The classic peptic ulcer is a round to oval, **sharply punched-out defect** (Fig. 14–15, A). The base of peptic ulcers is smooth and clean as a result of peptic digestion of exudate and on histologic examination is composed of richly vascular granulation tissue (Fig. 14–15, B). Ongoing bleeding within the ulcer base may cause life-threatening hemorrhage. **Perforation** is a complication that demands emergent surgical intervention.

### Clinical Features

Peptic ulcers are chronic, recurring lesions that occur most often in middle-aged to older adults without obvious precipitating conditions, other than chronic gastritis. A majority of peptic ulcers come to clinical attention after patient complaints of *epigastric burning or aching pain*, although a significant fraction manifest with complications such as *iron deficiency anemia, frank hemorrhage, or perforation*. The pain tends to occur 1 to 3 hours after meals during the day, is worse at night, and is relieved by alkali or food. Nausea,



**Figure 14–15** Acute gastric perforation in a patient presenting with free air under the diaphragm. **A**, Mucosal defect with clean edges. **B**, The necrotic ulcer base (*arrow*) is composed of granulation tissue.



vomiting, bloating, and belching may be present. Healing may occur with or without therapy, but the tendency to develop ulcers later remains.

A variety of surgical approaches formerly were used to treat PUD, but current therapies are aimed at *H. pylori* eradication with antibiotics and neutralization of gastric acid, usually through use of proton pump inhibitors. These efforts have markedly reduced the need for surgical management, which is reserved primarily for treatment of bleeding or perforated ulcers. PUD causes much more morbidity than mortality.

## SUMMARY

### Acute and Chronic Gastritis

- The spectrum of *acute gastritis* ranges from asymptomatic disease to mild epigastric pain, nausea, and vomiting. Causative factors include any agent or disease that interferes with gastric mucosal protection. Acute gastritis can progress to *acute gastric ulceration*.
- The most common cause of chronic gastritis is *H. pylori* infection; most remaining cases are caused by *autoimmune gastritis*.
- *H. pylori* gastritis typically affects the antrum and is associated with increased gastric acid production. The induced mucosa-associated lymphoid tissue (MALT) can transform into lymphoma.
- *Autoimmune gastritis* causes atrophy of the gastric body oxyntic glands, which results in decreased gastric acid production, antral G cell hyperplasia, achlorhydria, and vitamin B<sub>12</sub> deficiency. Anti-parietal cell and anti-intrinsic factor antibodies typically are present.
- *Intestinal metaplasia* develops in both forms of chronic gastritis and is a risk factor for development of gastric adenocarcinoma.
- Peptic ulcer disease can be caused by *H. pylori* chronic gastritis and the resultant hyperchlorhydria or NSAID use. Ulcers can develop in the stomach or duodenum and usually heal after suppression of gastric acid production and, if present, eradication of the *H. pylori*.

## NEOPLASTIC DISEASE OF THE STOMACH

### Gastric Polyps

*Polyps*, nodules or masses that project above the level of the surrounding mucosa, are identified in up to 5% of upper gastrointestinal tract endoscopies. Polyps may develop as a result of epithelial or stromal cell hyperplasia, inflammation, ectopia, or neoplasia. Although many different types of polyps can occur in the stomach, only hyperplastic and inflammatory polyps, fundic gland polyps, and adenomas are considered here.

#### *Inflammatory and Hyperplastic Polyps*

Approximately 75% of all gastric polyps are *inflammatory* or *hyperplastic polyps*. They most commonly affect persons between 50 and 60 years of age, usually arising in a

background of chronic gastritis that initiates the injury and reactive hyperplasia that cause polyp growth. If associated with *H. pylori* gastritis, polyps may regress after bacterial eradication.

## MORPHOLOGY

In the stomach, inflammatory and hyperplastic polyps are essentially the same entity, with the distinction based solely on the degree of inflammation. The polyps frequently are multiple and characteristically are ovoid in shape, less than 1 cm in diameter, and covered by a smooth surface. On microscopic examination, polyps have irregular, cystically dilated, and elongated foveolar glands. The lamina propria typically is edematous with variable degrees of acute and chronic inflammation, and surface erosions may be present.

The frequency with which **dysplasia**, a precancerous in situ lesion, develops in inflammatory or hyperplastic polyps correlates with size; there is a significant increase in risk in polyps larger than 1.5 cm.

### *Fundic Gland Polyps*

*Fundic gland polyps* occur sporadically and in persons with familial adenomatous polyposis (FAP) but do not have neoplastic potential. They are, however, worth mentioning here because their incidence has increased markedly as a result of the use of proton pump inhibitors. This likely results from increased gastrin secretion, in response to reduced acidity, and glandular hyperplasia driven by gastrin. Fundic gland polyps may be asymptomatic or associated with nausea, vomiting, or epigastric pain. These well-circumscribed polyps occur in the gastric body and fundus, often are multiple, and are composed of cystically dilated, irregular glands lined by flattened parietal and chief cells.

### *Gastric Adenoma*

Gastric adenomas represent as many as 10% of all gastric polyps. Their incidence increases with age and varies among different populations in parallel with that of gastric adenocarcinoma. Patients usually are between 50 and 60 years of age, and males are affected three times more often than females. Similar to other forms of gastric dysplasia, adenomas almost always occur on a background of chronic gastritis with atrophy and intestinal metaplasia. The risk for development of adenocarcinoma in gastric adenomas is related to the size of the lesion and is particularly elevated with lesions greater than 2 cm in diameter. Overall, carcinoma may be present in up to 30% of gastric adenomas.

## MORPHOLOGY

Gastric adenomas are most commonly located in the antrum and typically are composed of intestinal-type columnar epithelium. By definition, all gastrointestinal adenomas exhibit epithelial dysplasia, which can be classified as low- or high-grade. Both grades may include enlargement, elongation, and hyperchromasia of epithelial cell nuclei, epithelial crowding, and pseudostratification. High-grade dysplasia is characterized by more severe cytologic atypia and irregular architecture, including glandular budding and gland-within-gland, or cribriform, structures.

## Gastric Adenocarcinoma

Adenocarcinoma is the most common malignancy of the stomach, comprising more than 90% of all gastric cancers. Early symptoms resemble those of chronic gastritis, including dyspepsia, dysphagia, and nausea. As a result, in low-incidence regions such as the United States, the cancer is often at advanced stages when clinical manifestations such as weight loss, anorexia, altered bowel habits, anemia, and hemorrhage trigger diagnostic evaluation.

### Epidemiology

Gastric cancer rates vary markedly with geography. The incidence is up to 20 times higher in Japan, Chile, Costa Rica, and Eastern Europe than in North America, northern Europe, Africa, and Southeast Asia. Mass endoscopic screening programs can be successful in regions of high incidence, such as Japan, where 35% of newly detected cases are *early gastric cancer*, or tumors limited to the mucosa and submucosa. Unfortunately, mass screening programs are not cost-effective in regions in which the incidence is low, and less than 20% of cases are detected at an early stage in North America and northern Europe.

Gastric cancer is more common in lower socioeconomic groups and in persons with *multifocal mucosal atrophy and intestinal metaplasia*. PUD does not impart an increased risk of gastric cancer, but patients who have had *partial gastrectomies* for PUD have a slightly higher risk of developing cancer in the residual gastric stump as a result of hypochlorhydria, bile reflux, and chronic gastritis.

In the United States, *gastric cancer rates dropped by more than 85% during the 20th century*. Similar declines have been reported in many other Western countries, reflecting the importance of environmental and dietary factors. Despite this decrease in overall gastric adenocarcinoma incidence, *cancer of the gastric cardia is on the rise*. This trend probably is related to increased rates of Barrett esophagus and may reflect the growing prevalence of chronic GERD and obesity.

### PATHOGENESIS

Gastric cancers are genetically heterogeneous but certain molecular alterations are common. We will consider these first to be followed by the role of *H. pylori*-induced chronic inflammation and the association of a subset of gastric cancers with EBV infection.

- **Mutations:** While the majority of gastric cancers are not hereditary, mutations identified in familial gastric cancer have provided important insights into mechanisms of carcinogenesis in sporadic cases. Germline mutations in *CDH1*, which encodes E-cadherin, a protein that contributes to epithelial intercellular adhesion, are associated with familial gastric cancers, usually of the diffuse type. Mutations in *CDH1* are present in about 50% of diffuse gastric tumors, while E-cadherin expression is drastically decreased in the rest, often by methylation of the *CDH1* promoter. **Thus, the loss of E-cadherin function seems to be a key step in the development of diffuse gastric cancer.**

In contrast to *CDH1*, patients with familial adenomatous polyposis (FAP) who have germline mutations in

**adenomatous polyposis coli (APC) genes** have an increased risk of intestinal-type gastric cancer. Sporadic intestinal-type gastric cancer is associated with several genetic abnormalities including acquired mutations of  $\beta$ -catenin, a protein that binds to both E-cadherin and APC protein; microsatellite instability; and hypermethylation of genes including *TGF $\beta$ R11*, *BAX*, *IGFR11*, and *p16/INK4a*. *TP53* mutations are present in a majority of sporadic gastric cancers of both histologic types.

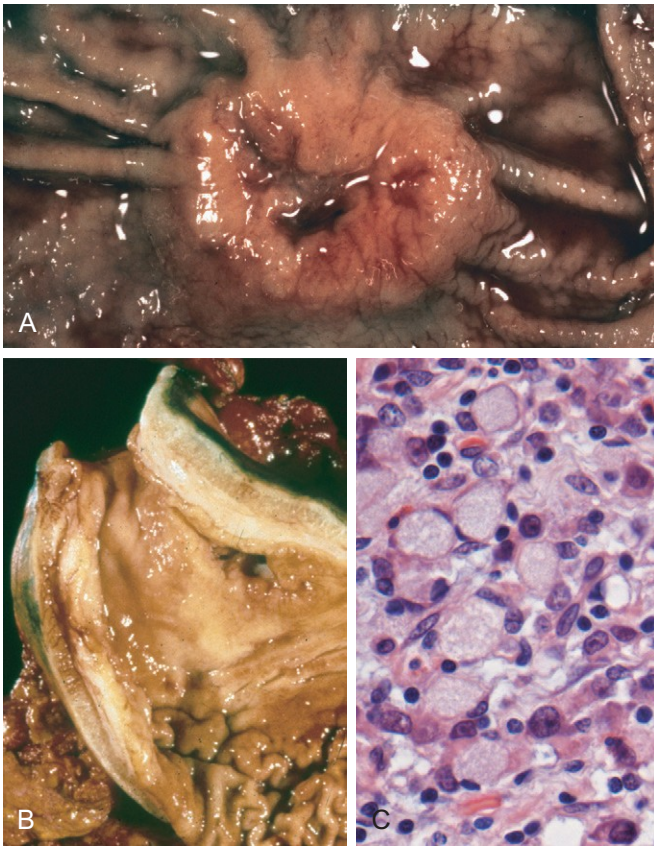
- ***H. pylori*:** Chronic gastritis, most commonly due to *H. pylori* infection, promotes the development and progression of cancers that may be induced by diverse genetic alterations (Chapter 5). As is the case with many forms of chronic inflammation, *H. pylori*-induced chronic gastritis is associated with increased production of proinflammatory proteins, such as interleukin-1 $\beta$  (IL-1 $\beta$ ) and tumor necrosis factor (TNF). It is therefore not surprising that polymorphisms associated with enhanced production of these cytokines confer increased risk of chronic gastritis-associated intestinal-type gastric cancer in those with coexisting *H. pylori* infection.
- **EBV:** While *H. pylori* is most commonly associated with gastric cancer, approximately 10% of gastric adenocarcinomas are associated with Epstein-Barr virus (EBV) infection. Although the precise role of EBV in the development of gastric adenocarcinomas remains to be defined, it is notable that EBV episomes in these tumors frequently are clonal, suggesting that infection preceded neoplastic transformation. Further, *TP53* mutations are uncommon in the EBV-positive gastric tumors, suggesting that the molecular pathogenesis of these cancers is distinct from that of other gastric adenocarcinomas. Morphologically, EBV-positive tumors tend to occur in the proximal stomach and most commonly have a diffuse morphology with a marked lymphocytic infiltrate.

### MORPHOLOGY

Gastric adenocarcinomas are classified according to their location in the stomach as well as gross and histologic morphology. The **Lauren classification** that separates gastric cancers into **intestinal** and **diffuse** types correlates with distinct patterns of molecular alterations, as discussed above. Intestinal-type cancers tend to be bulky (Fig. 14-16, A) and are composed of glandular structures similar to esophageal and colonic adenocarcinoma. Intestinal-type adenocarcinomas typically grow along broad cohesive fronts to form either an exophytic mass or an ulcerated tumor. The neoplastic cells often contain apical mucin vacuoles, and abundant mucin may be present in gland lumina.

Diffuse gastric cancers display an infiltrative growth pattern (Fig. 14-16, B) and are composed of discohesive cells with large mucin vacuoles that expand the cytoplasm and push the nucleus to the periphery, creating a **signet ring cell** morphology (Fig. 14-16, C). These cells permeate the mucosa and stomach wall individually or in small clusters. A mass may be difficult to appreciate in diffuse gastric cancer, but these infiltrative tumors often evoke a **desmoplastic** reaction that stiffens the gastric wall and may cause diffuse rugal flattening and a rigid, thickened wall that imparts a "leather bottle" appearance termed **linitis plastica**.





**Figure 14-16** Gastric adenocarcinoma. **A**, Intestinal-type adenocarcinoma consisting of an elevated mass with heaped-up borders and central ulceration. Compare with the peptic ulcer in [Figure 14-15, A](#). **B**, Linitis plastica. The gastric wall is markedly thickened, and rugal folds are partially lost. **C**, Signet ring cells with large cytoplasmic mucin vacuoles and peripherally displaced, crescent-shaped nuclei.

### Clinical Features

Intestinal-type gastric cancer predominates in high-risk areas and develops from precursor lesions including flat dysplasia and adenomas. The mean age at presentation is 55 years, and the male-to-female ratio is 2:1. By contrast, the incidence of diffuse gastric cancer is relatively uniform across countries, there are no identified precursor lesions, and the disease occurs at similar frequencies in males and females. Of note, *the remarkable decrease in gastric cancer incidence applies only to the intestinal type*, which is most closely associated with atrophic gastritis and intestinal metaplasia. As a result, the incidences of intestinal and diffuse types of gastric cancers are now similar in some regions.

*The depth of invasion and the extent of nodal and distant metastasis at the time of diagnosis remain the most powerful prognostic indicators for gastric cancer.* Local invasion into the duodenum, pancreas, and retroperitoneum also is characteristic. When possible, surgical resection remains the preferred treatment for gastric adenocarcinoma. After surgical resection, the 5-year survival rate for early gastric cancer can exceed 90%, even if lymph node metastases are present. By contrast, the 5-year survival rate for advanced gastric cancer remains below 20%, in large part because current chemotherapy regimens are minimally effective. Because of the advanced stage at which most

gastric cancers are discovered in the United States, the overall 5-year survival is less than 30%.

### Lymphoma

Although extranodal lymphomas can arise in virtually any tissue, they do so most commonly in the gastrointestinal tract, particularly the stomach. In allogeneic hematopoietic stem cell and organ transplant recipients, the bowel also is the most frequent site for Epstein-Barr virus–positive B cell lymphoproliferations. Nearly 5% of all gastric malignancies are primary lymphomas, the most common of which are indolent extranodal marginal zone B cell lymphomas. In the gut, these tumors often are referred to as lymphomas of *mucosa-associated lymphoid tissue* (MALT), or *MALTomas*. This entity and the second most common primary lymphoma of the gut, diffuse large B cell lymphoma, are discussed in Chapter 11.

### Carcinoid Tumor

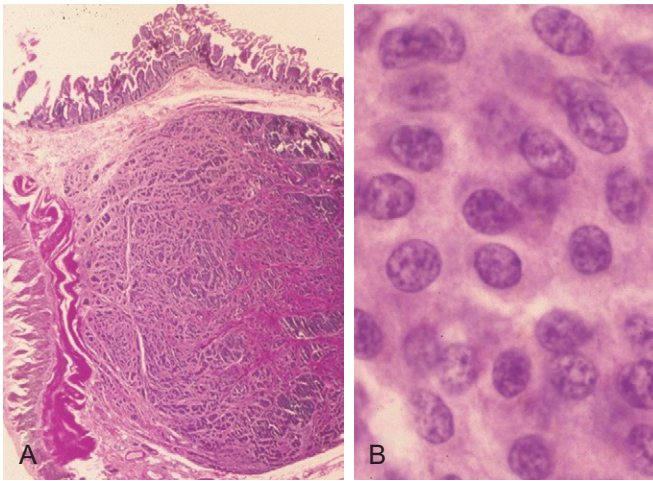
Carcinoid tumors arise from neuroendocrine organs (e.g., the endocrine pancreas) and neuroendocrine-differentiated gastrointestinal epithelia (e.g., G-cells). A majority are found in the gastrointestinal tract, and more than 40% occur in the small intestine. The tracheobronchial tree and lungs are the next most commonly involved sites. Gastric carcinoids may be associated with endocrine cell hyperplasia, chronic atrophic gastritis, and Zollinger-Ellison syndrome. These tumors were called “carcinoid” because they are slower growing than carcinomas. The most current WHO classification describes these as low- or intermediate grade neuroendocrine tumors. The grade is based on mitotic activity and the fraction of cells immunohistochemically positive for Ki67, a mitotic marker. However, it is important to recognize that site within the GI tract and extent of local invasion are also important prognostic indicators (see later). High-grade neuroendocrine tumors, termed *neuroendocrine carcinoma*, frequently display necrosis and, in the GI tract, are most common in the jejunum.

### MORPHOLOGY

Carcinoid tumors are intramural or submucosal masses that create small polypoid lesions ([Fig. 14-17, A](#)). The tumors are yellow or tan in appearance and elicit an intense desmoplastic reaction that may cause kinking of the bowel and obstruction. On histologic examination, carcinoid tumors are composed of islands, trabeculae, strands, glands, or sheets of uniform cells with scant, pink granular cytoplasm and a round to oval stippled nucleus ([Fig. 14-17, B](#)).

### Clinical Features

The peak incidence of carcinoid tumors is in the sixth decade, but they may appear at any age. Symptoms are determined by the hormones produced. For example, the *carcinoid syndrome* is caused by vasoactive substances secreted by the tumor that cause cutaneous flushing, sweating, bronchospasm, colicky abdominal pain, diarrhea, and right-sided cardiac valvular fibrosis. When tumors are



**Figure 14-17** Gastrointestinal carcinoid tumor (neuroendocrine tumor). **A**, Carcinoid tumors often form a submucosal nodule composed of tumor cells embedded in dense fibrous tissue. **B**, High magnification shows the bland cytology that typifies carcinoid tumors. The chromatin texture, with fine and coarse clumps, frequently assumes a “salt and pepper” pattern. Despite their innocuous appearance, carcinoids can be aggressive.

confined to the intestine, the vasoactive substances released are metabolized to inactive forms by the liver—a “first-pass” effect similar to that seen with oral drugs. Thus, carcinoid syndrome occurs in less than 10% of patients and is *strongly associated with metastatic disease*.

*The most important prognostic factor for gastrointestinal carcinoid tumors is location:*

- *Foregut carcinoid tumors*, those found within the stomach, duodenum proximal to the ligament of Treitz, and esophagus, rarely metastasize and generally are cured by resection. Although rare, duodenal gastrin-producing carcinoid tumors, *gastrinomas*, have been associated with proton pump inhibitor therapy.
- *Midgut carcinoid tumors* that arise in the jejunum and ileum often are multiple and tend to be aggressive. In these tumors, greater depth of local invasion, increased size, and presence of necrosis and mitosis are associated with poor outcome.
- *Hindgut carcinoids* arising in the appendix and colorectum typically are discovered incidentally. Those in the appendix occur at any age and are almost uniformly benign. Rectal carcinoid tumors tend to produce polypeptide hormones and may manifest with abdominal pain and weight loss; they only occasionally metastasize.

## Gastrointestinal Stromal Tumor

A wide variety of mesenchymal neoplasms may arise in the stomach. Many are named according to the cell type they most resemble; for example, smooth muscle tumors are called *leiomyomas* or *leiomyosarcomas*, nerve sheath tumors are termed *schwannomas*, and those resembling glomus bodies in the nail beds and at other sites are termed *glomus tumors*. These tumors are all rare and are not discussed here. *Gastrointestinal stromal tumor (GIST)* is the

most common mesenchymal tumor of the abdomen, and more than half of these tumors occur in the stomach.

### Epidemiology

Overall, GISTs are slightly more common in males. The peak incidence of gastric GIST is around 60 years of age, with less than 10% occurring in persons younger than 40 years of age.

### PATHOGENESIS

Approximately **75% to 80% of all GISTs have oncogenic, gain-of-function mutations of the gene encoding the tyrosine kinase c-KIT**, which is the receptor for stem cell factor. Another 8% of GISTs have mutations that activate a related tyrosine kinase, platelet-derived growth factor receptor A (PDGFRA); thus activating mutations in tyrosine kinases are found in virtually all GISTs. However, either mutation is sufficient for tumorigenesis, and *c-KIT* and *PDGFRA* mutations are almost never found in a single tumor. GISTs appear to arise from, or share a common stem cell with, the interstitial cells of Cajal, which express c-KIT, are located in the muscularis propria, and serve as pacemaker cells for gut peristalsis.

### MORPHOLOGY

Primary gastric GISTs usually form a solitary, well-circumscribed, fleshy, submucosal mass. Metastases may form multiple small serosal nodules or fewer large nodules in the liver; spread outside of the abdomen is uncommon. GISTs can be composed of thin, elongated **spindle cells** or plumper **epithelioid cells**. The most useful diagnostic marker is c-KIT, consistent with the relationship between GISTs and interstitial cells of Cajal, which is immunohistochemically detectable in 95% of these tumors.

### Clinical Features

Symptoms of GISTs at presentation may be related to mass effects or mucosal ulceration. Complete surgical resection is the primary treatment for localized gastric GIST. The prognosis correlates with tumor size, mitotic index, and location, *with gastric GISTs being somewhat less aggressive than those arising in the small intestine*. Recurrence or metastasis is rare for gastric GISTs less than 5 cm across but common for mitotically active tumors larger than 10 cm. Patients with unresectable, recurrent, or metastatic disease often respond to *imatinib*, an inhibitor of the tyrosine kinase activity of c-KIT and PDGFRA that is also effective in suppressing BCR-ABL kinase activity in chronic myelogenous leukemia (Chapter 11). Unfortunately, GISTs eventually become resistant to imatinib, and other kinase inhibitors are now being evaluated in imatinib-resistant disease.

### SUMMARY

#### Gastric Polyps and Tumors

- *Inflammatory and hyperplastic gastric polyps* are reactive lesions associated with chronic gastritis. Risk of dysplasia increases with polyp size.



- *Gastric adenomas* develop in a background of chronic gastritis and are particularly associated with intestinal metaplasia and mucosal (glandular) atrophy. Adenocarcinoma frequently arises in gastric adenomas, which therefore require complete excision and surveillance to detect recurrence.
- Gastric adenocarcinoma incidence varies markedly with geography and also is more common in lower socioeconomic groups.
- Gastric adenocarcinomas are classified according to location and gross and histologic morphology. Those with an *intestinal* histologic pattern tend to form bulky tumors and may be ulcerated, whereas those composed of *signet ring cells* typically display a diffuse infiltrative growth pattern that may thicken the gastric wall (*linitis plastica*) without forming a discrete mass.
- *H. pylori* infection is the most common etiologic agent for gastric adenocarcinoma, but other associations, including chronic atrophic gastritis and EBV infection, suggest

several pathways of neoplastic transformation are operative.

- *Primary gastric lymphomas* most often are derived from the mucosa-associated lymphoid tissue whose development is induced by chronic gastritis.
- *Carcinoid tumors* arise from the diffuse components of the endocrine system, and are most common in the gastrointestinal tract, particularly the small intestine. The single most important prognostic factor is location: Tumors of the small intestine tend to be most aggressive, while those of the appendix are almost always benign.
- *Gastrointestinal stromal tumor (GIST)* is the most common mesenchymal tumor of the abdomen, occurs most often in the stomach; it arises from benign pacemaker cells, also known as the interstitial cells of Cajal. A majority of tumors have activating mutations in either the c-KIT or the PDGFRA tyrosine kinases and respond to kinase inhibitors.

## SMALL AND LARGE INTESTINES

The small intestine and colon account for most of the length of the gastrointestinal tract and are the sites of a wide variety of diseases, many of which affect nutrient and water transport. Perturbation of these processes can cause malabsorption and diarrhea. The intestines are also the principal site where the immune system interfaces with a diverse array of antigens present in food and gut microbes. Indeed, intestinal bacteria outnumber eukaryotic cells in the human body by ten-fold. Thus, it is not surprising that the small intestine and colon frequently are involved by infectious and inflammatory processes. Finally, the colon is the most common site of gastrointestinal neoplasia in Western populations.

## INTESTINAL OBSTRUCTION

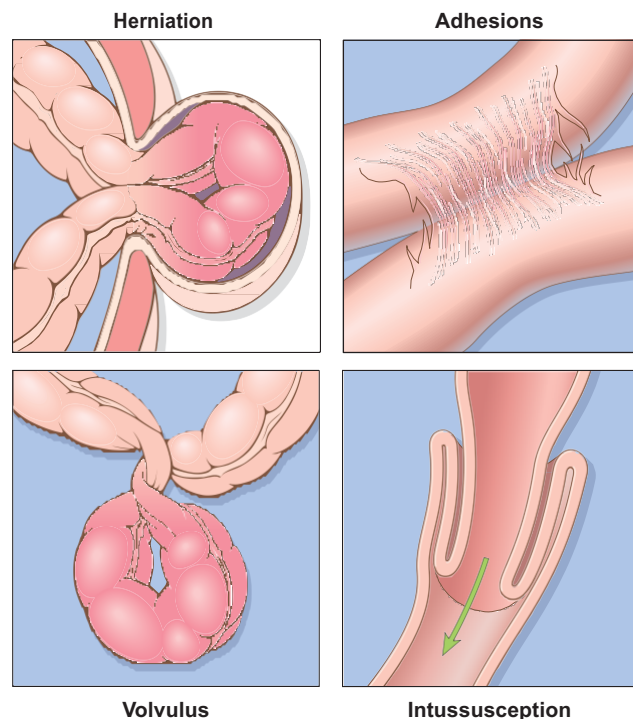
Obstruction of the gastrointestinal tract may occur at any level, but the small intestine is most often involved because of its relatively narrow lumen. Collectively, *hernias*, *intestinal adhesions*, *intussusception*, and *volvulus* account for 80% of mechanical obstructions (Fig. 14-18), while tumors and infarction account for most of the remainder. The clinical manifestations of intestinal obstruction include abdominal pain and distention, vomiting, and constipation. Surgical intervention usually is required in cases involving mechanical obstruction or severe infarction.

### Hirschsprung Disease

*Hirschsprung disease* occurs in approximately 1 of 5000 live births and stems from a congenital defect in colonic innervation. It may be isolated or occur in combination with other developmental abnormalities. It is more common in males but tends to be more severe in females. Siblings

of patients have an increased risk of Hirschsprung disease.

Patients typically present as neonates with failure to pass meconium in the immediate postnatal period followed by obstructive constipation. The major threats to life



**Figure 14-18** Intestinal obstruction. The four major mechanical causes of intestinal obstruction are (1) herniation of a segment in the umbilical or inguinal regions, (2) adhesion between loops of intestine, (3) volvulus, and (4) intussusception.

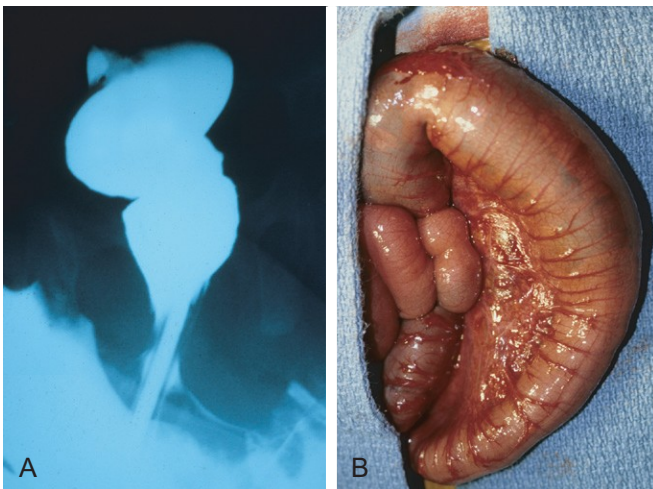
are enterocolitis, fluid and electrolyte disturbances, perforation, and peritonitis. Surgical resection of the aganglionic segment with anastomosis of the normal colon to the rectum is effective, although it may take years for patients to attain normal bowel function and continence.

## PATHOGENESIS

The enteric neuronal plexus develops from neural crest cells that migrate into the bowel wall during embryogenesis. Hirschsprung disease, also known as **congenital aganglionic megacolon**, results when the normal migration of neural crest cells from cecum to rectum is disrupted. This produces a distal intestinal segment that lacks both the Meissner submucosal plexus and the Auerbach myenteric plexus (“aganglionosis”). Coordinated peristaltic contractions are absent and the subsequent functional obstruction results in dilation proximal to the affected segment. While the mechanisms underlying this defective neural crest cell migration are unknown, **heterozygous loss-of-function mutations in the receptor tyrosine kinase RET account for a majority of familial cases** and approximately 15% of sporadic cases. However, mutations also occur in other genes, only some of which have been identified, and modifying genes or environmental factors also play a role.

## MORPHOLOGY

Hirschsprung disease always affects the rectum, but the length of the additional involved segments varies. Most cases are limited to the rectum and sigmoid colon, but severe disease can involve the entire colon. The aganglionic region may have a grossly normal or contracted appearance, while the normally innervated proximal colon may undergo progressive dilation as a result of the distal obstruction (Fig. 14–19). Diagnosis of Hirschsprung disease requires demonstrating the absence of ganglion cells in the affected segment.



**Figure 14–19** Hirschsprung disease. **A**, Preoperative barium enema study showing constricted rectum (bottom of the image) and dilated sigmoid colon. Ganglion cells were absent in the rectum, but present in the sigmoid colon. **B**, Corresponding intraoperative appearance of the dilated sigmoid colon.

(Courtesy of Dr. Aliya Husain, The University of Chicago, Chicago, Illinois.)

## Abdominal Hernia

Any weakness or defect in the wall of the peritoneal cavity may permit protrusion of a serosa-lined pouch of peritoneum called a *hernia sac*. Acquired hernias most commonly occur anteriorly, through the inguinal and femoral canals or umbilicus, or at sites of surgical scars. These are of concern because of visceral protrusion (*external herniation*). This is particularly true of inguinal hernias, which tend to have narrow orifices and large sacs. Small bowel loops are herniated most often, but portions of omentum or large bowel also protrude, and any of these may become entrapped. Pressure at the neck of the pouch may impair venous drainage, leading to stasis and edema. These changes increase the bulk of the herniated loop, leading to permanent entrapment, or *incarceration*, and over time, arterial and venous compromise, or *strangulation*, can result in infarction.

## SUMMARY

### Intestinal Obstruction

- *Hirschsprung disease* is the result of defective neural crest cell migration from cecum to rectum. It gives rise to functional obstruction.
- *Abdominal herniation* may occur through any weakness or defect in the wall of the peritoneal cavity, including inguinal and femoral canals, umbilicus, and sites of surgical scarring.

## VASCULAR DISORDERS OF BOWEL

The greater portion of the gastrointestinal tract is supplied by the celiac, superior mesenteric, and inferior mesenteric arteries. As they approach the intestinal wall, the superior and inferior mesenteric arteries fan out to form the mesenteric arcades. Interconnections between arcades, as well as collateral supplies from the proximal celiac and distal pudendal and iliac circulations, make it possible for the small intestine and colon to tolerate slowly progressive loss of the blood supply from one artery. By contrast, acute compromise of any major vessel can lead to infarction of several meters of intestine.

## Ischemic Bowel Disease

Ischemic damage to the bowel wall can range from *mucosal infarction*, extending no deeper than the muscularis mucosa; to *mural infarction* of mucosa and submucosa; to *transmural infarction* involving all three layers of the wall. While mucosal or mural infarctions often are secondary to acute or chronic *hypoperfusion*, transmural infarction is generally caused by acute vascular obstruction. Important causes of acute arterial obstruction include severe *atherosclerosis* (which is often prominent at the origin of mesenteric vessels), *aortic aneurysm*, *hypercoagulable states*, *oral contraceptive use*, and *embolization of cardiac vegetations or aortic atheromas*. Intestinal hypoperfusion can also be associated with *cardiac failure*, *shock*, *dehydration*, or *vasoconstrictive drugs*. Systemic *vasculitides*, such as polyarteritis nodosum, Hensch-Schönlein purpura, or Wegener granulomatosis,



also may damage intestinal arteries. Mesenteric venous thrombosis can also lead to ischemic disease, but is uncommon. Other causes include invasive neoplasms, cirrhosis, portal hypertension, trauma, or abdominal masses that compress the portal drainage.

## PATHOGENESIS

Intestinal responses to ischemia occur in two phases. The initial hypoxic injury occurs at the onset of vascular compromise and, although some damage occurs, intestinal epithelial cells are relatively resistant to transient hypoxia. The second phase, reperfusion injury, is initiated by restoration of the blood supply and associated with the greatest damage. In severe cases multiorgan failure may occur. While the underlying mechanisms of reperfusion injury are incompletely understood, they involve free radical production, neutrophil infiltration, and release of inflammatory mediators, such as complement proteins and cytokines (Chapter 10). **The severity of vascular compromise, time frame during which it develops, and vessels affected are the major variables that determine severity of ischemic bowel disease.** Two aspects of intestinal vascular anatomy also contribute to the distribution of ischemic damage:

- Intestinal segments at the end of their respective arterial supplies are particularly susceptible to ischemia. These **watershed zones** include the splenic flexure, where the superior and inferior mesenteric arterial circulations terminate, and, to a lesser extent, the sigmoid colon and rectum where inferior mesenteric, pudendal, and iliac arterial circulations end. Generalized hypotension or hypoxemia can therefore cause localized injury, and ischemic disease should be considered in the differential diagnosis for focal colitis of the splenic flexure or rectosigmoid colon.
- Intestinal capillaries run alongside the glands, from crypt to surface, before making a hairpin turn at the surface to empty into the postcapillary venules. This configuration allows oxygenated blood to supply crypts but leaves the surface epithelium vulnerable to ischemic injury. This anatomy protects the crypts, which contain the epithelial stem cells that are necessary to repopulate the surface. Thus, surface epithelial atrophy, or even necrosis with consequent sloughing, with normal or hyperproliferative crypts constitutes a morphologic signature of ischemic intestinal disease.

## MORPHOLOGY

Despite the increased susceptibility of watershed zones, **mucosal and mural infarction** may involve any level of the gut from stomach to anus. Disease frequently is segmental and patchy in distribution, and the mucosa is hemorrhagic and often ulcerated. The bowel wall is thickened by edema that may involve the mucosa or extend into the submucosa and muscularis propria. With severe disease, pathologic changes include extensive mucosal and submucosal hemorrhage and necrosis, but serosal hemorrhage and serositis generally are absent. Damage is more pronounced in acute arterial thrombosis and **transmural infarction**. Blood-tinged mucus or blood accumulates within the lumen.

Coagulative necrosis of the muscularis propria occurs within 1 to 4 days and may be associated with purulent serositis and perforation.

In **mesenteric venous thrombosis**, arterial blood continues to flow for a time, resulting in a less abrupt transition from affected to normal bowel. However, propagation of the thrombus may lead to secondary involvement of the splanchnic bed. The ultimate result is similar to that produced by acute arterial obstruction, because impaired venous drainage eventually prevents entry of oxygenated arterial blood.

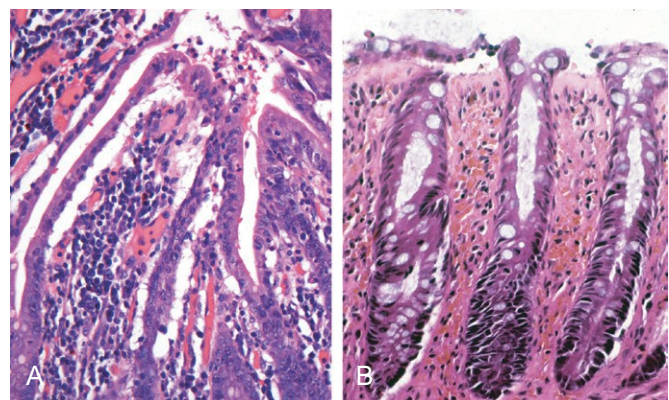
Microscopic examination of ischemic intestine demonstrates **atrophy or sloughing of surface epithelium** (Fig. 14–20, A). By contrast, crypts may be hyperproliferative. Inflammatory infiltrates initially are absent in acute ischemia, but neutrophils are recruited within hours of reperfusion. Chronic ischemia is accompanied by fibrous scarring of the lamina propria (Fig. 14–20, B) and, uncommonly, stricture formation. In acute phases of ischemic damage, bacterial superinfection and enterotoxin release may induce pseudomembrane formation that can resemble *Clostridium difficile*-associated pseudomembranous colitis (discussed later).

## Clinical Features

Ischemic bowel disease tends to occur in older persons with coexisting cardiac or vascular disease. Acute transmural infarction typically manifests with sudden, severe abdominal pain and tenderness, sometimes accompanied by nausea, vomiting, bloody diarrhea, or grossly melanotic stool. This presentation may progress to shock and vascular collapse within hours as a result of blood loss. Peristaltic sounds diminish or disappear, and muscular spasm creates boardlike rigidity of the abdominal wall. Because these physical signs overlap with those of other abdominal emergencies, including acute appendicitis, perforated ulcer, and acute cholecystitis, the diagnosis of intestinal infarction may be delayed or missed, with disastrous consequences. As the mucosal barrier breaks down, bacteria enter the circulation and sepsis can develop; the mortality rate may exceed 50%.

The overall progression of ischemic enteritis depends on the underlying cause and severity of injury:

- *Mucosal and mural infarctions* by themselves may not be fatal. However, these may progress to more extensive,



**Figure 14–20** Ischemia. **A**, Characteristic attenuated and partially detached villous epithelium in acute jejunal ischemia. Note the hyperchromatic nuclei of proliferating crypt cells. **B**, Chronic colonic ischemia with atrophic surface epithelium and fibrotic lamina propria.

transmural infarction if the vascular supply is not restored by correction of the insult or, in chronic disease, by development of adequate collateral supplies.

- *Chronic ischemia* may masquerade as inflammatory bowel disease, with episodes of bloody diarrhea interspersed with periods of healing.
- *CMV infection* causes ischemic gastrointestinal disease as a consequence of the viral tropism for and infection of endothelial cells. CMV infection can be a complication of immunosuppressive therapy (Chapter 8).
- *Radiation enterocolitis* occurs when the gastrointestinal tract is irradiated. In addition to epithelial damage, radiation-induced vascular injury may be significant and produce changes that are similar to ischemic disease. In addition to clinical history, the presence of bizarre “radiation fibroblasts” within the stroma may provide an important clue to the etiology. Acute radiation enteritis manifests as anorexia, abdominal cramps, and a malabsorptive diarrhea, while chronic radiation enteritis or colitis often is more indolent and may present as an inflammatory colitis.
- *Necrotizing enterocolitis* is an acute disorder of the small and large intestines that can result in transmural necrosis. It is the most common acquired gastrointestinal emergency of neonates, particularly those who are premature or of low birth weight, and occurs most often when oral feeding is initiated (Chapter 6). Ischemic injury generally is considered to contribute to its pathogenesis.
- *Angiodysplasia* is characterized by malformed submucosal and mucosal blood vessels. It occurs *most often in the cecum or right colon*, and usually presents after the sixth decade of life. Although the prevalence of angiodysplasia is less than 1% in the adult population, *it accounts for 20% of major episodes of lower intestinal bleeding; intestinal hemorrhage may be chronic and intermittent or acute and massive*. The pathogenesis is unknown.

## Hemorrhoids

*Hemorrhoids* affect about 5% of the general population. Simply put, hemorrhoids are dilated anal and perianal collateral vessels that connect the portal and caval venous systems to relieve elevated venous pressure within the hemorrhoid plexus. Thus, although hemorrhoids are both more common and less serious than esophageal varices, the pathogenesis of these lesions is similar. Common factors that predispose to hemorrhoids are constipation and associated straining, which increase intra-abdominal and venous pressures, venous stasis of pregnancy, and portal hypertension.

### MORPHOLOGY

Collateral vessels within the inferior hemorrhoidal plexus are located below the anorectal line and are termed **external hemorrhoids**, while those that result from dilation of the superior hemorrhoidal plexus within the distal rectum are referred to as **internal hemorrhoids**. On histologic examination, hemorrhoids consist of thin-walled, dilated,

submucosal vessels that protrude beneath the anal or rectal mucosa. In their exposed position, they are subject to trauma and tend to become inflamed, thrombosed, and, in the course of time, recanalized. Superficial ulceration may occur.

### Clinical Features

Hemorrhoids often manifest with pain and rectal bleeding, particularly bright red blood seen on toilet tissue. Except in pregnant women, hemorrhoids are rarely encountered in persons younger than 30 years of age. Hemorrhoids also may develop as a result of portal hypertension, where the implications are more ominous. Hemorrhoidal bleeding generally is not a medical emergency; treatment options include sclerotherapy, rubber band ligation, and infrared coagulation. In severe cases, hemorrhoids may be removed surgically by *hemorrhoidectomy*.

## SUMMARY

### Vascular Disorders of Bowel

- Intestinal ischemia can occur as a result of either *arterial or venous obstruction*.
- *Ischemic bowel disease* resulting from hypoperfusion is most common at the splenic flexure, sigmoid colon, and rectum; these are *watershed zones* where two arterial circulations terminate.
- *Systemic vasculitides and infectious diseases* (e.g., CMV infection) can cause vascular disease that is not confined to the gastrointestinal tract.
- *Angiodysplasia* is a common cause of major lower gastrointestinal bleeding in the elderly.
- *Hemorrhoids* are collateral vessels that form to allow resolution of venous hypertension.

## DIARRHEAL DISEASE

### Malabsorptive Diarrhea

Diarrhea is a common symptom of many intestinal diseases, including those due to infection, inflammation, ischemia, malabsorption, and nutritional deficiency. This section focuses primarily on *malabsorption*, which manifests most commonly as *chronic diarrhea* and is characterized by defective absorption of fats, fat- and water-soluble vitamins, proteins, carbohydrates, electrolytes and minerals, and water. Other disorders associated with *secretory* and *exudative* types of diarrhea (e.g., cholera and inflammatory bowel disease, respectively) are addressed in separate sections.

Chronic malabsorption causes weight loss, anorexia, abdominal distention, borborygmi, and muscle wasting. A hallmark of malabsorption is *steatorrhea*, characterized by excessive fecal fat and bulky, frothy, greasy, yellow or clay-colored stools. *The chronic malabsorptive disorders most commonly encountered in the United States are pancreatic insufficiency, celiac disease, and Crohn disease*. Intestinal graft-versus-host disease is an important cause of both



malabsorption and diarrhea after allogeneic hematopoietic stem cell transplantation. Environmental enteropathy (previously known as tropical sprue) is pervasive in some communities within developing countries.

*Diarrhea* is defined as an increase in stool mass, frequency, or fluidity, typically to volumes greater than 200 mL per day. In severe cases stool volume can exceed 14 L per day and, without fluid resuscitation, result in death. Painful, bloody, small-volume diarrhea is known as *dysentery*. Diarrhea can be classified into four major categories:

- *Secretory diarrhea* is characterized by isotonic stool and persists during fasting.
- *Osmotic diarrhea*, such as that occurring with lactase deficiency, is due to osmotic forces exerted by unabsorbed luminal solutes. The diarrheal fluid is more than 50 mOsm more concentrated than plasma, and the condition abates with fasting.
- *Malabsorptive diarrhea* caused by inadequate nutrient absorption is associated with steatorrhea and is relieved by fasting.
- *Exudative diarrhea* is due to inflammatory disease and characterized by purulent, bloody stools that continue during fasting.

Malabsorption results from disturbance in at least one of the four phases of nutrient absorption: (1) *intraluminal digestion*, in which proteins, carbohydrates, and fats are broken down into absorbable forms; (2) *terminal digestion*, which involves the hydrolysis of carbohydrates and peptides by disaccharidases and peptidases, respectively, in the brush border of the small intestinal mucosa; (3) *transepithelial transport*, in which nutrients, fluid, and electrolytes are transported across and processed within the small intestinal epithelium; and (4) *lymphatic transport* of absorbed lipids.

In many malabsorptive disorders, a defect in one of these processes predominates, but more than one usually contributes (Table 14-3). As a result, malabsorption

syndromes resemble each other more than they differ. Symptoms and signs include *diarrhea* (from nutrient malabsorption and excessive intestinal secretion), *flatus*, *abdominal pain*, and *weight loss*. Inadequate absorption of vitamins and minerals can result in anemia and mucositis due to pyridoxine, folate, or vitamin B<sub>12</sub> deficiency; bleeding due to vitamin K deficiency; osteopenia and tetany due to calcium, magnesium, or vitamin D deficiency; or neuropathy due to vitamin A or B<sub>12</sub> deficiency. A variety of endocrine and skin disturbances also may occur.

### Cystic Fibrosis

Cystic fibrosis is discussed in greater detail elsewhere (Chapter 6). Only the malabsorption associated with cystic fibrosis is considered here. Owing to the absence of the epithelial cystic fibrosis transmembrane conductance regulator (CFTR), persons with cystic fibrosis have defects in intestinal and pancreatic ductal chloride ion secretion. This abnormality leads to interference with bicarbonate, sodium, and water secretion, ultimately resulting in defective luminal hydration. This failure of hydration can result in meconium ileus, which is present in up to 10% of newborns with cystic fibrosis. In the pancreas, intraductal concretions can begin to form in utero. This leads to obstruction, low-grade chronic autodigestion of the pancreas, and eventual *exocrine pancreatic insufficiency in more than 80% of patients*. The result is failure of the intraluminal phase of nutrient absorption, which can be effectively treated in most patients with oral enzyme supplementation.

### Celiac Disease

*Celiac disease*, also known as *celiac sprue* or *gluten-sensitive enteropathy*, is an immune-mediated enteropathy triggered by the ingestion of gluten-containing cereals, such as wheat, rye, or barley, in genetically predisposed persons. In countries whose populations consist predominantly of white people of European ancestry, celiac disease is a common disorder, with an estimated prevalence of 0.5%

**Table 14-3** Defects in Malabsorptive and Diarrheal Disease

Disease	Intraluminal Digestion	Terminal Digestion	Transepithelial Transport	Lymphatic Transport
Celiac disease		+	+	
Tropical sprue		+	+	
Chronic pancreatitis	+			
Cystic fibrosis	+			
Primary bile acid malabsorption	+		+	
Carcinoid syndrome			+	
Autoimmune enteropathy		+	+	
Disaccharidase deficiency		+		
Whipple disease				+
Abetalipoproteinemia			+	
Viral gastroenteritis		+	+	
Bacterial gastroenteritis		+	+	
Parasitic gastroenteritis		+	+	
Inflammatory bowel disease	+	+	+	

+ indicates that the process is abnormal in the disease indicated. Other processes are not affected.

to 1%. The primary treatment for celiac disease is a *gluten-free diet*. Despite the challenges of adhering to such a diet, it does result in symptomatic improvement for most patients.

## PATHOGENESIS

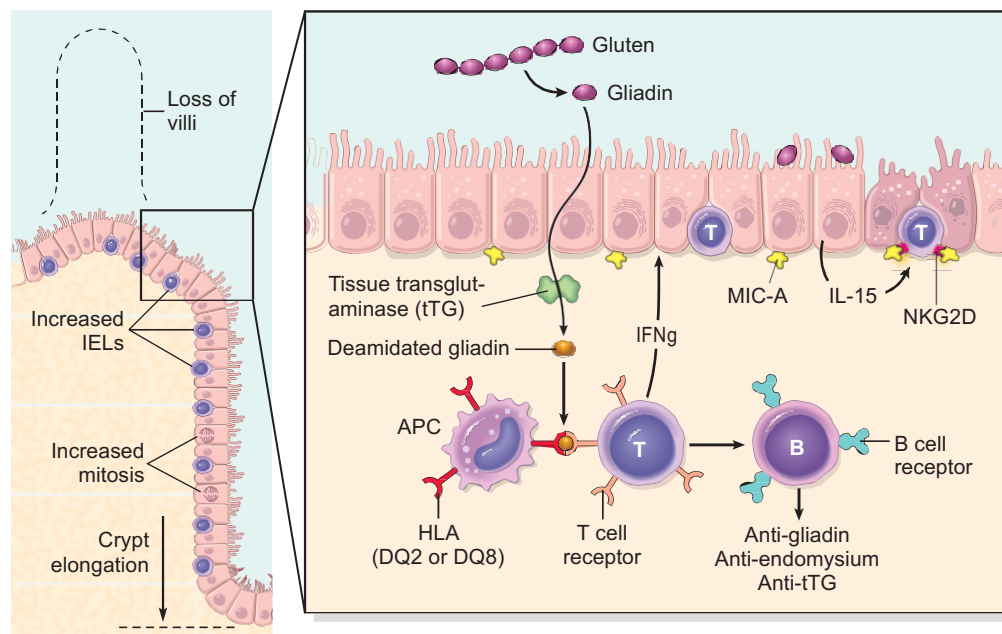
Celiac disease is an intestinal immune reaction to gluten, the major storage protein of wheat and similar grains. Gluten is digested by luminal and brush border enzymes into amino acids and peptides, including a 33–amino acid gliadin peptide that is resistant to degradation by gastric, pancreatic, and small intestinal proteases (Fig. 14–21). Gliadin is deamidated by tissue transglutaminase and is then able to interact with HLA-DQ2 or HLA-DQ8 on antigen-presenting cells and be presented to CD4<sup>+</sup> T cells. These T cells produce cytokines that are likely to contribute to the tissue damage and characteristic mucosal histopathology. A characteristic B cell response follows: this includes production of anti-tissue transglutaminase, anti-deamidated gliadin, and, perhaps as a result of cross-reactive epitopes, anti-endomysial antibodies, which are diagnostically useful (see below). However, whether these antibodies contribute to celiac disease pathogenesis or are merely markers remains controversial. In addition to CD4<sup>+</sup> cells, there is accumulation of CD8<sup>+</sup> cells that are not specific for gliadin. These CD8<sup>+</sup> cells may play an ancillary role in causing tissue damage. It is thought that deamidated gliadin peptides induce epithelial cells to produce the cytokine IL-15, which in turn triggers activation and proliferation of CD8<sup>+</sup> intraepithelial lymphocytes that can express the MIC-A receptor NKG2D. These lymphocytes become cytotoxic and kill enterocytes that have been induced by various stressors to express surface MIC-A, an HLA class I–like protein that is recognized by NKG2D and, possibly, other epithelial proteins. The damage caused by these

immune mechanisms may increase the movement of gliadin peptides across the epithelium, which are deamidated by tissue transglutaminase, thus perpetuating the cycle of disease.

While nearly all people eat grain and are exposed to gluten and gliadin, most do not develop celiac disease. Thus, host factors determine whether disease develops. Among these, HLA proteins seem to be critical, since almost all people with celiac disease carry the class II HLA-DQ2 or HLA-DQ8 alleles. However, the HLA locus accounts for less than half of the genetic component of celiac disease. Other genetic contributors are not fully defined. There is also an association of celiac disease with other immune diseases including type I diabetes, thyroiditis, and Sjögren syndrome.

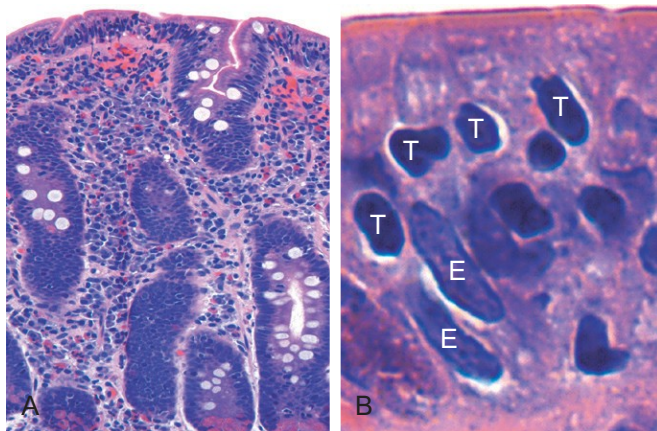
## MORPHOLOGY

Biopsy specimens from the second portion of the duodenum or proximal jejunum, which are exposed to the highest concentrations of dietary gluten, generally are diagnostic in celiac disease. The histopathologic picture is characterized by increased numbers of intraepithelial CD8<sup>+</sup> T lymphocytes, with **intraepithelial lymphocytosis, crypt hyperplasia, and villous atrophy** (Fig. 14–22). This loss of mucosal and brush border surface area probably accounts for the malabsorption. In addition, increased rates of epithelial turnover, reflected in increased crypt mitotic activity, may limit the ability of absorptive enterocytes to fully differentiate and contribute to defects in terminal digestion and transepithelial transport. Other features of fully developed celiac disease include increased numbers of plasma cells, mast cells, and eosinophils, especially within the upper part of the lamina propria. With increased serologic screening and early detection of disease-associated antibodies, it is now appreciated that an increase in the number of intraepithelial lymphocytes,



**Figure 14–21** *Left panel*, The morphologic alterations that may be present in celiac disease, including villous atrophy, increased numbers of intraepithelial lymphocytes (IELs), and epithelial proliferation with crypt elongation. *Right panel*, A model for the pathogenesis of celiac disease. Note that both innate and adaptive immune mechanisms are involved in the tissue responses to gliadin.





**Figure 14-22** Celiac disease. **A**, Advanced cases of celiac disease show complete loss of villi, or total villous atrophy. Note the dense plasma cell infiltrates in the lamina propria. **B**, Infiltration of the surface epithelium by T lymphocytes, which can be recognized by their densely stained nuclei (labeled T). Compare with elongated, pale-staining epithelial nuclei (labeled E).

particularly within the villus, is a marker of mild forms of celiac disease. Intraepithelial lymphocytosis and villous atrophy are not specific for celiac disease, however, and can be a feature of other disorders, including viral enteritis. The combination of histologic and serologic findings is most specific for diagnosis of celiac disease.

### Clinical Features

In adults, celiac disease manifests most commonly between the ages of 30 and 60. However, many cases escape clinical attention for extended periods because of atypical presentations. Some patients have *silent* celiac disease, defined as positive serology and villous atrophy without symptoms, or *latent* celiac disease, in which positive serology is not accompanied by villous atrophy. Symptomatic adult celiac disease is often associated with anemia (due to iron deficiency and, less commonly, B<sub>12</sub> and folate deficiency), diarrhea, bloating, and fatigue.

Pediatric celiac disease, which affects male and female children equally, may manifest with *classic symptoms*, typically between the ages of 6 and 24 months (after introduction of gluten to the diet) with irritability, abdominal distention, anorexia, diarrhea, failure to thrive, weight loss, or muscle wasting. Children with *nonclassic symptoms* tend to present at older ages with complaints of abdominal pain, nausea, vomiting, bloating, or constipation. A characteristic pruritic, blistering skin lesion, *dermatitis herpetiformis*, also is present in as many as 10% of patients, and the incidence of *lymphocytic gastritis* and *lymphocytic colitis* also is increased.

Noninvasive serologic tests generally are performed before biopsy. The most sensitive tests are the presence of IgA antibodies to tissue transglutaminase or IgA or IgG antibodies to deamidated gliadin. Antiendomysial antibodies are highly specific but less sensitive than other antibodies. The absence of HLA-DQ2 or HLA-DQ8 is useful for its high negative predictive value, but the presence of these common alleles is not helpful in confirming the diagnosis.

Patients with celiac disease exhibit a higher than normal rate of malignancy. The most common celiac disease-associated cancer is *enteropathy-associated T cell lymphoma*, an aggressive tumor of intraepithelial T lymphocytes. *Small intestinal adenocarcinoma* also is more frequent in persons with celiac disease. Thus, when symptoms such as abdominal pain, diarrhea, and weight loss develop despite a strict gluten-free diet, cancer or *refractory sprue*, in which the response to a gluten-free diet is lost, must be considered. It is, however, important to recognize that failure to adhere to a gluten-free diet is the most common cause of recurrent symptoms, and that most people with celiac disease do well with dietary restrictions and die of unrelated causes.

### Environmental (Tropical) Enteropathy

The term *environmental enteropathy* refers to a syndrome of stunted growth and impaired intestinal function that is common in developing countries, including many parts of sub-Saharan Africa, such as Gambia; aboriginal populations within northern Australia; and some groups within South America and Asia, such as residents of impoverished communities within Brazil, Guatemala, India, and Pakistan. The impact of environmental enteropathy, which was previously called *tropical enteropathy* or *tropical sprue*, cannot be overstated, as it is estimated to affect over 150 million children worldwide. Although malnutrition must contribute to the pathogenesis of this disorder, also referred to as *tropical enteropathy*, neither supplementary feeding nor vitamin and mineral supplementation are able to fully reverse the syndrome. Repeated bouts of diarrhea suffered within the first 2 or 3 years of life are most closely linked to environmental enteropathy. Many pathogens are endemic in these communities, but no single infectious agent has been linked to these diarrheal episodes. Intestinal biopsy specimens have been examined in only a small number of cases, and reported histologic features are more similar to those of severe celiac disease than to those of infectious enteritis. One hypothesis is that recurrent diarrhea establishes a cycle of mucosal injury, malnutrition, infection, and inflammation. However, this has not been established in part because accepted diagnostic criteria for environmental enteropathy are lacking, as the entity has been defined primarily by epidemiologic assessment of physical and cognitive growth and development.

### Lactase (Disaccharidase) Deficiency

The disaccharidases, including lactase, are located in the apical brush border membrane of the villous absorptive epithelial cells. Because the defect is biochemical, biopsies are generally unremarkable. Lactase deficiency is of two types:

- *Congenital lactase deficiency* is an autosomal recessive disorder caused by a mutation in the gene encoding lactase. The disease is rare and manifests as explosive diarrhea with watery, frothy stools and abdominal distention after milk ingestion. Symptoms abate when exposure to milk and milk products is terminated, thus removing the osmotically active but unabsorbable lactose from the lumen.
- *Acquired lactase deficiency* is caused by downregulation of lactase gene expression and is particularly common among Native Americans, African Americans, and

Chinese populations. Downregulation of lactase occurs in the gut after childhood, perhaps reflecting the fact that, before farming of dairy animals, lactase was unnecessary after children stopped drinking mother's milk. Onset of acquired lactase deficiency is sometimes associated with enteric viral or bacterial infections.

### Abetalipoproteinemia

*Abetalipoproteinemia* is an autosomal recessive disease characterized by an inability to secrete triglyceride-rich lipoproteins. Although it is rare, it is included here as an example of a transepithelial transport defect that leads to malabsorption. Mutation in the *microsomal triglyceride transfer protein* renders enterocytes unable to export lipoproteins and free fatty acids. As a result, monoglycerides and triglycerides accumulate within the epithelial cells. Lipid vacuoles in small intestinal epithelial cells are evident by light microscopy and can be highlighted by special stains, such as oil red O, particularly after a fatty meal. *Abetalipoproteinemia* manifests in infancy, and the clinical picture is dominated by failure to thrive, diarrhea, and steatorrhea. Failure to absorb essential fatty acids leads to deficiencies of fat-soluble vitamins, and lipid defects in plasma membranes often produce acanthocytic red cells (spur cells) in peripheral blood smears.

### Irritable Bowel Syndrome

*Irritable bowel syndrome* (IBS) is characterized by chronic and relapsing abdominal pain, bloating, and changes in bowel habits including diarrhea and constipation. The pathogenesis is poorly defined but involves psychologic stressors, diet, and abnormal gastrointestinal motility. Despite very real symptoms, no gross or microscopic abnormalities are found in most IBS patients. Thus, the diagnosis depends on clinical symptoms. IBS typically manifests between 20 and 40 years of age, and there is a significant female predominance. Variability in diagnostic criteria makes it difficult to establish the incidence, but reported prevalence rates in developed countries typically are between 5% and 10%. In patients with diarrhea, microscopic colitis, celiac disease, giardiasis, lactose intolerance, small bowel bacterial overgrowth, bile salt malabsorption, colon cancer, and inflammatory bowel disease must be excluded (although IBS is common in patients with inflammatory bowel disease). The prognosis for IBS is most closely related to symptom duration, with longer duration correlating with reduced likelihood of improvement.

### Microscopic Colitis

*Microscopic colitis* encompasses two entities, *collagenous colitis* and *lymphocytic colitis*. Both of these idiopathic diseases manifest with chronic, nonbloody, watery diarrhea without weight loss. Findings on radiologic and endoscopic studies typically are normal. Collagenous colitis, which occurs primarily in middle-aged and older women, is characterized by the presence of a dense subepithelial collagen layer, increased numbers of intraepithelial lymphocytes, and a mixed inflammatory infiltrate within the lamina propria. Lymphocytic colitis is histologically similar, but the subepithelial collagen layer is of normal thickness and the increase in intraepithelial lymphocytes may be greater, frequently exceeding one T lymphocyte

per five colonocytes. Lymphocytic colitis is associated with celiac and autoimmune diseases, including thyroiditis, arthritis, and autoimmune or lymphocytic gastritis.

### Graft-Versus-Host Disease

Graft-versus-host disease occurs after allogeneic hematopoietic stem cell transplantation. The small bowel and colon are involved in most cases. Although graft-versus-host disease is secondary to the targeting of antigens on the recipient's epithelial cells by donor T cells, the lymphocytic infiltrate in the lamina propria is typically sparse. Epithelial apoptosis, particularly of crypt cells, is the most common histologic finding. Intestinal graft-versus-host disease often manifests as a watery diarrhea.

## SUMMARY

### Malabsorptive Diarrhea

- Diarrhea can be characterized as *secretory, osmotic, malabsorptive, or exudative*.
- The malabsorption associated with cystic fibrosis is the result of *pancreatic insufficiency* (i.e., inadequate pancreatic digestive enzymes) and *deficient luminal breakdown* of nutrients.
- *Celiac disease* is an immune-mediated enteropathy triggered by the ingestion of gluten-containing grains. The malabsorptive diarrhea in celiac disease is due to *loss of brush border surface area* and, possibly, deficient enterocyte maturation as a result of immune-mediated epithelial damage.
- *Lactase deficiency* causes an *osmotic diarrhea* owing to the inability to break down or absorb lactose.
- *Irritable bowel syndrome* (IBS) is characterized by chronic, relapsing abdominal pain, bloating, and changes in bowel habits. The pathogenesis is poorly defined.
- The two forms of microscopic colitis, *collagenous colitis* and *lymphocytic colitis*, both cause chronic watery diarrhea. The intestines are grossly normal, and the diseases are identified by their characteristic histologic features.

### Infectious Enterocolitis

Enterocolitis can manifest with a broad range of signs and symptoms including diarrhea, abdominal pain, urgency, perianal discomfort, incontinence, and hemorrhage. This global problem is responsible for more than 12,000 deaths per day among children in developing countries and half of all deaths before age 5 worldwide. Bacterial infections, such as enterotoxigenic *Escherichia coli*, frequently are responsible, but the most common pathogens vary with age, nutrition, and host immune status, as well as environmental influences (Table 14-4). For example, epidemics of cholera are common in areas with poor sanitation, as a result of inadequate public health measures, or as a consequence of natural disasters (e.g., the Haiti earthquake of 2010) or war. Pediatric infectious diarrhea, which may result in severe dehydration and metabolic acidosis, commonly is caused by enteric viruses. A summary of the epidemiology and clinical features of selected causes of bacterial enterocolitis is presented in



**Table 14–4** Features of Bacterial Enterocolitides

Infection Type	Geography	Reservoir	Transmission	Epidemiology	Affected GI Sites	Symptoms	Complications
Cholera	India, Africa	Shellfish	Fecal-oral, water	Sporadic, endemic, epidemic	Small intestine	Severe watery diarrhea	Dehydration, electrolyte imbalances
<i>Campylobacter</i> spp.	Developed countries	Chickens, sheep, pigs, cattle	Poultry, milk, other foods	Sporadic; children, travelers	Colon	Watery or bloody diarrhea	Arthritis, Guillain-Barré syndrome
Shigellosis	Developing countries	Humans	Fecal-oral, food, water	Children	Left colon, ileum	Bloody diarrhea	Reactive arthritis hemolytic-uremic syndrome
Salmonellosis	Worldwide	Poultry, farm animals, reptiles	Meat, poultry, eggs, milk	Children, elderly	Colon and small intestine	Watery or bloody diarrhea	Sepsis
Enteric (typhoid) fever	India, Mexico, Philippines	Humans	Fecal-oral, water	Children, adolescents, travelers	Small intestine	Bloody diarrhea, fever	Chronic infection, carrier state, encephalopathy, myocarditis
<i>Yersinia</i> spp.	Northern and central Europe	Pigs	Pork, milk, water	Clustered cases	Ileum, appendix, right colon	Abdominal pain, fever, diarrhea	Autoimmune, e.g., reactive arthritis
<i>Escherichia coli</i> Enterotoxigenic (ETEC)	Developing countries	Unknown	Food, fecal-oral	Infants, adolescents, travelers	Small intestine	Severe watery diarrhea	Dehydration, electrolyte imbalances
Enterohemorrhagic (EHEC)	Worldwide	Widespread, includes cattle	Beef, milk, produce	Sporadic and epidemic	Colon	Bloody diarrhea	Hemolytic-uremic syndrome
Enteroinvasive (EIEC)	Developing countries	Unknown	Cheese, other foods, water	Young children	Colon	Bloody diarrhea	Unknown
Enteraggregative (EAEC)	Worldwide	Unknown	Unknown	Children, adults, travelers	Colon	Nonbloody diarrhea, afebrile	Poorly defined
Pseudomembranous colitis ( <i>C. difficile</i> )	Worldwide	Humans, hospitals	Antibiotics allow emergence	Immunosuppressed, antibiotic-treated	Colon	Watery diarrhea, fever	Relapse, toxic megacolon
Whipple disease	Rural > urban	Unknown	Unknown	Rare	Small intestine	Malabsorption	Arthritis, CNS disease
Mycobacterial infection	Worldwide	Unknown	Unknown	Immunosuppressed	Small intestine	Malabsorption, diarrhea, fever	Pneumonia, infection at other sites

CNS, central nervous system; GI, gastrointestinal.

**Table 14–4.** Representative bacterial, viral, and parasitic enterocolitides are discussed below.

### Cholera

*Vibrio cholerae* organisms are comma-shaped, gram-negative bacteria that cause cholera, a disease that has been endemic in the Ganges Valley of India and Bangladesh for all of recorded history. *V. cholerae* is transmitted primarily by contaminated drinking water. However, it also can be present in food and causes rare cases of seafood-associated disease. There is a marked seasonal variation in most climates due to rapid growth of *Vibrio* bacteria at warm temperatures; the only animal reservoirs are shellfish and plankton. Relatively few *V. cholerae* serotypes are pathogenic, but other species of *Vibrio* also can cause disease.

### PATHOGENESIS

Despite the severe diarrhea, *Vibrio* organisms are noninvasive and remain within the intestinal lumen. Flagellar proteins, which are involved in motility and attachment, are necessary for efficient bacterial colonization, and a secreted metalloproteinase that also has hemagglutinin activity is important for bacterial detachment and shedding in the stool. However, it is the **preformed enterotoxin**, cholera toxin, which causes disease. The toxin, which is composed of five B subunits that direct endocytosis and a single active A subunit, is delivered to the endoplasmic reticulum by **retrograde transport**. A fragment of the A subunit is transported from the endoplasmic reticulum lumen into the cytosol, where it interacts with cytosolic ADP ribosylation factors to ribosylate and activate the G protein  $G_{sa}$ . This stimulates adenylate cyclase and the resulting increases in intracellular cyclic adenosine monophosphate (cAMP) open the cystic fibrosis transmembrane conductance regulator (CFTR), which releases chloride ions into the lumen. Sodium and bicarbonate absorption are also reduced. Accumulation of these ions creates an osmotic gradient that draws water into the lumen, leading to massive **secretory diarrhea**. Remarkably, mucosal biopsy specimens show only minimal morphologic alterations.

### Clinical Features

Most exposed persons are asymptomatic or suffer only mild diarrhea. Those with severe disease have an abrupt onset of watery diarrhea and vomiting after an incubation period of 1 to 5 days. The rate of diarrheal stool production may reach 1 L per hour, leading to dehydration, hypotension, electrolyte imbalances, muscular cramping, anuria, shock, loss of consciousness, and death. Most deaths occur within the first 24 hours after presentation. Although the mortality rate for severe cholera is 50% to 70% without treatment, fluid replacement can save more than 99% of patients.

### Campylobacter Enterocolitis

*Campylobacter jejuni* is the most common bacterial enteric pathogen in developed countries and is an important cause of traveler's diarrhea. Most infections are associated with ingestion of improperly cooked chicken, but outbreaks also can be caused by unpasteurized milk or contaminated water.

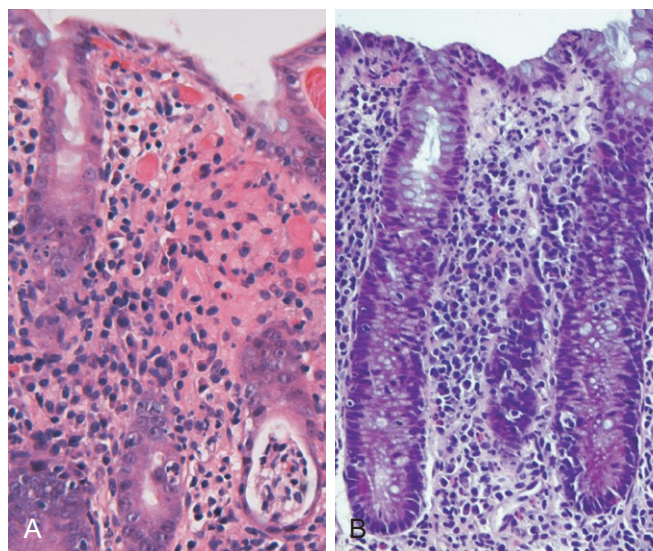
### PATHOGENESIS

The pathogenesis of *Campylobacter* infection remains poorly defined, but four major virulence properties contribute: motility, adherence, toxin production, and invasion. Flagella allow *Campylobacter* to be motile. This facilitates adherence and colonization, which are also necessary for mucosal invasion. Cytotoxins that cause epithelial damage and a cholera toxin–like enterotoxin are also released by some *C. jejuni* isolates. **Dysentery** generally is associated with invasion and only occurs with a small minority of *Campylobacter* strains. **Enteric fever** occurs when bacteria proliferate within the lamina propria and mesenteric lymph nodes.

*Campylobacter* infection can result in reactive arthritis, primarily in patients with HLA-B27. Other extraintestinal complications, including erythema nodosum and Guillain-Barré syndrome, a flaccid paralysis caused by autoimmune-induced inflammation of peripheral nerves, are not HLA-linked. Fortunately, Guillain-Barré syndrome develops in 0.1% or less of persons infected with *Campylobacter*.

### MORPHOLOGY

*Campylobacter*, *Shigella*, *Salmonella*, and many other bacterial infections, including *Yersinia* and *E. coli*, all induce a similar histopathology, termed **acute self-limited colitis**, and these pathogens cannot be reliably distinguished by tissue biopsy. Thus, specific diagnosis is primarily by stool culture. The histology of acute self-limited colitis includes prominent lamina propria and intraepithelial neutrophil infiltrates (Fig. 14–23, A); **cryptitis** (neutrophil infiltration of the crypts) and **crypt abscesses** (crypts with accumulations of luminal neutrophils) also may be present. The preservation of crypt architecture in most cases of acute self-limited colitis is helpful in distinguishing these infections from inflammatory bowel disease (Fig. 14–23, B).



**Figure 14–23** Bacterial enterocolitis. **A**, *Campylobacter jejuni* infection produces acute, self-limited colitis. Neutrophils can be seen within surface and crypt epithelium and a crypt abscess is present at the lower right. **B**, Enteroinvasive *Escherichia coli* infection is similar to other acute, self-limited colitides. Note the maintenance of normal crypt architecture and spacing, despite abundant intraepithelial neutrophils.



### Clinical Features

Ingestion of as few as 500 *C. jejuni* organisms can cause disease after an incubation period of up to 8 days. Watery diarrhea, either acute or with onset after an influenza-like prodrome, is the primary manifestation, and dysentery develops in 15% to 50% of patients. Patients may shed bacteria for 1 month or more after clinical resolution. The disease is self limited and therefore antibiotic therapy generally is not required. Diagnosis is primarily by stool culture since the histologic changes are not specific for *Campylobacter colitis*.

### Shigellosis

*Shigella* organisms are gram-negative bacilli that are unencapsulated, nonmotile, facultative anaerobes. Although humans are the only known reservoir, *Shigella* remains one of the most common causes of bloody diarrhea. It is estimated that 165 million cases occur worldwide each year. Shigellae are highly transmissible by the fecal-oral route or through ingestion of contaminated water and food; the infective dose is fewer than 100 organisms and each gram of stool contains as many as  $10^9$  organisms during acute phases of the disease.

In the United States and Europe, children in day care centers, migrant workers, travelers to developing countries, and residents of nursing homes are most commonly affected. Most *Shigella*-associated infections and deaths occur in children younger than 5 years of age; in countries in which *Shigella* is endemic, it is responsible for approximately 10% of all cases of pediatric diarrheal disease and as many as 75% of diarrheal deaths.

## PATHOGENESIS

*Shigella* organisms are resistant to the harsh acidic environment of the stomach, which partially explains the very low infective dose. Once in the intestine, organisms are taken up by M (microfold) epithelial cells, which are specialized for sampling and uptake of luminal antigens. After intracellular proliferation, the bacteria escape into the lamina propria. These bacteria then infect small intestinal and colonic epithelial cells through the basolateral membranes, which express bacterial receptors. Alternatively, luminal shigellae can directly modulate epithelial tight junctions to expose basolateral bacterial receptors. The latter is partly mediated by virulence proteins, some of which are directly injected into the host cytoplasm by a type III secretion system. Some *Shigella dysenteriae* serotypes also release the Shiga toxin Stx, which inhibits eukaryotic protein synthesis and causes host cell death.

## MORPHOLOGY

*Shigella* infections are most prominent in the left colon, but the ileum may also be involved, perhaps reflecting the abundance of M cells in the epithelium overlying the Peyer's patches. The histologic appearance in early cases is similar to that in other acute self-limited colitides. In more severe cases, the mucosa is hemorrhagic and ulcerated, and

pseudomembranes may be present. Perhaps because of the tropism for M cells, aphthous-appearing ulcers similar to those seen in Crohn disease also may occur. The potential for confusion with chronic inflammatory bowel disease is substantial, particularly if there is distortion of crypt architecture. Confirmation of *Shigella* infection requires stool culture.

### Clinical Features

After an incubation period of 1 to 7 days, *Shigella* causes self-limited disease characterized by about 6 days of diarrhea, fever, and abdominal pain. The initially watery diarrhea progresses to a dysenteric phase in approximately 50% of patients, and constitutional symptoms can persist for as long as 1 month. A subacute presentation also can develop in a minority of adults. Antibiotic treatment shortens the clinical course and reduces the duration over which organisms are shed in the stool, but antidiarrheal medications are contraindicated because they can prolong symptoms by delaying bacterial clearance.

Complications of *Shigella* infection are uncommon and include reactive arthritis, a triad of sterile arthritis, urethritis, and conjunctivitis that preferentially affects HLA-B27-positive men between 20 and 40 years of age. Hemolytic uremic syndrome, which typically is associated with enterohemorrhagic *Escherichia coli* (EHEC), also may occur after infection with shigellae that secrete Shiga toxin.

### Escherichia coli

*Escherichia coli* are gram-negative bacilli that colonize the healthy GI tract; most are nonpathogenic, but a subset cause human disease. The latter are classified according to morphology, mechanism of pathogenesis, and in vitro behavior (Table 14-4). Here we summarize their pathogenic mechanisms:

- **Enterotoxigenic *E. coli* (ETEC) organisms** are the principal cause of traveler's diarrhea, and are spread by the fecal-oral route. They express a heat labile toxin (LT) that is similar to cholera toxin and a heat-stable toxin (ST) that increases intracellular cGMP with effects similar to the cAMP elevations caused by LT.
- **Enterohemorrhagic *E. coli* (EHEC) organisms** are categorized as O157:H7 and non-O157:H7 serotypes. Outbreaks of *E. coli* O157:H7 in developed countries have been associated with the consumption of inadequately cooked ground beef, milk, and vegetables. Both O157:H7 and non-O157:H7 serotypes produce Shiga-like toxins and can cause dysentery. They can also give rise to hemolytic-uremic syndrome (Chapter 13).
- **Enteroinvasive *E. coli* (EIEC) organisms** resemble *Shigella* bacteriologically but do not produce toxins. They invade the gut epithelial cells and produce a bloody diarrhea.
- **Enteroaggregative *E. coli* (EAEC) organisms** attach to enterocytes by adherence fimbriae. Although they produce LT and Shiga-like toxins, histologic damage is minimal.

### Salmonellosis

*Salmonella* species, which are members of the Enterobacteriaceae family of gram-negative bacilli, are divided into

*Salmonella typhi*, the causative agent of typhoid fever (discussed in the next section) and nontyphoid *Salmonella* strains that cause gastroenteritis. Nontyphoid *Salmonella* infection usually is due to *Salmonella enteritidis*; more than 1 million cases occur each year in the United States, which result in 2000 deaths; the prevalence is even greater in many other countries. Infection is most common in young children and elderly persons, with peak incidence in summer and fall. Transmission usually is through contaminated food, particularly raw or undercooked meat, poultry, eggs, and milk.

## PATHOGENESIS

Very few viable *Salmonella* organisms are necessary to cause infection, and the absence of gastric acid, as in persons with atrophic gastritis or those on acid-suppressive therapy, further reduces the required inoculum. Salmonellae possess **virulence genes that encode a type III secretion system** capable of transferring bacterial proteins into M cells and enterocytes. The transferred proteins activate host cell Rho GTPases, thereby triggering actin rearrangement and bacterial uptake into phagosomes where the bacteria can grow. Salmonellae also secrete a molecule that induces epithelial release of a chemoattractant eicosanoid that draws neutrophils into the lumen and potentiates mucosal damage. Stool cultures are essential for diagnosis.

## Typhoid Fever

Typhoid fever, also referred to as enteric fever, is caused by *Salmonella typhi* and *Salmonella paratyphi*. It affects up to 30 million individuals worldwide each year. Infection by *S. typhi* is more common in endemic areas, where children and adolescents are most often affected. By contrast, *S. paratyphi* predominates in travelers and those living in developed countries. Humans are the sole reservoir for *S. typhi* and *S. paratyphi* and transmission occurs from person to person or via contaminated food or water. Gallbladder colonization may be associated with gallstones and a chronic carrier state. Acute infection is associated with anorexia, abdominal pain, bloating, nausea, vomiting, and bloody diarrhea followed by a short asymptomatic phase that gives way to bacteremia and fever with flu-like symptoms. It is during this phase that detection of organisms by blood culture may prompt antibiotic treatment and prevent further disease progression. Without such treatment, the febrile phase is followed by up to 2 weeks of sustained high fevers with abdominal tenderness that may mimic appendicitis. *Rose spots*, small erythematous maculopapular lesions, are seen on the chest and abdomen. Systemic dissemination may cause *extraintestinal complications* including encephalopathy, meningitis, seizures, endocarditis, myocarditis, pneumonia, and cholecystitis. Patients with sickle cell disease are particularly susceptible to *Salmonella* osteomyelitis.

Like *S. enteritidis*, *S. typhi* and *S. paratyphi* are taken up by M cells and then engulfed by mononuclear cells in the underlying lymphoid tissue. Thus, infection causes Peyer's patches in the terminal ileum to enlarge into plateau-like elevations up to 8 cm in diameter. Mucosal shedding

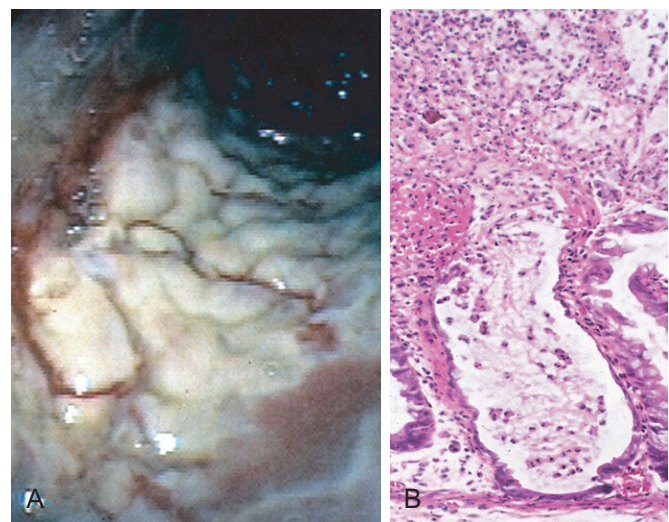
creates oval ulcers oriented along the long axis of the ileum. However, unlike *S. enteritidis*, *S. typhi* and *S. paratyphi* can disseminate via lymphatic and blood vessels. This causes reactive hyperplasia of draining lymph nodes, in which bacteria-containing phagocytes accumulate. In addition, the spleen is enlarged and soft with pale red pulp, obliterated follicular markings, and prominent phagocyte hyperplasia. Randomly scattered small foci of parenchymal necrosis with macrophage aggregates, termed *typhoid nodules*, are also present in the liver, bone marrow, and lymph nodes.

## Pseudomembranous Colitis

Pseudomembranous colitis, generally caused by *Clostridium difficile*, is also known as antibiotic-associated colitis or antibiotic-associated diarrhea. The latter terms apply to diarrhea developing during or after a course of antibiotic therapy and may be due to *C. difficile* as well as *Salmonella*, *C. perfringens* type A, or *S. aureus*. However, the latter two organisms produce enterotoxins and are common agents of food poisoning. They do not cause pseudomembranes. Disruption of the normal colonic microbiota by antibiotics allows *C. difficile* overgrowth. Toxins released by *C. difficile* cause the ribosylation of small GTPases, such as Rho, and lead to disruption of the epithelial cytoskeleton, tight junction barrier loss, cytokine release, and apoptosis.

## MORPHOLOGY

Fully developed *C. difficile*-associated colitis is accompanied by formation of **pseudomembranes** (Fig. 14–24, A), made up of an adherent layer of inflammatory cells and debris at sites of colonic mucosal injury. The surface epithelium is denuded, and the superficial lamina propria contains a dense infiltrate of neutrophils and occasional fibrin thrombi within capillaries. Damaged crypts are distended by a mucopurulent exudate that “erupts” to the surface in a fashion reminiscent of a volcano (Fig. 14–24, B).



**Figure 14–24** *Clostridium difficile* colitis. **A**, The colon is coated by tan pseudomembranes composed of neutrophils, dead epithelial cells, and inflammatory debris (endoscopic view). **B**, Typical pattern of neutrophils emanating from a crypt is reminiscent of a volcanic eruption.



### Clinical Features

In addition to antibiotic exposure, risk factors for *C. difficile*-associated colitis include advanced age, hospitalization, and immunosuppression. The organism is particularly prevalent in hospitals; as many as 20% of hospitalized adults are colonized with *C. difficile* (a rate 10 times higher than in the general population), but most colonized patients are free of disease. Persons with *C. difficile*-associated colitis present with fever, leukocytosis, abdominal pain, cramps, hypoalbuminemia, watery diarrhea, and dehydration. Fecal leukocytes and occult blood may be present, but grossly bloody diarrhea is rare. Diagnosis of *C. difficile*-associated colitis usually is accomplished by detection of *C. difficile* toxin, rather than culture, and is supported by the characteristic histopathologic findings. Regimens of metronidazole or vancomycin are generally effective treatments, but antibiotic-resistant and hypervirulent *C. difficile* strains are increasingly common, and the infection may recur in at-risk patients.

### Norovirus

Norovirus, previously known as Norwalk-like virus, is a common agent of nonbacterial infectious gastroenteritis. Norovirus causes approximately half of all gastroenteritis outbreaks worldwide and is a common cause of sporadic gastroenteritis in developed countries. Local outbreaks usually are related to contaminated food or water, but person-to-person transmission underlies most sporadic cases. Infections spread easily within schools, hospitals, and nursing homes and, most recently, on cruise ships. After a short incubation period, affected persons develop nausea, vomiting, watery diarrhea, and abdominal pain. Biopsy morphology is nonspecific. The disease is self-limited.

### Rotavirus

The encapsulated rotavirus infects 140 million people and causes 1 million deaths each year, making rotavirus *the most common cause of severe childhood diarrhea and diarrhea-related deaths worldwide*. Children between 6 and 24 months of age are most vulnerable. Protection in the first 6 months of life is probably due to the presence of antibodies to rotavirus in breast milk, while protection beyond 2 years is due to immunity that develops after the first infection. Outbreaks in hospitals and day care centers are common, and infection spreads easily; the estimated minimal infective inoculum is only 10 viral particles. *Rotavirus selectively infects and destroys mature (absorptive) enterocytes in the small intestine, and the villus surface is repopulated by immature secretory cells*. This change in functional capacity results in loss of absorptive function and net secretion of water and electrolytes that is compounded by an osmotic diarrhea from incompletely absorbed nutrients. Like norovirus, rotavirus produces clinically apparent infection after a short incubation period, manifested by vomiting and watery diarrhea for several days. Vaccines are now available, and their use is beginning to change the epidemiology of rotavirus infection. For unknown reasons, oral rotavirus vaccines have been less effective in developing countries where they are most needed.

### Parasitic Disease

Although viruses and bacteria are the predominant enteric pathogens in the United States, parasitic disease and protozoal infections affect over half of the world's population on a chronic or recurrent basis. The small intestine can harbor as many as 20 species of parasites, including nematodes, such as the roundworms *Ascaris* and *Strongyloides*; hookworms and pinworms; cestodes, including flatworms and tapeworms; trematodes, or flukes; and protozoa.

- *Ascaris lumbricoides*. This nematode infects more than 1 billion people worldwide as a result of human fecal-oral contamination. Ingested eggs hatch in the intestine and larvae penetrate the intestinal mucosa. From here the larvae migrate via the splanchnic circulation to the liver, creating hepatic abscesses, and then through the systemic circulation to the lung, where they can cause *Ascaris* pneumonitis. In the latter case, larvae migrate up the trachea, are swallowed, and arrive again in the intestine to mature into adult worms.
- *Strongyloides*. The larvae of *Strongyloides* live in fecally contaminated ground soil and can penetrate unbroken skin. They migrate through the lungs to the trachea from where they are swallowed and then mature into adult worms in the intestines. Unlike other intestinal worms, which require an ovum or larval stage outside the human, the eggs of *Strongyloides* can hatch within the intestine and release larvae that penetrate the mucosa, creating a vicious cycle referred to as autoinfection. Hence, *Strongyloides* infection can persist for life, and immunosuppressed individuals can develop overwhelming infections.
- *Necator americanus* and *Ancylostoma duodenale*. These hookworms infect 1 billion people worldwide and cause significant morbidity. Infection is initiated by larval penetration through the skin. After further development in the lungs, the larvae migrate up the trachea and are swallowed. Once in the duodenum, the larvae mature and the adult worms attach to the mucosa, suck blood, and reproduce. Hookworms are the leading cause of iron deficiency anemia in the developing world.
- *Giardia lamblia*. This flagellated protozoan, also referred to as *Giardia duodenalis* or *Giardia intestinalis*, is responsible for the *most common pathogenic parasitic infection in humans* and is spread by fecally contaminated water or food. Infection may occur after ingestion of as few as 10 cysts. Because cysts are resistant to chlorine, *Giardia* organisms are endemic in unfiltered public and rural water supplies. In the acid environment of the stomach excystation occurs and trophozoites are released. Secretory IgA and mucosal IL-6 responses are important for clearance of *Giardia* infections, and immunosuppressed, agammaglobulinemic, or malnourished persons often are severely affected. *Giardia* evade immune clearance through continuous modification of the major surface antigen, variant surface protein, and can persist for months or years while causing intermittent symptoms. *Giardia* infection decreases the expression of brush border enzymes, including lactase, and causes microvillous damage and apoptosis of small intestinal epithelial cells. *Giardia* trophozoites are noninvasive and can be identified in duodenal biopsy specimens by their

characteristic pear shape. Giardiasis is clinically characterized by acute or chronic diarrhea and can result in malabsorption.

## SUMMARY

### Infectious Enterocolitis

- *Vibrio cholerae* secretes a pre-formed toxin that causes massive chloride secretion. Water follows the resulting osmotic gradient, leading to *secretory diarrhea*.
- *Campylobacter jejuni* is the most common bacterial enteric pathogen in developed countries and also causes traveler's diarrhea. Most isolates are noninvasive. *Salmonella* and *Shigella* spp. are invasive and associated with exudative bloody diarrhea (dysentery). *Salmonella* infection is a common cause of food poisoning. *S. typhi* can cause systemic disease (typhoid fever).
- Pseudomembranous colitis is often triggered by antibiotic therapy that disrupts the normal microbiota and allows *C. difficile* to colonize and grow. The organism releases toxins that disrupt epithelial function. The associated inflammatory response includes characteristic volcano-like eruptions of neutrophils from colonic crypts that spread to form mucopurulent pseudomembranes.
- Rotavirus is the most common cause of severe childhood diarrhea and diarrheal mortality worldwide. The diarrhea is secondary to loss of mature enterocytes, resulting in malabsorption as well as secretion.
- Parasitic and protozoal infections affect over half of the world's population on a chronic or recurrent basis.

## INFLAMMATORY INTESTINAL DISEASE

### Sigmoid Diverticulitis

In general, diverticular disease refers to acquired pseudo-diverticular outpouchings of the colonic mucosa and submucosa. Such *colonic diverticula* are rare in persons younger than 30 years of age, but the prevalence approaches 50% in Western adult populations beyond the age of 60. Diverticula generally are multiple, and the condition is referred to as *diverticulosis*. This disease is much less common in Japan and nonindustrialized countries, probably because of dietary differences.

## PATHOGENESIS

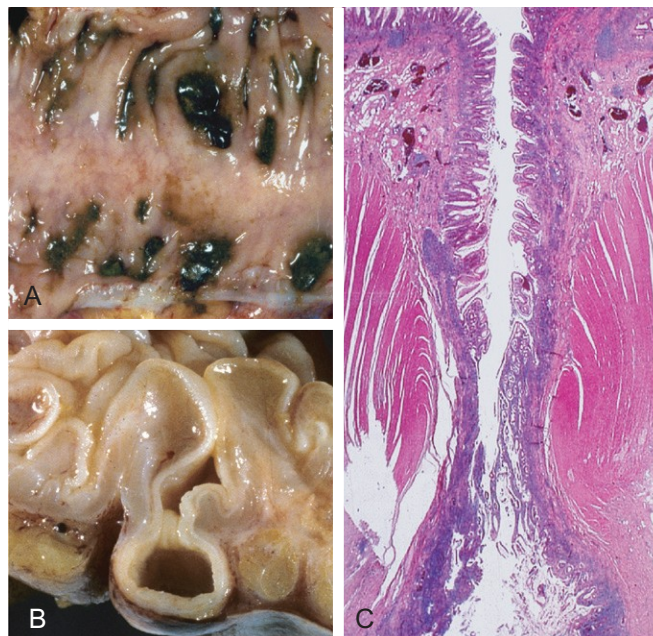
Colonic diverticula tend to develop under conditions of elevated intraluminal pressure in the sigmoid colon. This is facilitated by the unique structure of the colonic muscularis propria, where nerves, arterial vasa recta, and their connective tissue sheaths penetrate the inner circular muscle coat to create discontinuities in the muscle wall. In other parts of the intestine, these gaps are reinforced by the external longitudinal layer of the muscularis propria, but in the colon, this muscle layer is discontinuous, being gathered into the three bands termed **taeniae coli**. High luminal pressures may be generated by exaggerated peristaltic contractions, with spasmodic sequestration of bowel segments that may be exacerbated by diets low in fiber, which reduce stool bulk.

## MORPHOLOGY

Anatomically, colonic diverticula are small, flask-like outpouchings, usually 0.5 to 1 cm in diameter, that occur in a regular distribution in between the taeniae coli (Fig. 14-25, A). They are most common in the sigmoid colon, but other regions of the colon may be affected in severe cases. Because diverticula are compressible, easily emptied of fecal contents, and often surrounded by the fat-containing **epiolic appendices** on the surface of the colon, they may be missed on casual inspection. Colonic diverticula have a thin wall composed of a flattened or atrophic mucosa, compressed submucosa, and attenuated muscularis propria—often, this last component is totally absent (Fig. 14-30, B and C). Hypertrophy of the circular layer of the muscularis propria in the affected bowel segment is common. Obstruction of diverticula leads to inflammatory changes, producing **diverticulitis** and peridiverticulitis. Because the wall of the diverticulum is supported only by the muscularis mucosa and a thin layer of subserosal adipose tissue, inflammation and increased pressure within an obstructed diverticulum can lead to **perforation**. With or without perforation, recurrent diverticulitis may cause segmental colitis, fibrotic thickening in and around the colonic wall, or stricture formation. Perforation can lead to formation of pericolonic abscesses, development of sinus tracts, and, occasionally, peritonitis.

### Clinical Features

Most persons with diverticular disease remain asymptomatic throughout their lives. About 20% of those affected develop complaints including intermittent cramping, continuous lower abdominal discomfort, constipation, and



**Figure 14-25** Sigmoid diverticular disease. **A**, Stool-filled diverticula are regularly arranged. **B**, Cross-section showing the outpouching of mucosa beneath the muscularis propria. **C**, Low-power photomicrograph of a sigmoid diverticulum showing protrusion of the mucosa and submucosa through the muscularis propria.



diarrhea. Longitudinal studies have shown that while diverticula can regress early in their development they often become more numerous and larger over time. Whether a high-fiber diet prevents such progression or protects against diverticulitis is unclear. Even when diverticulitis occurs, it most often resolves spontaneously or after antibiotic treatment, and relatively few patients require surgical intervention.

**SUMMARY**

**Sigmoid Diverticulitis**

- *Diverticular disease* of the sigmoid colon is common in Western populations over the age of 60. Contributing etiologic factors include low-fiber diets, colonic spasm, and the unique anatomy of the colon. Inflammation of diverticula, *diverticulitis*, affects a minority of persons with *diverticulosis* but can cause perforation in its most severe form.

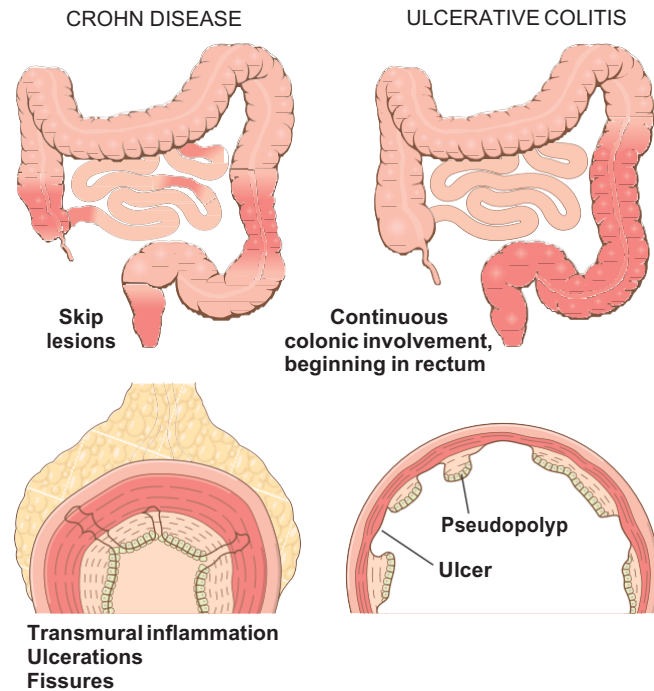
**Inflammatory Bowel Disease**

*Inflammatory bowel disease* (IBD) is a chronic condition resulting from inappropriate mucosal immune activation. IBD encompasses two major entities, *Crohn disease* and *ulcerative colitis*. The distinction between ulcerative colitis and Crohn disease is based, in large part, on the distribution of affected sites and the morphologic expression of disease at those sites (Fig. 14-26; Table 14-5). *Ulcerative colitis* is limited to the colon and rectum and extends only into the mucosa and submucosa. By contrast, *Crohn disease*, which

**Table 14-5** Features That Differ Between Crohn Disease and Ulcerative Colitis

Feature	Crohn Disease	Ulcerative Colitis
<b>Macroscopic</b>		
Bowel region affected	Ileum ± colon	Colon only
Rectal involvement	Sometimes	Always
Distribution	Skip lesions	Diffuse
Stricture	Yes	Rare
Bowel wall appearance	Thick	Thin
Inflammation	Transmural	Limited to mucosa and submucosa
Pseudopolyps	Moderate	Marked
Ulcers	Deep, knifelike	Superficial, broad-based
Lymphoid reaction	Marked	Moderate
Fibrosis	Marked	Mild to none
Serositis	Marked	No
Granulomas	Yes (~35%)	No
Fistulas/sinuses	Yes	No
<b>Clinical</b>		
Perianal fistula	Yes (in colonic disease)	No
Fat/vitamin malabsorption	Yes	No
Malignant potential	With colonic involvement	Yes
Recurrence after surgery	Common	No
Toxic megacolon	No	Yes

NOTE: Not all features may be present in a single case.



**Figure 14-26** Distribution of lesions in inflammatory bowel disease. The distinction between Crohn disease and ulcerative colitis is based primarily on morphology.

also has been referred to as regional enteritis (because of frequent ileal involvement), may involve any area of the gastrointestinal tract and frequently is transmural.

**Epidemiology**

Both Crohn disease and ulcerative colitis are more common in females and frequently present during adolescence or in young adults. In Western industrialized nations, IBD is most common among whites and, in the United States, occurs 3 to 5 times more often among eastern European (Ashkenazi) Jews. This predilection is at least partly due to genetic factors, as discussed next under “Pathogenesis.” The geographic distribution of IBD is highly variable, but it is most prevalent in North America, northern Europe, and Australia. IBD incidence worldwide is on the rise and is becoming more common in regions in which the prevalence was historically low. The *hygiene hypothesis* suggests that these changes in incidence are related to improved food storage conditions and decreased food contamination. Specifically, it proposes that a reduced frequency of enteric infections due to improved hygiene has resulted in inadequate development of regulatory processes that limit mucosal immune responses early in life. As a result, exposure of susceptible individuals to normally innocuous microbes later in life triggers inappropriate immune responses that may be self-sustaining due to loss of intestinal epithelial barrier function. Although many details are

lacking, some data, including some from animal models and the observation in humans that an episode of acute infectious gastroenteritis increases the risk of developing IBD, are consistent with the hygiene hypothesis.

## PATHOGENESIS

The cause(s) of IBD remains uncertain. However, **most investigators believe that IBD results from a combination of errant host interactions with intestinal microbiota, intestinal epithelial dysfunction, and aberrant mucosal immune responses.** This view is supported by epidemiologic, genetic, and clinical studies as well as data from laboratory models of IBD (Fig. 14–27).

- **Genetics.** Risk of disease is increased when there is an affected family member, and in Crohn disease, the concordance rate for monozygotic twins is approximately 50%. By contrast, concordance of monozygotic twins for ulcerative colitis is only 16%, suggesting that genetic factors are less dominant in this form of IBD.

Molecular linkage analyses of affected families have identified *NOD2* (nucleotide oligomerization binding domain 2) as a susceptibility gene in Crohn disease. *NOD2* encodes a protein that binds to intracellular bacterial peptidoglycans and subsequently activates NF- $\kappa$ B. It has been postulated that disease-associated *NOD2* variants are less effective at recognizing and combating luminal microbes, which are then able to enter the lamina propria and trigger inflammatory reactions. Other data suggest that *NOD2* may regulate immune responses to prevent excessive activation by luminal microbes. Whatever the mechanism by which *NOD2* polymorphisms contribute to the pathogenesis of Crohn disease, it should be recognized that disease

develops in less than 10% of persons carrying *NOD2* mutations, and *NOD2* mutations are uncommon in African and Asian patients with Crohn disease.

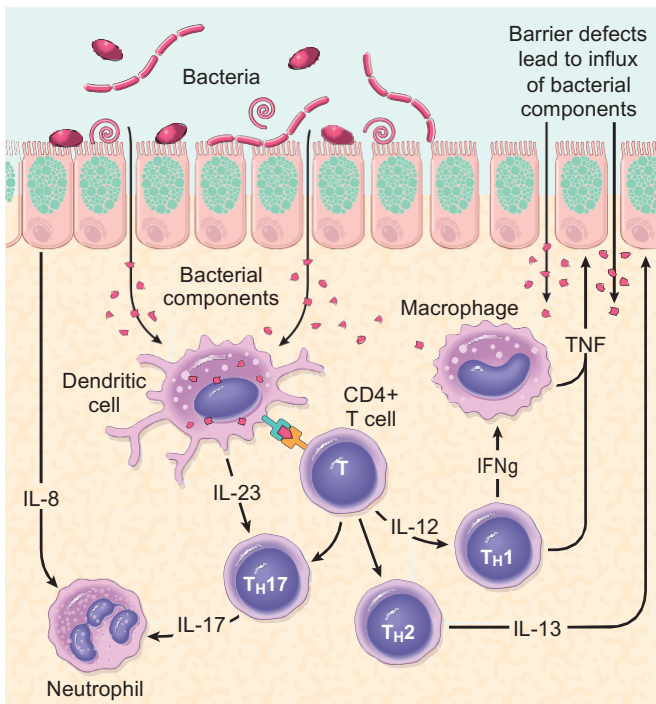
In recent years, genome-wide association studies (GWAS) that assess single-nucleotide polymorphisms have been used to broaden the search for IBD-associated genes. The number of genes identified by GWAS is increasing rapidly (already numbering more than 30), but along with *NOD2*, two Crohn disease–related genes of particular interest are *ATG16L1* (autophagy-related 16–like-1), a part of the autophagosome pathway that is critical to host cell responses to intracellular bacteria, and *IRGM* (immunity-related GTPase M), which also is involved in autophagy and clearance of intracellular bacteria. *NOD2*, *ATG16L1*, and *IRGM* are expressed in multiple cell types, and their precise roles in the pathogenesis of Crohn disease have yet to be defined. Like *NOD2*, however, *ATG16L1* and *IRGM* are related to recognition and response to intracellular pathogens, supporting the hypothesis that inappropriate immune reactions to luminal bacteria are important in pathogenesis of IBD. None of these genes are associated with ulcerative colitis.

- **Mucosal immune responses.** Although the mechanisms by which mucosal immunity contributes to the pathogenesis of ulcerative colitis and Crohn disease are still being deciphered, immunosuppressive and immunomodulatory agents remain mainstays of IBD therapy. Polarization of helper T cells to the  $T_H1$  type is well recognized in Crohn disease, and emerging data suggest that  $T_H17$  T cells also contribute to disease pathogenesis. Consistent with this, certain polymorphisms of the IL-23 receptor confer protection from Crohn disease and ulcerative colitis (IL-23 is involved in the development and maintenance of  $T_H17$  cells). The protection afforded by IL-23 receptor polymorphisms, together with the recognized effectiveness of anti-TNF therapy in some patients with ulcerative colitis, seems to support roles for  $T_H1$  and  $T_H17$  cells.

Some data suggest that the pathogenic immune response in ulcerative colitis includes a significant  $T_H2$  component. For example, mucosal IL-13 production is increased in ulcerative colitis, and, to a lesser degree, Crohn disease. However, the pathogenic role of  $T_H2$  cells in IBD pathogenesis remains controversial. Polymorphisms of the *IL-10* gene as well as *IL-10R*, the IL10 receptor gene, have been linked to ulcerative colitis but not Crohn disease, further emphasizing the importance of immunoregulatory signals in IBD pathogenesis.

Overall, it is likely that some combination of derangements that activate mucosal immunity and suppress immunoregulation contribute to the development of both ulcerative colitis and Crohn disease. The relative roles of the innate and adaptive arms of the immune system are the subject of ongoing intense scrutiny.

- **Epithelial defects.** A variety of epithelial defects have been described in Crohn disease, ulcerative colitis, or both. For example, defects in intestinal epithelial tight junction barrier function are present in patients with Crohn disease and a subset of their healthy first-degree relatives. This barrier dysfunction cosegregates with specific disease-associated *NOD2* polymorphisms, and experimental models demonstrate that barrier dysfunction can activate



**Figure 14–27** A model of pathogenesis of inflammatory bowel disease (IBD). Aspects of both Crohn disease and ulcerative colitis are shown.



innate and adaptive mucosal immunity and sensitize subjects to disease. Interestingly, the Paneth cell granules, which contain antimicrobial peptides that can affect composition of the luminal microbiota, are abnormal in patients with Crohn disease carrying *ATG16L1* mutations, thus providing one potential mechanism where a defective feedback loop between the epithelium and microbiota could contribute to disease pathogenesis.

- **Microbiota.** The quantity of microbial organisms in the gastrointestinal lumen is enormous, amounting to as many as  $10^{12}$  organisms/mL of fecal material in the colon (50% of fecal mass). This abundance means that, on a per cell level, we are only about 10% human. There is significant inter-individual variation in the composition of this microbial population, which is modified by diet and disease. Despite a growing body of data that suggest that intestinal microbiota contribute to IBD pathogenesis, their precise role remains to be defined. In keeping with this, some antibiotics, such as metronidazole, can be helpful in maintenance of remission in Crohn disease. Ongoing studies suggest that ill-defined mixtures containing probiotic, or beneficial, bacteria also may combat disease in experimental models, as well as in some patients with IBD, although the mechanisms responsible are not well understood.

One model that unifies the roles of intestinal microbiota, epithelial function, and mucosal immunity suggests a cycle by which transepithelial flux of luminal bacterial components activates innate and adaptive immune responses. In a genetically susceptible host, the subsequent release of TNF and other immune-mediated signals direct epithelia to increase tight junction permeability, which further increases the flux of luminal material. These events may establish a self-amplifying cycle in which a stimulus at any site may be sufficient to initiate IBD. Although this model is helpful in advancing the current understanding of IBD pathogenesis, a variety of factors are associated with disease for unknown reasons. For example, a single episode of appendicitis is associated with reduced risk of developing ulcerative colitis. Tobacco use also modifies the risk of IBD. Somewhat surprisingly, the risk of Crohn disease is increased by smoking, whereas that of ulcerative colitis is reduced.

## Crohn Disease

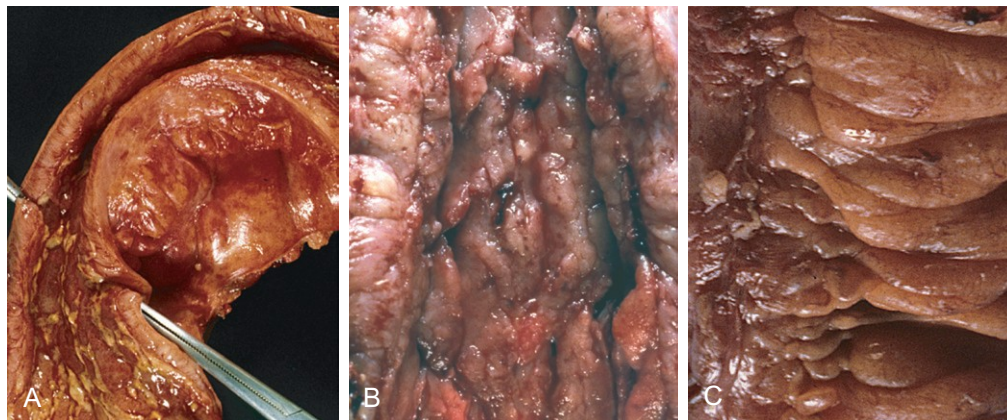
Crohn disease, also known as regional enteritis, may occur in any area of the gastrointestinal tract.

### MORPHOLOGY

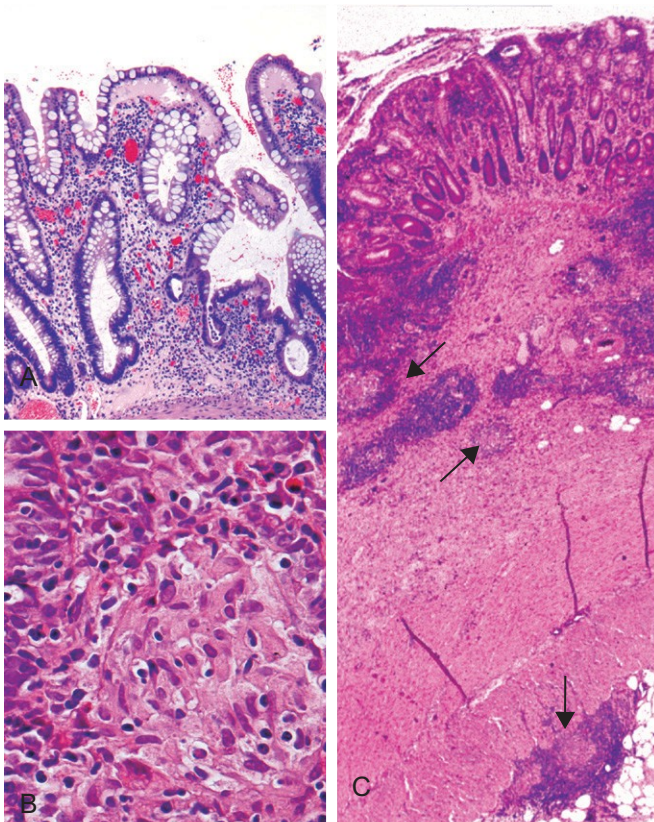
The most common sites involved by Crohn disease at presentation are the **terminal ileum, ileocecal valve, and cecum**. Disease is limited to the small intestine alone in about 40% of cases; the small intestine and the colon both are involved in 30% of patients; and the remainder of cases are characterized by colonic involvement only. The presence of multiple, separate, sharply delineated areas of disease, resulting in **skip lesions**, is characteristic of Crohn disease and may help in differentiation from ulcerative colitis. Strictures are common (Fig. 14–28, A).

The earliest lesion, the **aphthous ulcer**, may progress, and multiple lesions often coalesce into elongated, serpentine ulcers oriented along the axis of the bowel. Edema and loss of normal mucosal folds are common. Sparing of interspersed mucosa results in a coarsely textured, **cobblestone** appearance in which diseased tissue is depressed below the level of normal mucosa (Fig. 14–28, B). **Fissures** frequently develop between mucosal folds and may extend deeply to become sites of perforation or fistula tracts. The intestinal wall is thickened as a consequence of transmural edema, inflammation, submucosal fibrosis, and hypertrophy of the muscularis propria, all of which contribute to stricture formation. In cases with extensive transmural disease, mesenteric fat frequently extends around the serosal surface (**creeping fat**) (Fig. 14–28, C).

The microscopic features of active Crohn disease include abundant neutrophils that infiltrate and damage crypt epithelium. Clusters of neutrophils within a crypt are referred to as a **crypt abscess** and often are associated with crypt destruction. Ulceration is common in Crohn disease, and there may be an abrupt transition between ulcerated and normal mucosa. Repeated cycles of crypt destruction and regeneration lead to **distortion of mucosal architecture**; the normally straight and parallel crypts take on bizarre branching shapes and unusual orientations to one another (Fig. 14–29,



**Figure 14–28** Gross pathology of Crohn disease. **A**, Small intestinal stricture. **B**, Linear mucosal ulcers and thickened intestinal wall. **C**, Creeping fat.



**Figure 14-29** Microscopic pathology of Crohn disease. **A**, Haphazard crypt organization results from repeated injury and regeneration. **B**, Non-caseating granuloma. **C**, Transmural Crohn disease with submucosal and serosal granulomas (arrows).

**A**). Epithelial metaplasia, another consequence of chronic relapsing injury, often takes the form of gastric antral-appearing glands (pseudopyloric metaplasia). **Paneth cell metaplasia** also may occur in the left colon, where Paneth cells normally are absent. These architectural and metaplastic changes may persist even when active inflammation has resolved. Mucosal atrophy, with loss of crypts, may result after years of disease. **Noncaseating granulomas** (Fig. 14-29, **B**), a hallmark of Crohn disease, are found in approximately 35% of cases and may arise in areas of active disease or uninvolved regions in any layer of the intestinal wall (Fig. 14-29, **C**). Granulomas also may be found in mesenteric lymph nodes. Cutaneous granulomas form nodules that are referred to (misleadingly) as **metastatic Crohn disease**. **The absence of granulomas does not preclude a diagnosis of Crohn disease.**

#### Clinical Features

The clinical manifestations of Crohn disease are extremely variable. *In most patients, disease begins with intermittent attacks of relatively mild diarrhea, fever, and abdominal pain.* Approximately 20% of patients present acutely with right lower quadrant pain, fever, and bloody diarrhea that may mimic acute appendicitis or bowel perforation. Periods of active disease typically are interrupted by asymptomatic intervals that last for weeks to many months. Disease

reactivation can be associated with a variety of external triggers, including physical or emotional stress, specific dietary items, and cigarette smoking.

Iron deficiency anemia may develop in persons with colonic disease, while extensive small bowel disease may result in serum protein loss and hypoalbuminemia, generalized nutrient malabsorption, or malabsorption of vitamin B<sub>12</sub> and bile salts. Fibrosing strictures, particularly of the terminal ileum, are common and require surgical resection. Disease often recurs at the site of anastomosis, and as many as 40% of patients require additional resections within 10 years. Fistulas develop between loops of bowel and may also involve the urinary bladder, vagina, and abdominal or perianal skin. Perforations and peritoneal abscesses are common.

Extraintestinal manifestations of Crohn disease include uveitis, migratory polyarthritis, sacroiliitis, ankylosing spondylitis, erythema nodosum, and clubbing of the fingertips, any of which may develop before intestinal disease is recognized. Pericholangitis and primary sclerosing cholangitis also occur in Crohn disease but are more common in ulcerative colitis. As discussed later on, risk of colonic adenocarcinoma is increased in patients with long-standing colonic Crohn disease.

#### Ulcerative Colitis

Ulcerative colitis is closely related to Crohn disease. However, ulcerative colitis is limited to the colon and rectum. Some extraintestinal manifestations of ulcerative colitis overlap with those of Crohn disease, including migratory polyarthritis, sacroiliitis, ankylosing spondylitis, uveitis, skin lesions, pericholangitis, and primary sclerosing cholangitis.

## MORPHOLOGY

Ulcerative colitis always involves the rectum and extends proximally in a continuous fashion to involve part or all of the colon. Skip lesions are not seen (although focal appendiceal or cecal inflammation occasionally may be present). Disease of the entire colon is termed **pancolitis** (Fig. 14-30, **A**). Disease limited to the rectum or rectosigmoid may be referred to descriptively as **ulcerative proctitis** or **ulcerative proctosigmoiditis**. The small intestine is normal, although mild mucosal inflammation of the distal ileum, **backwash ileitis**, may be present in severe cases of pancolitis.

On gross evaluation, involved colonic mucosa may be slightly red and granular-appearing or exhibit extensive **broad-based ulcers**. The transition between diseased and uninvolved colon can be abrupt (Fig. 14-30, **B**). Ulcers are aligned along the long axis of the colon but typically do not replicate the serpentine ulcers of Crohn disease. Isolated islands of regenerating mucosa often bulge into the lumen to create small elevations, termed **pseudopolyps**. Chronic disease may lead to **mucosal atrophy** and a flat, smooth mucosal surface lacking normal folds. Unlike in Crohn disease, **mural thickening is absent, the serosal surface is normal, and strictures do not occur**. However, inflammation and inflammatory mediators can damage the muscularis propria and disturb neuromuscular function leading to



colonic dilation and **toxic megacolon**, which carries a significant risk of perforation.

Histologic features of mucosal disease in ulcerative colitis are similar to those in colonic Crohn disease and include inflammatory infiltrates, crypt abscesses, crypt distortion, and epithelial metaplasia. However, **skip lesions are absent and inflammation generally is limited to the mucosa and superficial submucosa** (Fig. 14-30, C). In severe cases, mucosal damage may be accompanied by ulcers that extend more deeply into the submucosa, but the muscularis propria is rarely involved. Submucosal fibrosis, mucosal atrophy, and distorted mucosal architecture remain as residua of healed disease, but the histologic pattern also may revert to near normal after prolonged remission. **Granulomas are not present.**

### Clinical Features

Ulcerative colitis is a relapsing disorder characterized by attacks of bloody diarrhea with expulsion of stringy, mucoid material and lower abdominal pain and cramps that are temporarily relieved by defecation. These symptoms may persist for days, weeks, or months before they subside, and occasionally the initial attack may be severe enough to constitute a medical or surgical emergency. More than half of the patients have mild disease, and almost all experience at least one relapse during a 10-year period. Colectomy cures intestinal disease, but extraintestinal manifestations may persist.

The factors that trigger ulcerative colitis are not known, but as noted previously, infectious enteritis precedes disease onset in some cases. In other cases the first attack is preceded by psychological stress, which also may be linked to relapse during remission. The initial onset of symptoms also has been reported to occur shortly after smoking cessation in some patients, and smoking may partially relieve symptoms. Unfortunately, studies of nicotine as a therapeutic agent have been disappointing.

### Indeterminate Colitis

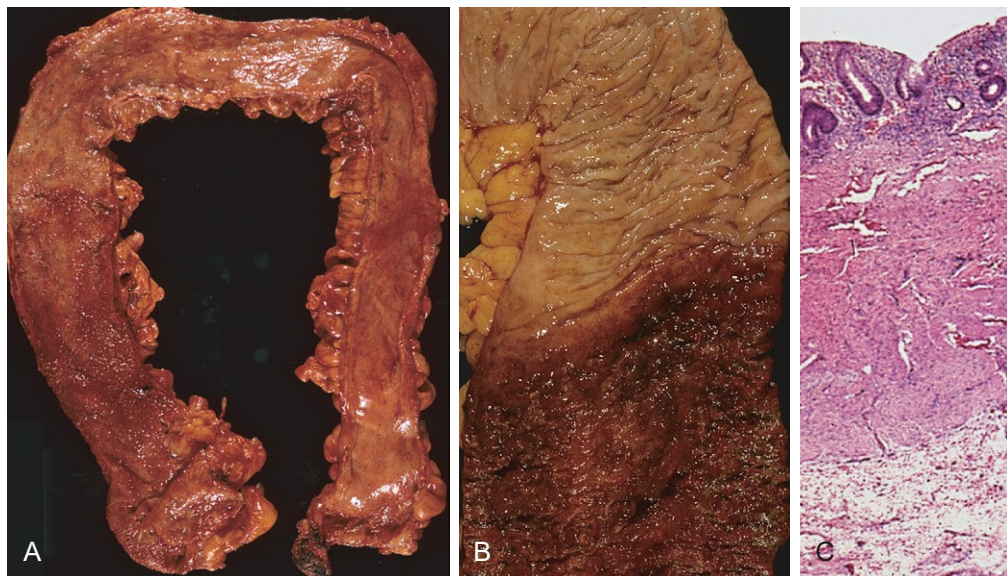
Histopathologic and clinical overlap between ulcerative colitis and Crohn disease is common, and it is not possible to make a distinction in up to 10% of patients with IBD. In such cases, termed *indeterminate colitis*, the small bowel is not involved, and the continuous pattern of colonic disease typically would indicate ulcerative colitis. However, patchy disease, fissures, a family history of Crohn disease, perianal lesions, onset after initiation of cigarette smoking, or findings that are not typical of ulcerative colitis may create uncertainty. Because of extensive overlap in medical management of ulcerative colitis and Crohn disease, patients carrying a diagnosis of indeterminate colitis can be treated effectively. Nevertheless, it is preferable, when possible, to definitively categorize patients, because evolving medical therapies and surgical management differ for ulcerative colitis and for Crohn disease.

### Colitis-Associated Neoplasia

One of the most feared long-term complications of ulcerative colitis and colonic Crohn disease is the development of neoplasia. This process begins as dysplasia, which, just as in Barrett esophagus and chronic gastritis, is a step along the road to full-blown carcinoma. The risk of dysplasia is related to several factors:

- Risk increases sharply 8 to 10 years after disease initiation.
- Patients with pancolitis are at greater risk than those with only left-sided disease.
- Greater frequency and severity of active inflammation (characterized by the presence of neutrophils) may increase risk. This is another example of the enabling effect of inflammation on carcinogenesis (Chapter 5).

To facilitate early detection of neoplasia, patients typically are enrolled in surveillance programs approximately 8 years after diagnosis of IBD. The primary exception to this approach is in patients with primary sclerosing cholangitis,



**Figure 14-30** Pathology of ulcerative colitis. **A**, Total colectomy with pancolitis showing active disease, with red, granular mucosa in the cecum (left) and smooth, atrophic mucosa distally (right). **B**, Sharp demarcation between active ulcerative colitis (bottom) and normal (top). **C**, This full-thickness histologic section shows that disease is limited to the mucosa. Compare with Figure 14-28, C.

who are at markedly greater risk for development of dysplasia and generally are enrolled for surveillance at the time of diagnosis. Surveillance requires regular and extensive mucosal biopsy, making it a costly practice. In many cases, dysplasia occurs in flat areas of mucosa that are not recognized as abnormal on gross evaluation. Thus, advanced endoscopic imaging techniques are beginning to be used experimentally to increase sensitivity of detection in normal-looking tissue.

IBD-associated dysplasia is classified histologically as low-grade or high-grade. High-grade dysplasia can be associated with invasive carcinoma at the same site or elsewhere in the colon and therefore often prompts colectomy, particularly when the changes are multifocal. Low-grade dysplasia may be treated with colectomy or monitored closely, depending on a variety of clinical factors. Colonic adenomas (discussed later on) also occur in patients with IBD, and in some cases these may be difficult to differentiate from a polypoid focus of IBD-associated dysplasia.

## SUMMARY

### Inflammatory Bowel Disease

- Inflammatory bowel disease (IBD) is an umbrella term for Crohn disease and ulcerative colitis.
- Crohn disease most commonly affects the terminal ileum and cecum, but any site within the gastrointestinal tract can be involved; skip lesions and noncaseating granulomas are common.
- Ulcerative colitis is limited to the colon, is continuous from the rectum, and ranges in extent from only rectal disease to pancolitis; neither skip lesions nor granulomas are present.
- Both Crohn disease and ulcerative colitis can have extraintestinal manifestations.
- The risk of colonic epithelial dysplasia and adenocarcinoma is increased in patients who have had IBD for more than 8 to 10 years.

## COLONIC POLYPS AND NEOPLASTIC DISEASE

Polyps are most common in the colon but may occur in the esophagus, stomach, or small intestine. Those without stalks are referred to as *sessile*. As sessile polyps enlarge, proliferation of cells adjacent to the polyp and the effects of traction on the luminal protrusion, may combine to create a stalk. Polyps with stalks are termed *pedunculated*. In general, intestinal polyps can be classified as non-neoplastic or neoplastic. The most common neoplastic polyp is the adenoma, which has the potential to progress to cancer. Non-neoplastic colonic polyps can be further classified as inflammatory, hamartomatous, or hyperplastic.

### Inflammatory Polyps

The polyp that forms as part of the *solitary rectal ulcer syndrome* is an example of the purely inflammatory lesion.

Patients present with the clinical triad of rectal bleeding, mucus discharge, and an inflammatory lesion of the anterior rectal wall. The underlying cause is impaired relaxation of the anorectal sphincter, creating a sharp angle at the anterior rectal shelf. This leads to recurrent abrasion and ulceration of the overlying rectal mucosa. Chronic cycles of injury and healing produce a polypoid mass made up of inflamed and reactive mucosal tissue.

### Hamartomatous Polyps

Hamartomatous polyps occur sporadically and as components of various genetically determined or acquired syndromes (Table 14-6). As described previously, hamartomas are disorganized, tumor-like growths composed of mature cell types normally present at the site at which the polyp develops. Hamartomatous polyposis syndromes are rare, but they are important to recognize because of associated intestinal and extraintestinal manifestations and the need to screen family members.

### Juvenile Polyps

*Juvenile polyps* are the most common type of hamartomatous polyp. They may be *sporadic* or *syndromic*. In adults, the sporadic form sometimes is also referred to as an *inflammatory polyp*, particularly when dense inflammatory infiltrates are present. The vast majority of juvenile polyps occur in children younger than 5 years of age. *Juvenile polyps characteristically are located in the rectum*, and most manifest with rectal bleeding. In some cases, prolapse occurs and the polyp protrudes through the anal sphincter. Sporadic juvenile polyps are usually solitary but in persons with the autosomal dominant syndrome of juvenile polyposis the number varies from 3 to as many as 100. Colectomy may be required to limit the hemorrhage associated with polyp ulceration in juvenile polyposis. Dysplasia occurs in a small proportion of (mostly syndrome-associated) juvenile polyps, and the juvenile polyposis syndrome is associated with increased risk for the development of colonic adenocarcinoma.

## MORPHOLOGY

Individual sporadic and syndromic juvenile polyps often are indistinguishable. They typically are pedunculated, smooth-surfaced, reddish lesions that are less than 3 cm in diameter and display characteristic cystic spaces on cut sections. Microscopic examination shows the spaces to be dilated glands filled with mucin and inflammatory debris (Fig. 14-31, A). Some data suggest that mucosal hyperplasia is the initiating event in polyp development, and this mechanism is consistent with the discovery that mutations in pathways that regulate cellular growth, such as transforming growth factor- $\beta$  (TGF- $\beta$ ) signaling, are associated with autosomal dominant juvenile polyposis.

### Peutz-Jeghers Syndrome

Peutz-Jeghers syndrome is a rare autosomal dominant disorder defined by the presence of multiple gastrointestinal



**Table 14-6** Gastrointestinal (GI) Polyposis Syndromes

Syndrome	Mean Age at Presentation (years)	Mutated Gene(s)	GI Lesions	Selected Extragastrointestinal Manifestations
Peutz-Jeghers syndrome	10–15	<i>LKB1/STK11</i>	Arborizing polyps—small intestine > colon > stomach; colonic adenocarcinoma	Mucocutaneous pigmentation; increased risk of thyroid, breast, lung, pancreas, gonadal, and bladder cancers
Juvenile polyposis	<5	<i>SMAD4, BMPRIA</i>	Juvenile polyps; increased risk of gastric, small intestinal, colonic, and pancreatic adenocarcinoma	Pulmonary arteriovenous malformations, digital clubbing
Cowden syndrome, Bannayan-Ruvalcaba-Riley syndrome	<15	<i>PTEN</i>	Hamartomatous polyps, lipomas, ganglioneuromas, inflammatory polyps; increased risk of colon cancer	Benign skin tumors, benign and malignant thyroid and breast lesions
Cronkhite-Canada syndrome	>50	Nonhereditary	Hamartomatous colon polyps, crypt dilatation and edema in nonpolypoid mucosa	Nail atrophy, hair loss, abnormal skin pigmentation, cachexia, anemia
Tuberous sclerosis	Infancy to adulthood	<i>TSC1, TSC2</i>	Hamartomatous polyps (rectal)	Facial angiofibroma, cortical tubers, renal angiomyolipoma
Familial adenomatous polyposis (FAP)				
Classic FAP	10–15	<i>APC, MUTYH</i>	Multiple adenomas	Congenital RPE hypertrophy
Attenuated FAP	40–50	<i>APC, MUTYH</i>	Multiple adenomas	
Gardner syndrome	10–15	<i>APC, MUTYH</i>	Multiple adenomas	Osteomas, desmoids, skin cysts
Turcot syndrome	10–15	<i>APC, MUTYH</i>	Multiple adenomas	CNS tumors, medulloblastoma

CNS, central nervous system; RPE, retinal pigment epithelium.

hamartomatous polyps and mucocutaneous hyperpigmentation that carries an increased risk of several malignancies, including cancers of the colon, pancreas, breast, lung, ovaries, uterus, and testes, as well as other unusual neoplasms. Germ line heterozygous loss-of-function mutations in the gene *LKB1/STK11* are present in approximately half of the patients with the familial form of Peutz-Jeghers syndrome, as well as a subset of patients with the sporadic form. Intestinal polyps are most common in the small intestine, although they may also occur in the stomach and colon and, rarely, in the bladder and lungs. On gross evaluation, the polyps are large and pedunculated with a lobulated contour. Histologic examination demonstrates a characteristic arborizing network of connective tissue, smooth muscle, lamina propria, and glands lined by normal-appearing intestinal epithelium (Fig. 14-31, B).

## Hyperplastic Polyps

Colonic hyperplastic polyps are common epithelial proliferations that typically are discovered in the sixth and seventh decades of life. The pathogenesis of hyperplastic polyps is incompletely understood, but formation of these lesions is thought to result from decreased epithelial cell turnover and delayed shedding of surface epithelial cells, leading to a “pileup” of goblet cells.

Although these lesions have no malignant potential, they must be distinguished from sessile serrated adenomas, histologically similar lesions that have malignant potential, as described later.

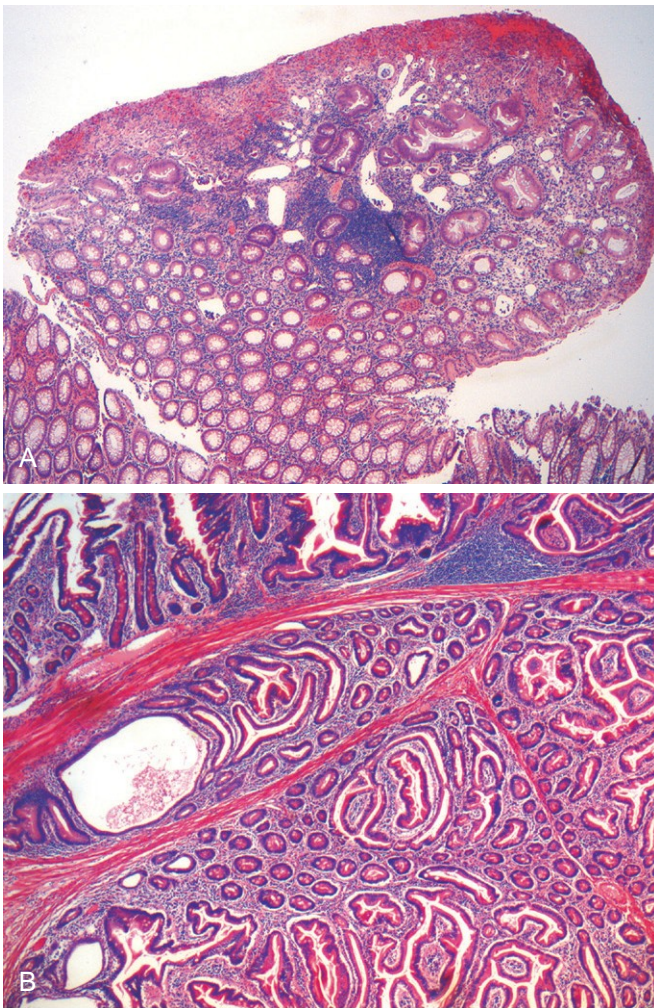
## MORPHOLOGY

Hyperplastic polyps are most commonly found in the left colon and typically are less than 5 mm in diameter. They are smooth, nodular protrusions of the mucosa, often on the crests of mucosal folds. They may occur singly but more frequently are multiple, particularly in the sigmoid colon and rectum. Histologically, hyperplastic polyps are composed of mature goblet and absorptive cells. The delayed shedding of these cells leads to crowding that creates the serrated surface architecture that is the morphologic hallmark of these lesions (Fig. 14-32).

## Adenomas

Any neoplastic mass lesion in the gastrointestinal tract may produce a mucosal protrusion, or polyp. The most common and clinically important neoplastic polyps are *colonic adenomas*, *benign polyps that give rise to a majority of colorectal adenocarcinomas*. Most adenomas, however, do not progress to adenocarcinoma.

*Colorectal adenomas are characterized by the presence of epithelial dysplasia*. These growths range from small, often pedunculated polyps to large sessile lesions. There is no gender predilection, and they are present in nearly 50% of adults living in the Western world beginning age 50. Because these polyps are precursors to colorectal cancer, current recommendations are that all adults in the United States undergo surveillance colonoscopy starting at age 50. Because persons with a family history are at risk for

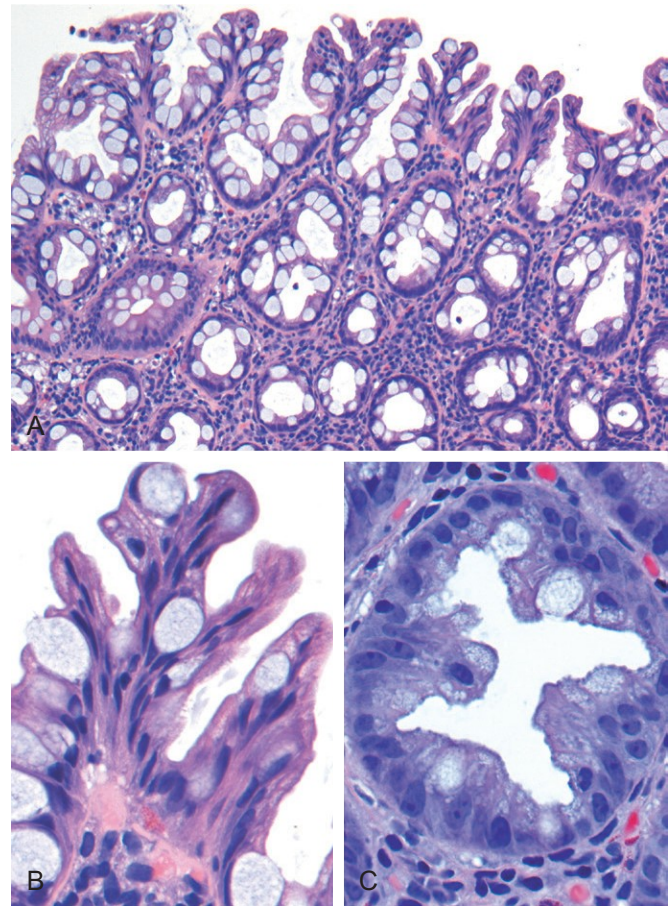


**Figure 14-31** Hamartomatous polyps. **A**, Juvenile polyp. Note the surface erosion and cystically dilated crypts filled with mucus, neutrophils, and debris. **B**, Peutz-Jeghers polyp. Complex glandular architecture and bundles of smooth muscle help to distinguish Peutz-Jeghers polyps from juvenile polyps.

developing colon cancer earlier in life, they typically are screened at least 10 years before the youngest age at which a relative was diagnosed. While adenomas are less common in Asia, their frequency has risen (in parallel with an increasing incidence of colorectal adenocarcinoma) as Western diets and lifestyles become more common.

## MORPHOLOGY

Typical adenomas range from 0.3 to 10 cm in diameter and can be **pedunculated** (Fig. 14-33, A) or **sessile**, with the surface of both types having a texture resembling velvet (Fig. 14-33, B) or a raspberry, due to the abnormal epithelial growth pattern. Histologically, the cytologic hallmark of **epithelial dysplasia** (Fig. 14-34, C) is nuclear hyperchromasia, elongation, and stratification. These changes are most easily appreciated at the surface of the adenoma, because the epithelium fails to mature as cells migrate out of the crypt. Pedunculated adenomas have slender fibromuscular stalks



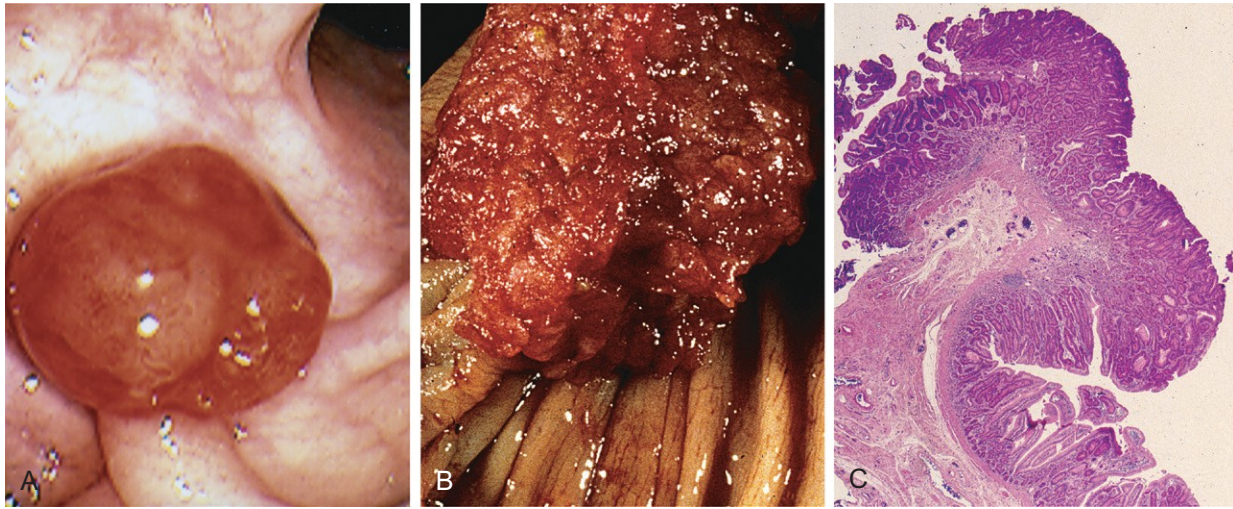
**Figure 14-32** Hyperplastic polyp. **A**, Polyp surface with irregular tufting of epithelial cells. **B**, Tufting results from epithelial overcrowding. **C**, Epithelial crowding produces a serrated architecture when glands are cut in cross-section.

(Fig. 14-33, C) containing prominent blood vessels derived from the submucosa. The stalk usually is covered by non-neoplastic epithelium, but dysplastic epithelium is sometimes present.

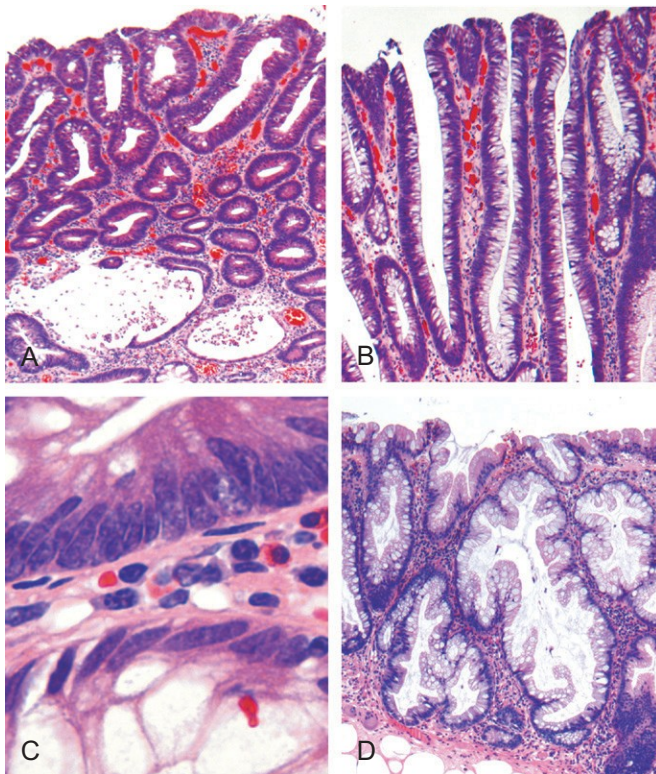
Adenomas can be classified as **tubular**, **tubulovillous**, or **villous** on the basis of their architecture. These categories, however, have little clinical significance in isolation. Tubular adenomas tend to be small, pedunculated polyps composed of small, rounded or tubular glands (Fig. 14-34, A). By contrast, villous adenomas, which often are larger and sessile, are covered by slender villi (Fig. 14-34, B). Tubulovillous adenomas have a mixture of tubular and villous elements. Although foci of invasion are more frequent in villous adenomas than in tubular adenomas, villous architecture alone does not increase cancer risk when polyp size is considered.

The histologic features of **sessile serrated adenomas** overlap with those of hyperplastic polyps and the typical cytologic features of dysplasia are lacking (Fig. 14-34, D). However, these lesions, which are most common in the right colon, have a malignant potential similar to that of traditional adenomas. The most useful histologic feature that distinguishes sessile serrated adenomas and hyperplastic polyps is the presence of serrated architecture throughout the full length of the glands, including the crypt base, associated with crypt dilation and lateral growth, in the former (Fig. 14-34,





**Figure 14-33** Colonic adenomas. **A**, Pedunculated adenoma (endoscopic view). **B**, Adenoma with a velvety surface. **C**, Low-magnification photomicrograph of a pedunculated tubular adenoma.



**Figure 14-34** Histologic appearance of colonic adenomas. **A**, Tubular adenoma with a smooth surface and rounded glands. In this case, crypt dilation and rupture, with associated reactive inflammation, can be seen at the bottom of the field. **B**, Villous adenoma with long, slender projections that are reminiscent of small intestinal villi. **C**, Dysplastic epithelial cells (top) with an increased nuclear-to-cytoplasmic ratio, hyperchromatic and elongated nuclei, and nuclear pseudostratification. Compare with the nondysplastic epithelium below. **D**, Sessile serrated adenoma lined by goblet cells without typical cytologic features of dysplasia. This lesion is distinguished from a hyperplastic polyp by involvement of the crypts. Compare with the hyperplastic polyp in [Figure 14-32](#).

**D**). By contrast, serrated architecture typically is confined to the surface of hyperplastic polyps.

Although most colorectal adenomas are benign lesions, a small proportion may harbor invasive cancer at the time of detection. **Size is the most important characteristic that correlates with risk of malignancy.** For example, while cancer is extremely rare in adenomas less than 1 cm in diameter, some studies suggest that nearly 40% of lesions larger than 4 cm in diameter contain foci of cancer. In addition to size, high-grade dysplasia is a risk factor for cancer in an individual polyp (but not other polyps in the same patient).

## Familial Syndromes

Several syndromes associated with colonic polyps and increased rates of colon cancer have been described. The genetic basis of these disorders has been established and has greatly enhanced the current understanding of sporadic colon cancer ([Table 14-7](#)).

### Familial Adenomatous Polypos

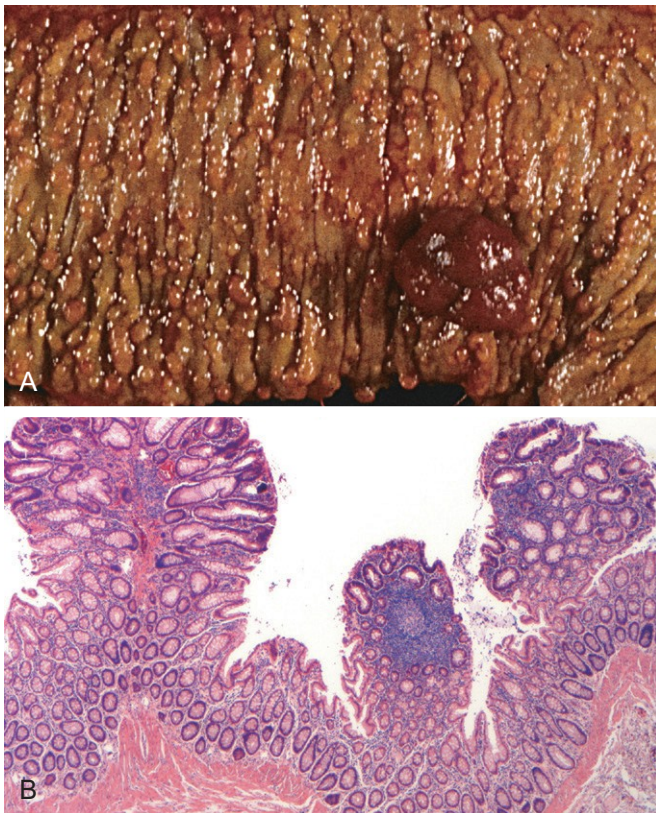
Familial adenomatous polyposis (FAP) is an autosomal dominant disorder marked by the appearance of numerous colorectal adenomas by the teenage years. It is caused by mutations of the *adenomatous polyposis coli* gene (*APC*). A count of at least 100 polyps is necessary for a diagnosis of classic FAP, and as many as several thousand may be present ([Fig. 14-35](#)). Except for their remarkable numbers, these growths are morphologically indistinguishable from sporadic adenomas. Colorectal adenocarcinoma develops in 100% of patients with untreated FAP, often before age 30. As a result, prophylactic colectomy is standard therapy for persons carrying *APC* mutations. However, patients remain at risk for *extraintestinal manifestations*, including neoplasia at other sites. Specific *APC* mutations are also associated with the development of other manifestations of FAP and explain variants such as Gardner syndrome and Turcot syndrome. In addition to intestinal polyps, clinical features of *Gardner syndrome*, a variant of FAP, may include osteomas of



**Table 14-7** Common Patterns of Sporadic and Familial Colorectal Neoplasia

Etiology	Molecular Defect	Target Gene(s)	Transmission	Predominant Site(s)	Histology
Familial adenomatous polyposis (70% of FAP)	APC/WNT pathway	APC	Autosomal dominant	None	Tubular, villous; typical adenocarcinoma
Familial adenomatous polyposis (<10% of FAP)	DNA mismatch repair	<i>MUTYH</i>	None, recessive	None	Sessile serrated adenoma; mucinous adenocarcinoma
Hereditary nonpolyposis colorectal cancer	DNA mismatch repair	<i>MSH2, MLH1</i>	Autosomal dominant	Right side	Sessile serrated adenoma; mucinous adenocarcinoma
Sporadic colon cancer (80%)	APC/WNT pathway	APC	None	Left side	Tubular, villous; typical adenocarcinoma
Sporadic colon cancer (10% to 15%)	DNA mismatch repair	<i>MSH2, MLH1</i>	None	Right side	Sessile serrated adenoma; mucinous adenocarcinoma

mandible, skull, and long bones; epidermal cysts; desmoid and thyroid tumors; and dental abnormalities, including unerupted and supernumerary teeth. *Turcot syndrome* is rarer and is characterized by intestinal adenomas and tumors of the central nervous system. Two thirds of patients with *Turcot syndrome* have *APC* gene mutations and develop medulloblastomas. The remaining one third have mutations in one of several genes involved in DNA repair and develop glioblastomas. Some patients who have FAP without *APC* loss have mutations of the base excision repair gene *MUTYH*. The role of these genes in tumor development is discussed below.



**Figure 14-35** Familial adenomatous polyposis. **A**, Hundreds of small colonic polyps are present along with a dominant polyp (right). **B**, Three tubular adenomas are present in this single microscopic field.

### Hereditary Nonpolyposis Colorectal Cancer

*Hereditary nonpolyposis colorectal cancer* (HNPCC), also known as *Lynch syndrome*, originally was described as familial clustering of cancers at several sites including the colorectum, endometrium, stomach, ovary, ureters, brain, small bowel, hepatobiliary tract, and skin. Colon cancers in patients with HNPCC tend to occur at *younger ages* than for sporadic colon cancers and often are located in the *right colon* (Table 14-7).

Just as identification of *APC* mutations in FAP has provided molecular insights into the pathogenesis of a majority of sporadic colon cancers, dissection of the defects in HNPCC has shed light on the mechanisms responsible for most of the remaining sporadic cases. HNPCC is caused by inherited germline mutations in genes that encode proteins responsible for the detection, excision, and repair of errors that occur during DNA replication. At least five such mismatch repair genes have been recognized, but a majority of HNPCC cases involve either *MSH2* or *MLH1*. Patients with HNPCC inherit one mutated DNA repair gene and one normal allele. When the second copy is lost through mutation or epigenetic silencing, defects in mismatch repair lead to the accumulation of mutations at rates up to 1000 times higher than normal, mostly in regions containing short repeating DNA sequences referred to as microsatellite DNA. The human genome contains approximately 50,000 to 100,000 microsatellites, which are prone to undergo expansion during DNA replication and represent the most frequent sites of mutations in HNPCC. The consequences of mismatch repair defects and the resulting *microsatellite instability* are discussed next in the context of colonic adenocarcinoma.

### Adenocarcinoma

Adenocarcinoma of the colon is the most common malignancy of the gastrointestinal tract and is a major contributor to morbidity and mortality worldwide. By contrast, the small intestine, which accounts for 75% of the overall length of the gastrointestinal tract, is an uncommon site for benign and malignant tumors. Among malignant small intestinal tumors, adenocarcinomas and carcinoid tumors have roughly equal rates of occurrence, followed by lymphomas and sarcomas.



## Epidemiology

Each year in the United States there are more than 130,000 new cases and 55,000 deaths from colorectal adenocarcinoma. This represents nearly 15% of all cancer-related deaths, second only to lung cancer. Colorectal cancer incidence peaks at 60 to 70 years of age, and less than 20% of cases occur before age 50. Males are affected slightly more often than females. Colorectal carcinoma is most prevalent in the United States, Canada, Australia, New Zealand, Denmark, Sweden, and other developed countries. The incidence of this cancer is as much as 30-fold lower in India, South America, and Africa. In Japan, where incidence was previously very low, rates have now risen to intermediate levels (similar to those in the United Kingdom), presumably as a result of changes in lifestyle and diet.

The dietary factors most closely associated with increased colorectal cancer rates are low intake of unabsorbable vegetable fiber and high intake of refined carbohydrates and fat.

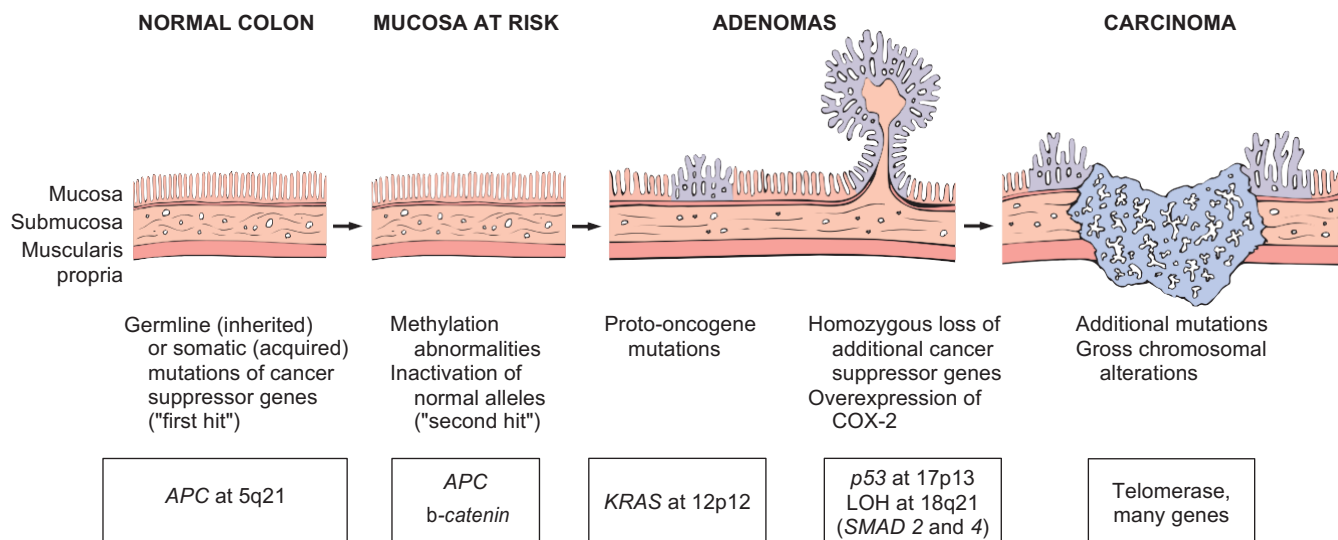
In addition to dietary modification, pharmacologic chemoprevention has become an area of great interest. Several epidemiologic studies suggest that aspirin or other NSAIDs have a protective effect. This is consistent with studies showing that some NSAIDs cause polyp regression in patients with FAP in whom the rectum was left in place after colectomy. It is suspected that this effect is mediated by inhibition of the enzyme cyclooxygenase-2 (COX-2), which is highly expressed in 90% of colorectal carcinomas and 40% to 90% of adenomas and is known to promote epithelial proliferation, particularly in response to injury.

## PATHOGENESIS

Studies of colorectal carcinogenesis have provided fundamental insights into the general mechanisms of cancer

evolution. The combination of molecular events that lead to colonic adenocarcinoma is heterogeneous and includes genetic and epigenetic abnormalities. At least two distinct genetic pathways APC/ $\beta$ -catenin pathway, have been described. In simplest terms, these are the disturbances of which lead to increased WNT signaling, and the microsatellite instability pathway, which is associated with defects in DNA mismatch repair (see Table 14-7). Both pathways involve the stepwise accumulation of multiple mutations, but the genes involved and the mechanisms by which the mutations accumulate differ. Epigenetic events, the most common of which is methylation-induced gene silencing, may enhance progression along both pathways.

- The **APC/ $\beta$ -catenin pathway**. The classic **adenoma-carcinoma sequence**, which accounts for as much as 80% of sporadic colon tumors, typically involves mutation of the APC tumor suppressor early in the neoplastic process (Fig. 14-36). Both copies of the APC gene must be functionally inactivated, either by mutation or epigenetic events, for adenomas to develop. **APC is a key negative regulator of  $\beta$ -catenin, a component of the WNT signaling pathway** (Chapter 5). The APC protein normally binds to and promotes degradation of  $\beta$ -catenin. With loss of APC function,  $\beta$ -catenin accumulates and translocates to the nucleus, where it activates the transcription of genes, such as those encoding MYC and cyclin D1, which promote proliferation. This is followed by additional mutations, including activating mutations in KRAS, which also promote growth and prevent apoptosis. The conclusion that mutation of KRAS is a late event is supported by the observation that mutations are present in fewer than 10% of adenomas less than 1 cm in diameter, in 50% of adenomas greater than 1 cm in diameter, and in 50% of invasive adenocarcinomas. Neoplastic progression also is associated with mutations in other



**Figure 14-36** Morphologic and molecular changes in the adenoma-carcinoma sequence. It is postulated that loss of one normal copy of the tumor suppressor gene APC occurs early. Persons may be born with one mutant allele, making them extremely prone to the development of colon cancer, or inactivation of APC may occur later in life. This is the "first hit" according to Knudson's hypothesis. The loss of the intact copy of APC follows ("second hit"). Other mutations involving KRAS, SMAD2, and SMAD4, and the tumor suppressor gene TP53, lead to the emergence of carcinoma, in which additional mutations occur. Although there may be a preferred temporal sequence for these changes, it is the aggregate effect of the mutations, rather than their order of occurrence, that appears most critical.

tumor suppressor genes such as those encoding SMAD2 and SMAD4, which are effectors of TGF- $\beta$  signaling. Because TGF- $\beta$  signaling normally inhibits the cell cycle, loss of these genes may allow unrestrained cell growth. The tumor suppressor gene *TP53* is mutated in 70% to 80% of colon cancers but is uncommonly affected in adenomas, suggesting that *TP53* mutations also occur at late stages of tumor progression. “Loss of function” of *TP53* and other tumor suppressor genes often is caused by chromosomal deletions, highlighting chromosomal instability as a hallmark of the APC/ $\beta$ -catenin pathway. Alternatively, tumor suppressor genes may be silenced by methylation of CpG islands, a 5' region of some genes that frequently includes the promoter and transcriptional start site. Expression of telomerase also increases as lesions become more advanced.

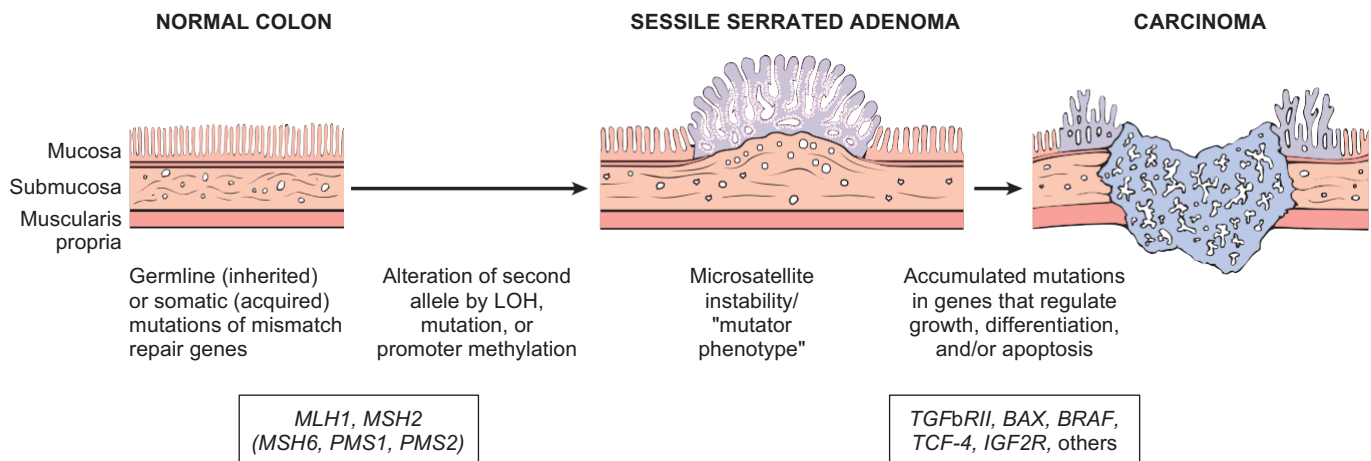
- **The microsatellite instability pathway.** In patients with DNA mismatch repair deficiency (due to loss of mismatch repair genes, as discussed earlier) mutations accumulate in microsatellite repeats, a condition referred to as **microsatellite instability**. These mutations generally are silent, because microsatellites typically are located in noncoding regions, but other microsatellite sequences are located in the coding or promoter regions of genes involved in regulation of cell growth, such as those encoding the type II TGF- $\beta$  receptor and the pro-apoptotic protein BAX (Fig. 14–37). Because TGF- $\beta$  inhibits colonic epithelial cell proliferation, type II TGF- $\beta$  receptor mutants can contribute to uncontrolled cell growth, while loss of BAX may enhance the survival of genetically abnormal clones. Mutations in the oncogene *BRAF* and silencing of distinct groups of genes due to CpG island hypermethylation also are common in cancers that develop through DNA mismatch repair defects. By contrast, *KRAS* and *TP53* typically are not mutated. Thus, the combination of microsatellite instability, *BRAF* mutation, and methylation of specific targets, such as *MLH1*, is the signature of this pathway of carcinogenesis.

## MORPHOLOGY

Overall, adenocarcinomas are distributed approximately equally over the entire length of the colon. **Tumors in the proximal colon often grow as polypoid, exophytic masses** that extend along one wall of the large-caliber cecum and ascending colon; these tumors rarely cause obstruction. By contrast, **carcinomas in the distal colon tend to be annular lesions that produce “napkin ring” constrictions and luminal narrowing** (Fig. 14–38), sometimes to the point of obstruction. Both forms grow into the bowel wall over time and may be palpable as firm masses. The general microscopic characteristics of right- and left-sided colonic adenocarcinomas are similar. Most tumors are composed of tall columnar cells that resemble dysplastic epithelium found in adenomas (Fig. 14–39, A). The invasive component of these tumors elicits a strong stromal desmoplastic response, which is responsible for their characteristic firm consistency. Some poorly differentiated tumors form few glands (Fig. 14–39, B). Others may produce abundant mucin that accumulates within the intestinal wall, and these carry a poor prognosis. Tumors also may be composed of signet ring cells that are similar to those in gastric cancer (Fig. 14–39, C).

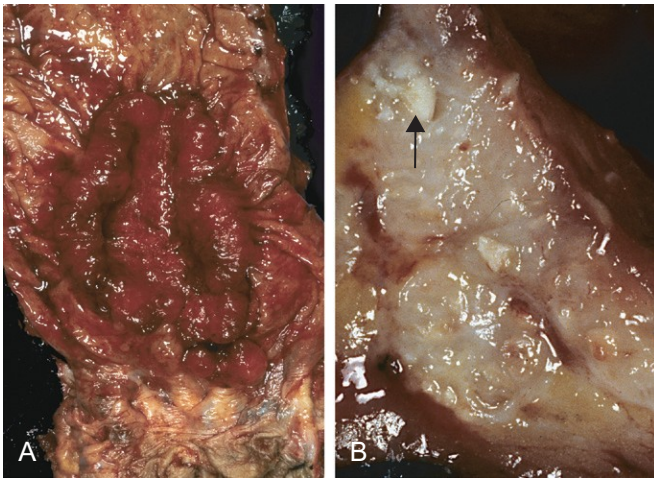
### Clinical Features

The availability of endoscopic screening combined with the recognition that most carcinomas arise within adenomas presents a unique opportunity for cancer prevention. Unfortunately, colorectal cancers develop insidiously and may therefore go undetected for long periods. Cecal and other *right-sided colon cancers* most often are called to clinical attention by the appearance of *fatigue and weakness due to iron deficiency anemia*. Thus, it is a clinical maxim that the underlying cause of iron deficiency anemia in an older man or postmenopausal woman is gastrointestinal cancer until proven otherwise. *Left-sided colorectal adenocarcinomas* may produce *occult bleeding, changes in bowel habits, or cramping left lower quadrant discomfort*.



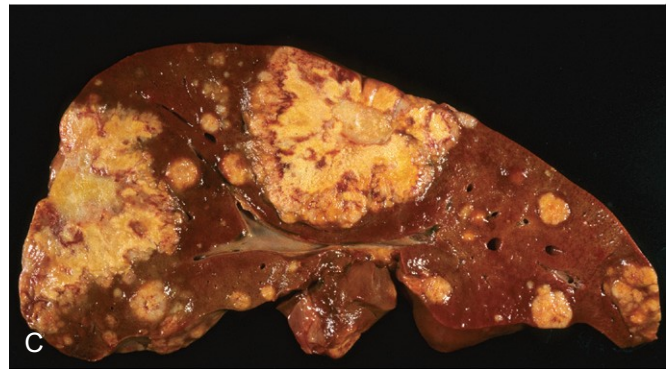
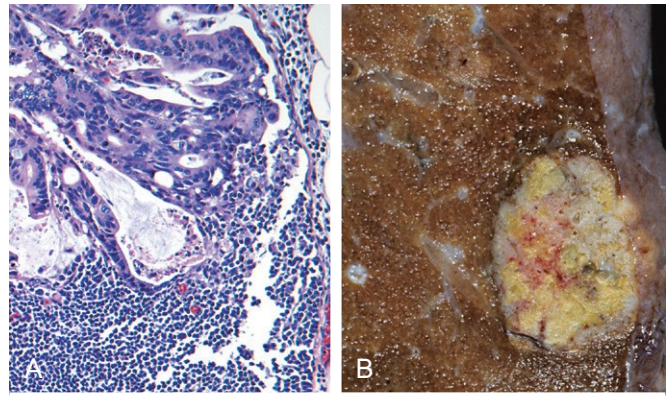
**Figure 14–37** Morphologic and molecular changes in the mismatch repair pathway of colon carcinogenesis. Defects in mismatch repair genes result in microsatellite instability and permit accumulation of mutations in numerous genes. If these mutations affect genes involved in cell survival and proliferation, cancer may develop. LOH, loss of heterozygosity.





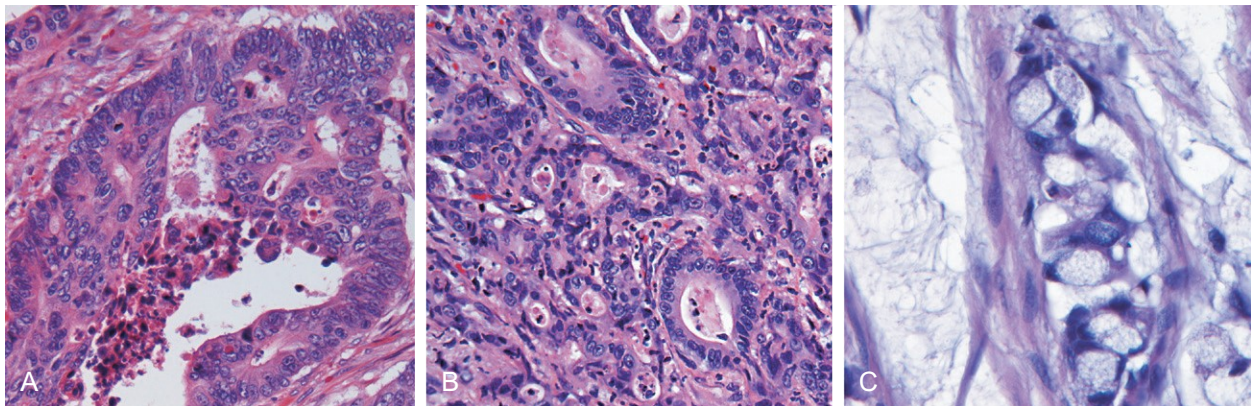
**Figure 14-38** Colorectal carcinoma. **A**, Circumferential, ulcerated rectal cancer. Note the anal mucosa at the bottom of the image. **B**, Cancer of the sigmoid colon that has invaded through the muscularis propria and is present within subserosal adipose tissue (left). Areas of chalky necrosis are present within the colon wall (arrow).

Although poorly differentiated and mucinous histologic patterns are associated with poor prognosis, *the two most important prognostic factors are depth of invasion and the presence or absence of lymph node metastases*. Invasion into the muscularis propria imparts significantly reduced survival that is decreased further by the presence of lymph node metastases (Fig. 14-40, A). These factors were originally recognized by Dukes and Kirklin and form the core of the TNM (tumor-node-metastasis) classification (Table 14-8) and staging system (Table 14-9) from the American Joint Committee on Cancer. Regardless of stage, however, some patients with small numbers of metastases do well for years after resection of distant tumor nodules. This observation once again emphasizes the clinical and molecular heterogeneity of colorectal carcinomas. Metastases may



**Figure 14-40** Metastatic colorectal carcinoma. **A**, Lymph node metastasis. Note the glandular structures within the subcapsular sinus. **B**, Solitary subpleural nodule of colorectal carcinoma metastatic to the lung. **C**, Liver containing two large and many smaller metastases. Note the central necrosis within metastases.

involve regional lymph nodes, lungs (Fig. 14-40, B), and bones, but because of the portal drainage, the liver is the most common site of metastatic lesions (Fig. 14-40, C). The rectum does not drain by way of the portal circulation, and metastases from carcinomas of the anal region often circumvent the liver.



**Figure 14-39** Histologic appearance of colorectal carcinoma. **A**, Well-differentiated adenocarcinoma. Note the elongated, hyperchromatic nuclei. Necrotic debris, present in the gland lumen, is typical. **B**, Poorly differentiated adenocarcinoma forms a few glands but is largely composed of infiltrating nests of tumor cells. **C**, Mucinous adenocarcinoma with signet ring cells and extracellular mucin pools.

**Table 14-8** AJCC Tumor-Node-Metastasis (TNM) Classification of Colorectal Carcinoma

Designation	Description
<b>Tumor</b>	
Tis	In situ dysplasia or intramucosal carcinoma
T1	Tumor invades submucosa
T2	Tumor invades into, but not through, muscularis propria
T3	Tumor invades through muscularis propria
T4	Tumor invades adjacent organs or visceral peritoneum
<b>Regional Lymph Nodes</b>	
NX	Lymph nodes cannot be assessed
N0	No regional lymph node metastasis
N1	Metastasis in one to three regional lymph nodes
N2	Metastasis in four or more regional lymph nodes
<b>Distant Metastasis</b>	
MX	Distant metastasis cannot be assessed
M0	No distant metastasis
M1	Distant metastasis or seeding of abdominal organs

AJCC, American Joint Committee on Cancer.

**Table 14-9** AJCC Colorectal Cancer Staging and Survival

Stage*	Tumor-Node-Metastasis (TNM) Criteria			5-Year Survival (%)
	T	N	M	
I	T1, T2	N0	M0	74
II	IIA	T3	N0	67
	IIB	T4	N0	59
III	IIIA	T1, T2	N1	73
	IIIB	T3, T4	N1	46
	IIIC	Any T	N2	28
IV	Any T	Any N	M1	6

\*Colorectal cancer staging is based on the TNM classification (Table 14-8). For example, a T3 tumor without nodal or distant metastases is classified as stage IIA and is associated with a 5-year survival rate of 67%.  
AJCC, American Joint Committee on Cancer.

## SUMMARY

### Colonic Polyps, Adenomas, and Adenocarcinomas

- Intestinal polyps* can be classified as non-neoplastic or neoplastic. The non-neoplastic polyps can be further defined as inflammatory, hamartomatous, or hyperplastic.
- Inflammatory polyps* form as a result of chronic cycles of injury and healing.
- Hamartomatous polyps* occur sporadically or as a part of genetic diseases. In the latter case, they often are associated with increased risk of malignancy.
- Hyperplastic polyps are benign epithelial proliferations most commonly found in the left colon and rectum. They are not reactive in origin, in contrast with gastric hyperplastic polyps; have no malignant potential; and must be distinguished from *sessile serrated adenomas*.
- Benign epithelial neoplastic polyps of the intestines are termed *adenomas*. The hallmark feature of these lesions, which are the precursors of colonic adenocarcinomas, is cytologic dysplasia.
- In contrast with traditional adenomas, *sessile serrated adenomas* lack cytologic dysplasia and share morphologic features with hyperplastic polyps.
- Familial adenomatous polyposis (FAP)* and *hereditary nonpolyposis colorectal cancer (HNPCC)* are the most common forms of familial colon cancer. FAP is caused by APC mutations, and patients typically have over 100 adenomas and develop colon cancer before the age of 30.
- HNPCC is caused by mutations in DNA mismatch repair genes. Patients with HNPCC have far fewer polyps and develop cancer at an older age than that typical for patients with FAP but at a younger age than in patients with sporadic colon cancer.
- FAP and HNPCC are examples of two distinct pathways of neoplastic transformation, both of which contribute to sporadic colon cancer.
- The vast majority of colonic cancers are adenocarcinomas. The two most important prognostic factors are *depth of invasion* and the presence or absence of *lymph node metastases*.

## APPENDIX

The appendix is a normal true diverticulum of the cecum. Like any diverticulum, it is prone to acute and chronic inflammation, and acute appendicitis is a relatively common entity. Other lesions, including tumors, can also occur in the appendix but are far less common.

### ACUTE APPENDICITIS

Acute appendicitis is most common in adolescents and young adults but may occur in any age group. The lifetime risk for appendicitis is 7%; males are affected slightly more often than females. Despite the prevalence of acute appendicitis, the diagnosis can be difficult to confirm

preoperatively, and the condition may be confused with mesenteric lymphadenitis (often secondary to unrecognized *Yersinia* infection or viral enterocolitis), acute salpingitis, ectopic pregnancy, mittelschmerz (pain associated with ovulation), and Meckel diverticulitis.

### PATHOGENESIS

Acute appendicitis is thought to be initiated by progressive increases in intraluminal pressure that compromises venous outflow. In 50% to 80% of cases, acute appendicitis is associated with overt luminal obstruction, usually by a small, stone-like mass of stool, or **fecalith**, or, less commonly, a gallstone,



tumor, or mass of worms. Ischemic injury and stasis of



luminal contents, which favor bacterial proliferation, trigger inflammatory responses including tissue edema and neutrophilic infiltration of the lumen, muscular wall, and periappendiceal soft tissues.

## MORPHOLOGY

In early acute appendicitis, subserosal vessels are congested, and a modest perivascular neutrophilic infiltrate is present within all layers of the wall. The inflammatory reaction transforms the normal glistening serosa into a dull, granular-appearing, erythematous surface. Although mucosal neutrophils and focal superficial ulceration often are present, these findings are not specific, and diagnosis of acute appendicitis requires neutrophilic infiltration of the muscularis propria. In more severe cases, focal abscesses may form within the wall (**acute suppurative appendicitis**), and these may even progress to large areas of hemorrhagic ulceration and gangrenous necrosis that extend to the serosa, creating **acute gangrenous appendicitis**, which often is followed by rupture and suppurative peritonitis.

### Clinical Features

Typically, early acute appendicitis produces periumbilical pain that ultimately localizes to the right lower quadrant, followed by nausea, vomiting, low-grade fever, and a mildly elevated peripheral white cell count. A classic physical finding is *McBurney's sign*, deep tenderness noted at a location two thirds of the distance from the umbilicus to the right anterior superior iliac spine (McBurney's point). These signs and symptoms often are absent, however, creating difficulty in clinical diagnosis.

## TUMORS OF THE APPENDIX

The most common tumor of the appendix is the *carcinoid*. It usually is discovered incidentally at the time of surgery or on examination of a resected appendix. This neoplasm most frequently involves the distal tip of the appendix, where it produces a solid bulbous swelling up to 2 to 3 cm in diameter. Although intramural and transmural extension may be evident, nodal metastases are very infrequent, and distant spread is exceptionally rare. Conventional *adenomas* or *non-mucin-producing adenocarcinomas* also occur in the appendix and may cause obstruction and enlargement that mimics the changes of acute appendicitis. *Mucocele*, a dilated appendix filled with mucin, may simply stem from an obstructed appendix containing inspissated mucin or may be a consequence of *mucinous cystadenoma* or *mucinous cystadenocarcinoma*. In the latter instance, invasion through the appendiceal wall can lead to intraperitoneal seeding and spread. In women, the resulting peritoneal implants may be mistaken for mucinous ovarian tumors. In the most advanced cases, the abdomen fills with tenacious, semi-solid mucin, a condition called *pseudomyxoma peritonei*. This disseminated intraperitoneal disease may be held in check for years by repeated debulking but in most instances is ultimately fatal.

## SUMMARY

### Appendix

- *Acute appendicitis* is most common in children and adolescents. It is thought to be initiated by increased intraluminal pressure consequent to obstruction of the appendiceal lumen, which compromises venous outflow.
- The most common tumor of the appendix is the *carcinoid*.
- The clinical presentation with *appendiceal adenocarcinoma* can be indistinguishable from that with acute appendicitis.

## BIBLIOGRAPHY

### ORAL CAVITY

- Hennessey PT, Westra WH, Califano JA: Human papillomavirus and head and neck squamous cell carcinoma: recent evidence and clinical implications. *J Dent Res* 88:300, 2009. [Discussion of head and neck cancers associated with HPV.]
- Leemans CR, Braakhuis BJ, Brakenhoff RH: The molecular biology of head and neck cancer. *Nat Rev Cancer* 11:9, 2011. [An up to date discussion of the molecular biology of head and neck cancer.]
- Leivo I: Insights into a complex group of neoplastic disease: advances in histopathologic classification and molecular pathology of salivary gland cancer. *Acta Oncol* 45:662, 2006. [A good review of the histologic spectrum of salivary gland tumors.]

### ESOPHAGUS

- Liacouras CA, Furuta GT, Hirano I, et al: Eosinophilic esophagitis: updated consensus recommendations for children and adults. *J Allergy Clin Immunol* 128:3, 2011. [The most current diagnostic definition of and therapeutic recommendations for eosinophilic esophagitis.]
- Sharma P: Clinical practice. Barrett's esophagus. *N Engl J Med* 361:2548, 2009. [A comprehensive discussion of Barrett esophagus.]

### INFLAMMATORY DISEASE OF THE STOMACH

- Malferteiner P, Chan FK, McColl KE: Peptic ulcer disease. *Lancet* 374:1449, 2009. [Summary of current understanding of peptic ulcer disease.]
- Mills JC, Shivdasani RA: Gastric epithelial stem cells. *Gastroenterology* 140:412, 2011. [A good discussion of cell lineages and differentiation pathways in the gastric epithelium.]
- Polk DB, Peek RM, Jr: *Helicobacter pylori*: gastric cancer and beyond. *Nat Rev Cancer* 10:403, 2010. [A good review of H. pylori and mechanisms by which it is linked to gastric cancer.]

### NEOPLASTIC DISEASE OF THE STOMACH

- Murphy G, Pfeiffer R, Camargo MC, Rabkin CS: Meta-analysis shows that prevalence of Epstein-Barr virus-positive gastric cancer differs based on sex and anatomic location. *Gastroenterology* 137:824, 2009. [A meta-analysis of over 15,000 gastric cancer cases tested for EBV RNA.]
- Polk DB, Peek RM Jr: *Helicobacter pylori*: gastric cancer and beyond. *Nat Rev Cancer* 10:403, 2010. [A good review of H. pylori and mechanisms by which it is linked to gastric cancer.]
- Sagaert X, Van Cutsem E, De Hertogh G, et al: Gastric MALT lymphoma: a model of chronic inflammation-induced tumor development. *Nat Rev Gastroenterol Hepatol* 7:336, 2010. [A discussion of gastric MALT lymphoma pathogenesis.]

### INTESTINAL OBSTRUCTION

- Kapur RP: Practical pathology and genetics of Hirschsprung's disease. *Semin Pediatr Surg* 18:212, 2009. [A review of Hirschsprung disease etiology and diagnosis.]





Muysoms FE, Miserez M, Berrevoet F, et al: Classification of primary and incisional abdominal wall hernias. *Hernia* 13:407, 2009. [An explanation of abdominal hernia classification.]

### VASCULAR DISORDERS

Barnert J, Messmann H: Diagnosis and management of lower gastro- intestinal bleeding. *Nat Rev Gastroenterol Hepatol* 6:637, 2009. [A good discussion of clinical approaches to lower GI bleeding.]

Colgan SP, Taylor CT: Hypoxia: an alarm signal during intestinal inflammation. *Nat Rev Gastroenterol Hepatol* 7:281, 2010. [A review of signaling events activated by intestinal hypoxia.]

Sneider EB, Maykel JA: Diagnosis and management of symptomatic hemorrhoids. *Surg Clin North Am* 90:17, 2010. [A clinically oriented review of hemorrhoids.]

### MALABSORPTIVE DIARRHEA

Khan S, Chang L: Diagnosis and management of IBS. *Nat Rev Gastro- enterol Hepatol* 7:565, 2010. [A recent review of IBS.]

Moore SR, Lima NL, Soares AM, et al: Prolonged episodes of acute diarrhea reduce growth and increase risk of persistent diarrhea in children. *Gastroenterology* 139:1156, 2010. [A detailed study of envi- ronmental enteropathy.]

Pardi DS, Kelly CP: Microscopic colitis. *Gastroenterology* 140:1155, 2011. [A review of collagenous and lymphocytic colitis.]

Schuppan D, Junker Y, Barisani D: Celiac disease: from pathogenesis to novel therapies. *Gastroenterology* 137:1912, 2009. [A recent review of celiac disease.]

Suchy FJ, Brannon PM, Carpenter TO, et al: National Institutes of Health Consensus Development Conference: lactose intolerance and health. *Ann Intern Med* 152:792, 2010. [A consensus conference on lactose intolerance.]

### INFECTIOUS ENTEROCOLITIS

Barton Behravesh C, Mody RK, Jungk J, et al: 2008 outbreak of *Salmo- nella* Saintpaul infections associated with raw produce. *N Engl J Med* 364:918, 2011. [Analysis of a Salmonella epidemic.]

John TJ, Dandona L, Sharma VP, Kakkar M: Continuing challenge of infectious diseases in India. *Lancet* 377:252, 2011. [Review of enteric infections in India.]

Kirkpatrick BD, Tribble DR: Update on human *Campylobacter jejuni* infections. *Curr Opin Gastroenterol* 27:1, 2011. [Recent verview of Campylobacter gastroenteritis.]

Kuehne SA, Cartman ST, Heap JT, et al: The role of toxin A and toxin B in *Clostridium difficile* infection. *Nature* 467:711, 2010. [A detailed analysis of toxin function in C. difficile pathogenesis.]

Navaneethan U, Giannella RA: Infectious colitis. *Curr Opin Gastroen- terol* 27:66, 2011. [Good overview of infectious colitis.]

Prince Christopher RH, David KV, John SM, Sankarapandian V: Anti- biotic therapy for *Shigella* dysentery. *Cochrane Database Syst Rev* 1:CD006784, 2010. [A meta-analysis of antibiotic effectiveness in dysentery.]

van Lieshout L, Verweij JJ: Newer diagnostic approaches to intestinal protozoa. *Curr Opin Infect Dis* 23:488, 2010. [Recent review of evolving diagnostic tools.]

### SIGMOID DIVERTICULITIS

Eglinton T, Nguyen T, Raniga S, et al: Patterns of recurrence in patients with acute diverticulitis. *Br J Surg* 97:952, 2010. [Evaluation of outcome following acute episodes of diverticulitis.]

Hall J, Hammerich K, Roberts P: New paradigms in the management of diverticular disease. *Curr Probl Surg* 47:680, 2010. [A recent review of approaches to diverticulosis and diverticulitis management.]

**INFLAMMATORY BOWEL DISEASE**

- Abraham C, Cho JH: Inflammatory bowel disease. *N Engl J Med* 361:2066, 2009. [A complete review of IBD mechanisms and genomics.]
- Glocker EO, Kotlarz D, Boztug K, et al: Inflammatory bowel disease and mutations affecting the interleukin-10 receptor. *N Engl J Med* 361:2033, 2009. [Identification of IL-10 receptor mutations in a subset of ulcerative colitis patients.]
- Goel GA, Kandiel A, Achkar JP, Lashner B: Molecular pathways underlying IBD-associated colorectal neoplasia: therapeutic implications. *Am J Gastroenterol* 106:719, 2011. [A good review of colitis-associated cancer.]
- Kaser A, Zeissig S, Blumberg RS: Inflammatory bowel disease. *Annu Rev Immunol* 28:573, 2010. [A review of immune mechanisms in IBD.]
- Marchiando AM, Graham WV, Turner JR: Epithelial barriers in homeostasis and disease. *Annu Rev Pathol* 5:119, 2010. [A review of intestinal epithelial barrier function and its implications in IBD and other disorders.]
- Molodecky NA, Panaccione R, Ghosh S, et al: Challenges associated with identifying the environmental determinants of the inflammatory bowel diseases. *Inflamm Bowel Dis* 17:1792, 2011. [A good discussion of environmental IBD triggers.]
- Turner JR: Intestinal mucosal barrier function in health and disease. *Nat Rev Immunol* 9:799, 2009. [An analysis of epithelial-immune interactions in gastrointestinal disease.]

**COLONIC POLYPS AND NEOPLASTIC DISEASE**

- Beggs AD, Latchford AR, Vasen HF, et al: Peutz-Jeghers syndrome: a systematic review and recommendations for management. *Gut* 59:975, 2010. [A review of Peutz-Jeghers disease etiology and management.]
- Boland CR, Goel A: Microsatellite instability in colorectal cancer. *Gastroenterology* 138:2073, 2010. [A discussion of the microsatellite instability pathway of colon cancer.]
- Hardwick JC, Kodach LL, Offerhaus GJ, van den Brink GR: Bone morphogenetic protein signalling in colorectal cancer. *Nat Rev Cancer* 8:806, 2008. [A good review of signaling pathways in colon cancer.]
- Jasperson KW, Tuohy TM, Neklason DW, Burt RW: Hereditary and familial colon cancer. *Gastroenterology* 138:2044, 2010. [A comprehensive review of colon cancer syndromes.]
- Jass JR: Colorectal polyposis: from phenotype to diagnosis. *Pathol Res Pract* 204:431, 2008. [A morphology-focused review of polyposis syndromes.]
- Noffsinger AE: Serrated polyps and colorectal cancer: new pathway to malignancy. *Annu Rev Pathol* 4:343, 2009. [A detailed review of sessile serrated adenomas and the mechanisms by which they develop and progress.]
- Pino MS, Chung DC: The chromosomal instability pathway in colon cancer. *Gastroenterology* 138:2059, 2010. [A review of colon cancer genetics.]

**APPENDIX**

- Cartwright SL, Knudson MP: Evaluation of acute abdominal pain in adults. *Am Fam Physician* 77:971, 2008. [A clinically oriented approach to the acute abdomen.]
- Deschamps L, Couvelard A: Endocrine tumors of the appendix: a pathologic review. *Arch Pathol Lab Med* 134:871, 2010. [A pathology-focused review of appendiceal carcinoid tumors.]
- Tang LH: Epithelial neoplasms of the appendix. *Arch Pathol Lab Med* 134: