Central Nervous System

Dr. Gary Mumaugh

COVERINGS OF THE BRAIN AND SPINAL CORD

- Two protective coverings
  - Outer covering is bone; cranial bones encase the brain and vertebrae encase the spinal cord
  - Inner covering is the meninges; the meninges of the cord continue inside the spinal cavity beyond the end of the spinal cord

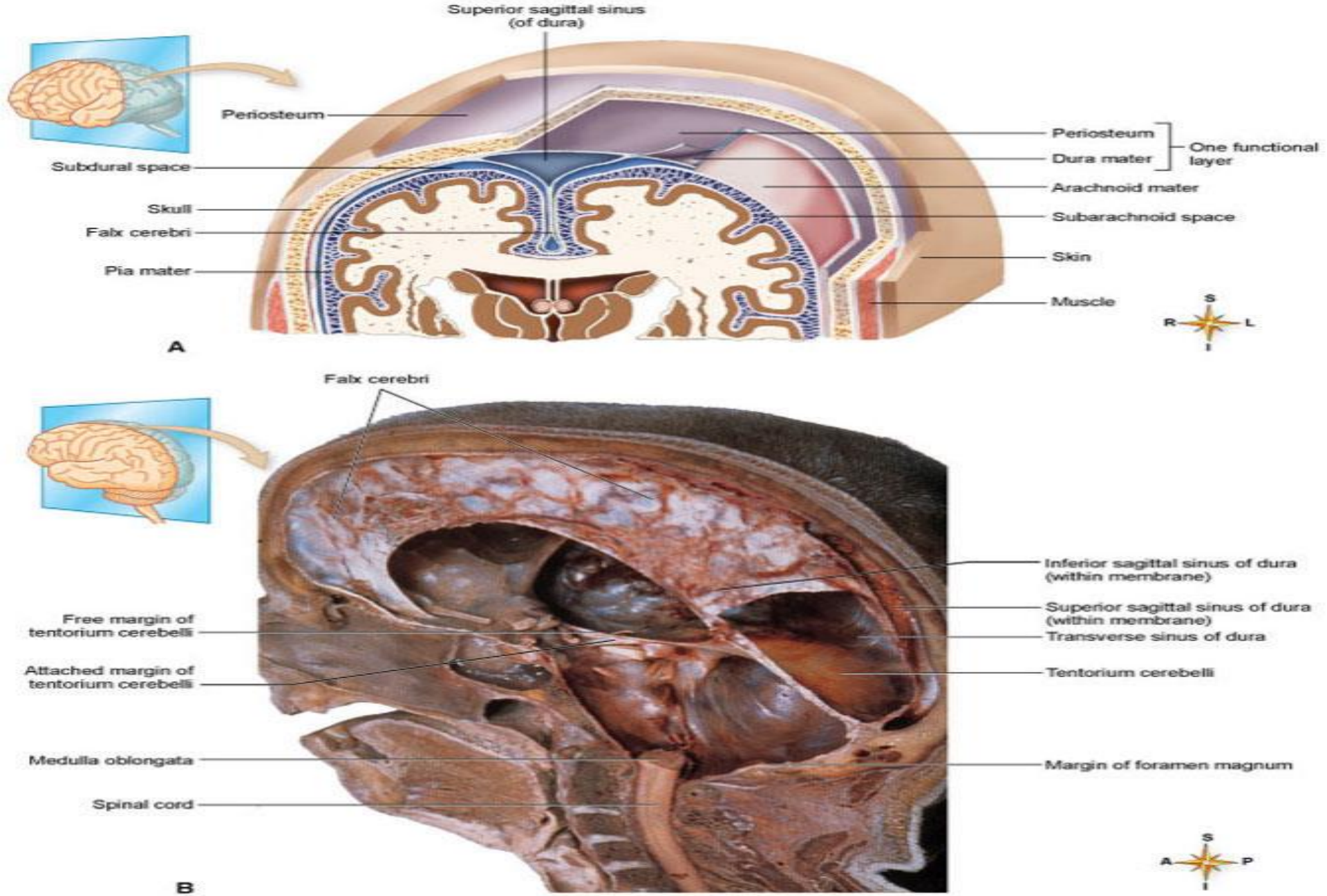

B: From Abrahams P, Marks S, Hutchings R: *McMinn's color atlas of human anatomy*, ed 5, Philadelphia, 2003, Mosby.

Fig. 13-2. **Coverings of the brain. A,** Frontal section of the superior portion of the head, as viewed from the front. Both the bony and the membranous coverings of the brain can be seen. **B,** Sagittal section of the skull, viewed from the left. The dura mater has been retained in this specimen to show how it lines the inner roof of the cranium and the falx cerebri extending inward.

Meninges of Vertebra and Spinal Cord

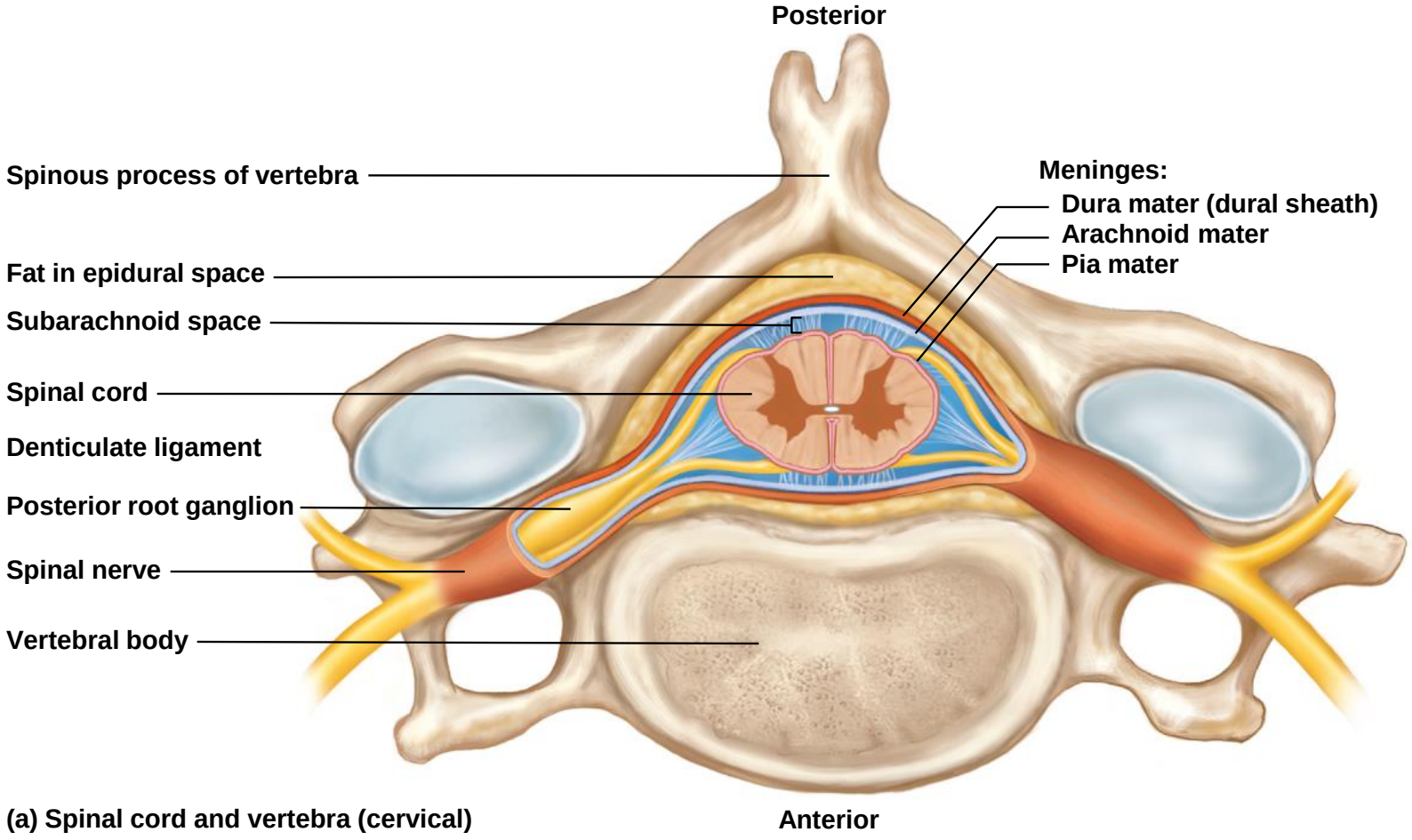

(a) Spinal cord and vertebra (cervical)

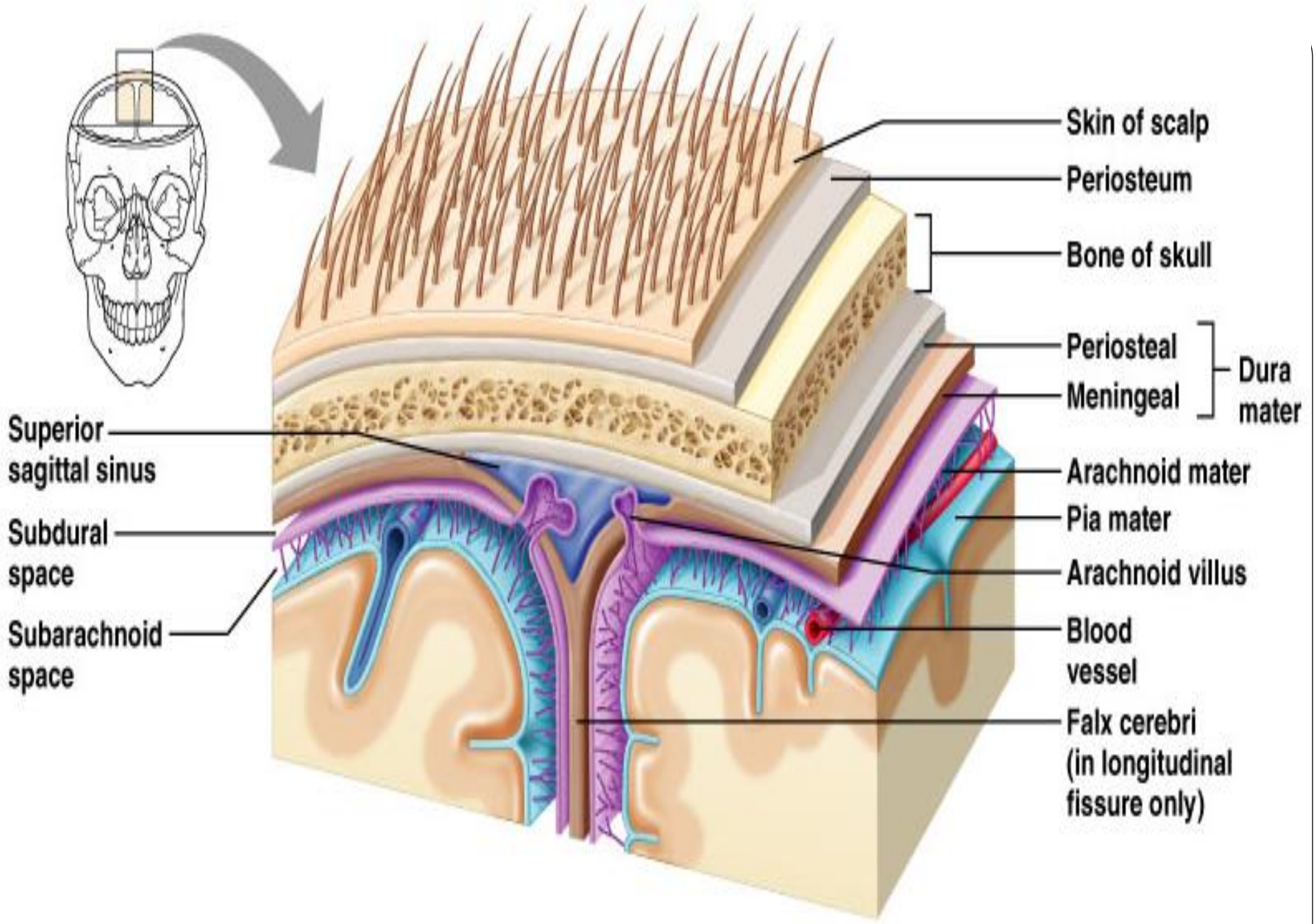
Skin of scalp
Periosteum
Bone of skull
Periosteal
Meningeal
Dura mater
Superior sagittal sinus
Subdural space
Subarachnoid space
Arachnoid mater
Pia mater
Arachnoid villus
Blood vessel
Falx cerebri (in longitudinal fissure only)

(a)

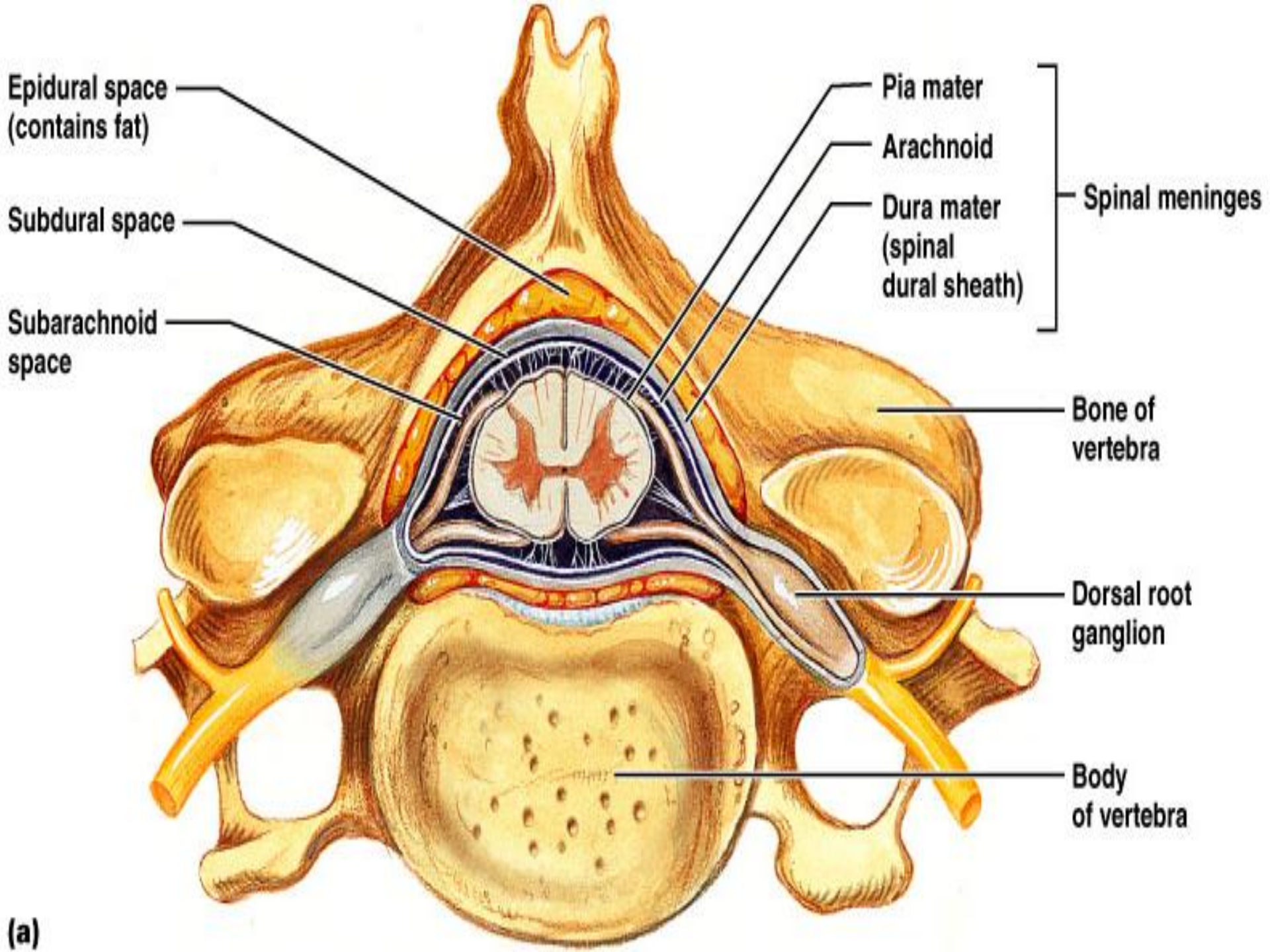
Epidural space
(contains fat)
Subdural space
Subarachnoid
space
Pia mater
Arachnoid
Dura mater
(spinal
dural sheath)
Spinal meninges
Bone of
vertebra
Dorsal root
ganglion
Body
of vertebra
(a)

COVERINGS OF THE BRAIN AND SPINAL CORD: MENINGES

- Meninges have three membranous layers
  - Dura mater: strong, white, fibrous tissue; outer layer of meninges and inner periosteum of the cranial bones; has three important extensions
    - Falx cerebri
      - Projects downward into the longitudinal fissure between the two cerebral hemispheres
      - Dural sinuses: function as veins, collecting blood from brain tissues for return to the heart
      - Superior sagittal sinus—one of several dural sinuses
    - Falx cerebelli: separates the two hemispheres of the cerebellum
    - Tentorium cerebelli: separates the cerebellum from the cerebrum

Dura Mater

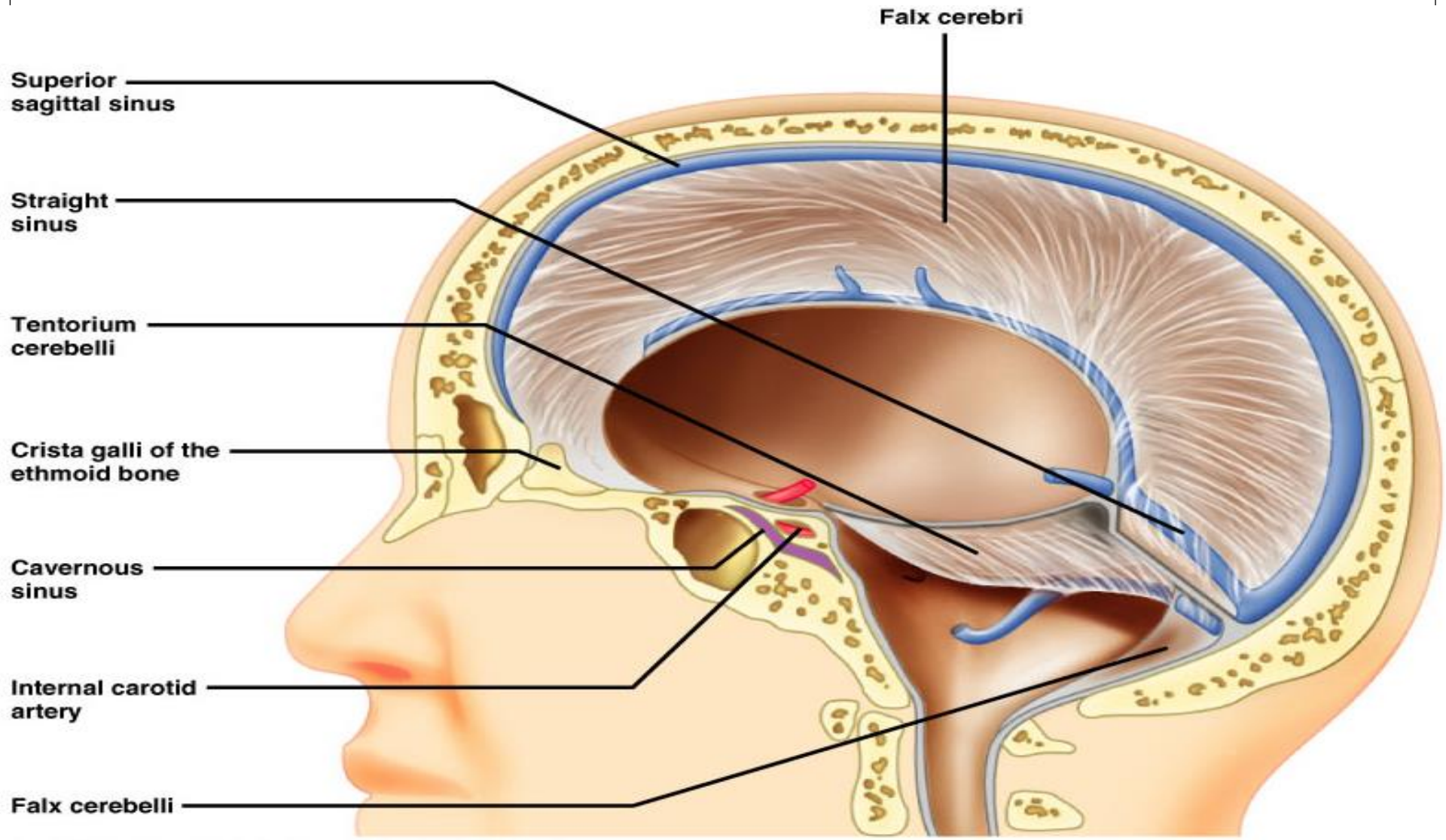
Falx cerebri
Superior sagittal sinus
Straight sinus
Tentorium cerebelli
Crista galli of the ethmoid bone
Cavernous sinus
Internal carotid artery
Falx cerebelli

COVERINGS OF THE BRAIN AND SPINAL CORD: MENINGES

- Meninges have three membranous layers
  - Arachnoid mater: delicate, cobweblike layer between the dura mater and pia mater
  - Pia mater: innermost, transparent layer; adheres to the outer surface of the brain and spinal cord; contains blood vessels; beyond the spinal cord, forms a slender filament called *filum terminale;* at level of sacrum, blends with dura mater to form a fibrous cord that disappears into the periosteum of the coccyx

Spaces Between The Meninges

- Epidural space
  - Between the dura mater and inside the bony covering of the spinal cord; contains a supporting cushion of fat and other connective tissues
- Subdural space
  - Located between the dura mater and arachnoid mater; contains lubricating serous fluid
- Subarachnoid space
  - Between the arachnoid and pia mater; contains a significant amount of cerebrospinal fluid (CSF)

Cerebral Spinal Fluid

- CSF continually flows through and around the CNS
  - driven by its own pressure, beating of ependymal cilia, and pulsations of the brain produced by each heartbeat
- cerebrospinal fluid (CSF) – clear, colorless liquid that fills the ventricles and canals of CNS
- brain produces and absorbs 500 mL/day
  - 100 – 160 mL normally present at one time
- production begins with the filtration of blood plasma through the capillaries of the brain

Functions of CSF

- Buoyancy
  - allows brain to attain considerable size without being impaired by its own weight
  - if it rested heavily on floor of cranium, the pressure would kill the nervous tissue
- Protection
  - protects the brain from striking the cranium when the head is jolted
  - shaken child syndrome and concussions do occur from severe jolting
- Chemical stability
  - flow of CSF rinses away metabolic wastes from nervous tissue and homeostatically regulates its chemical environment
- Nutrition to cord

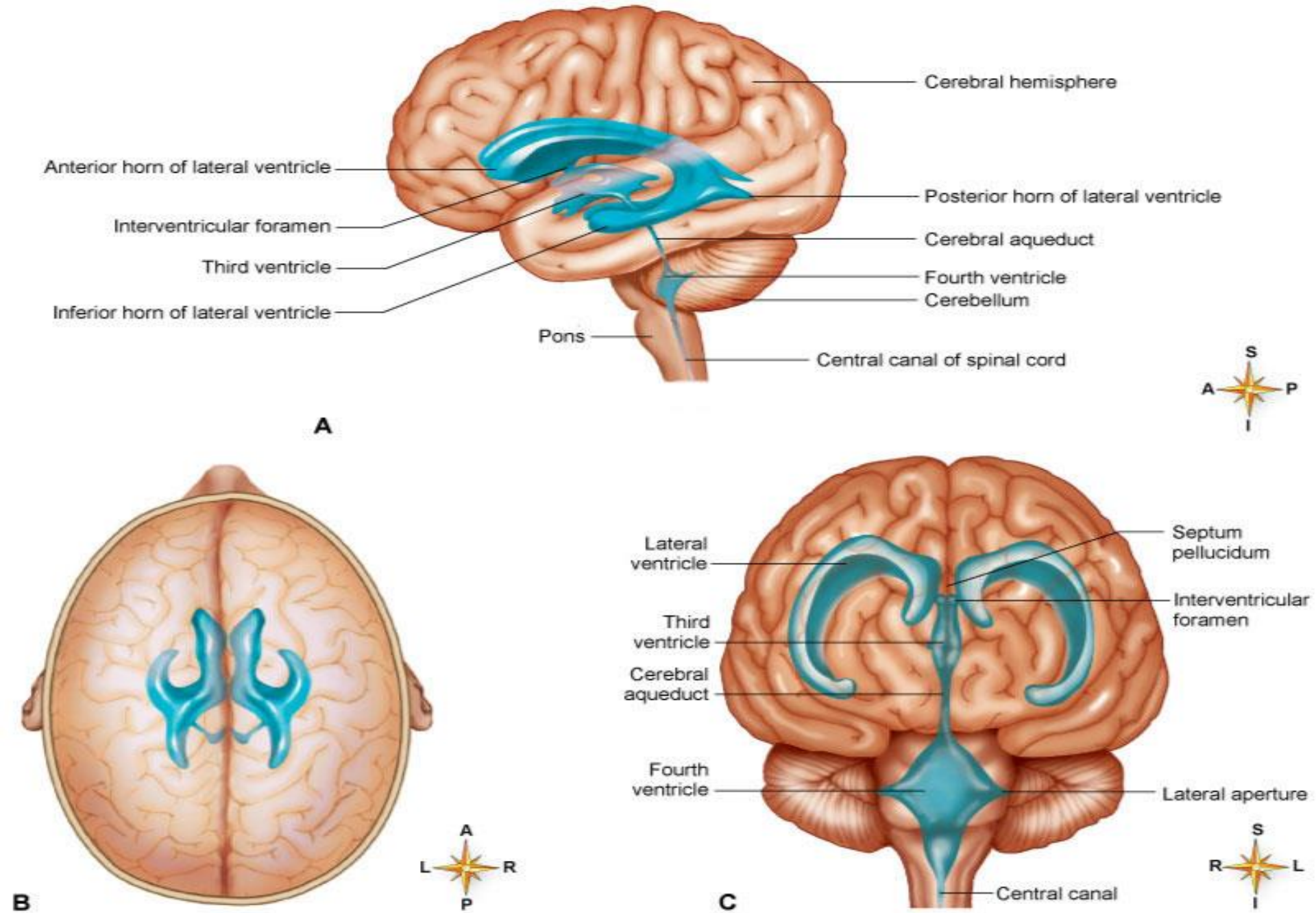

Fig. 13-4. **Fluid spaces of the brain. A,** Ventricles highlighted in blue within a translucent brain in a left lateral view. **B,** Ventricles as seen from above. **C,** Ventricles as seen from the front.

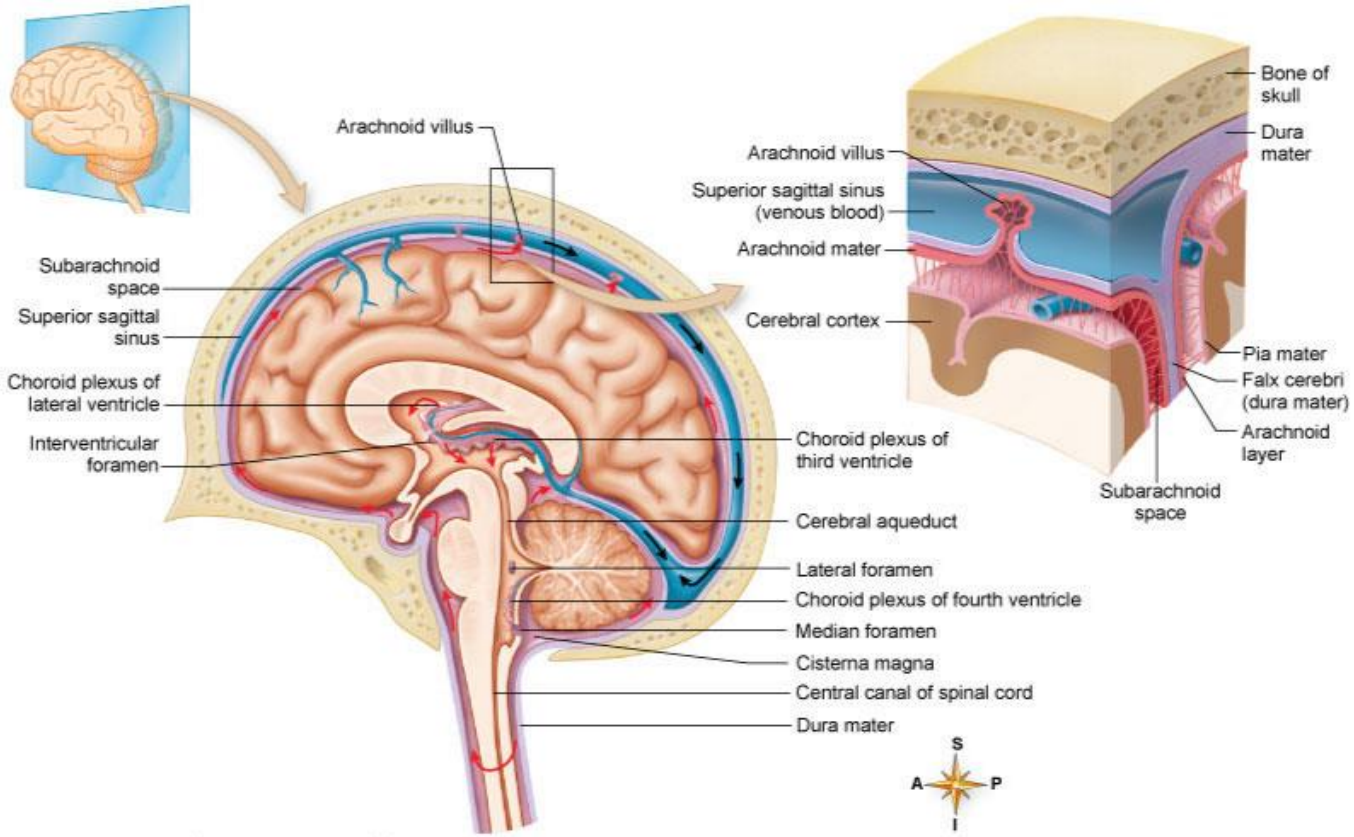

Fig. 13-5. **Flow of cerebrospinal fluid.** The fluid produced by filtration of blood by the choroid plexus of each ventricle flows inferiorly through the lateral ventricles, interventricular foramen, third ventricle, cerebral aqueduct, fourth ventricle, and subarachnoid space and to the blood.

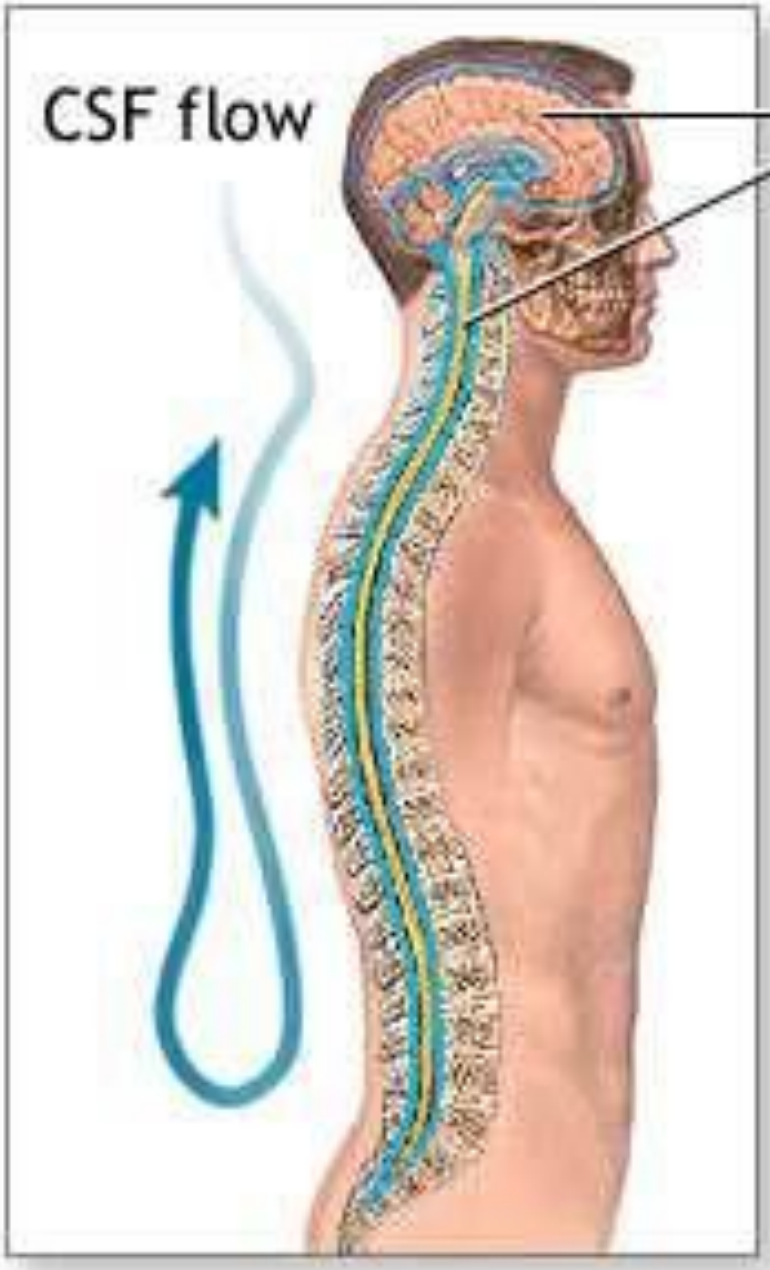

Central nervous system (CNS)

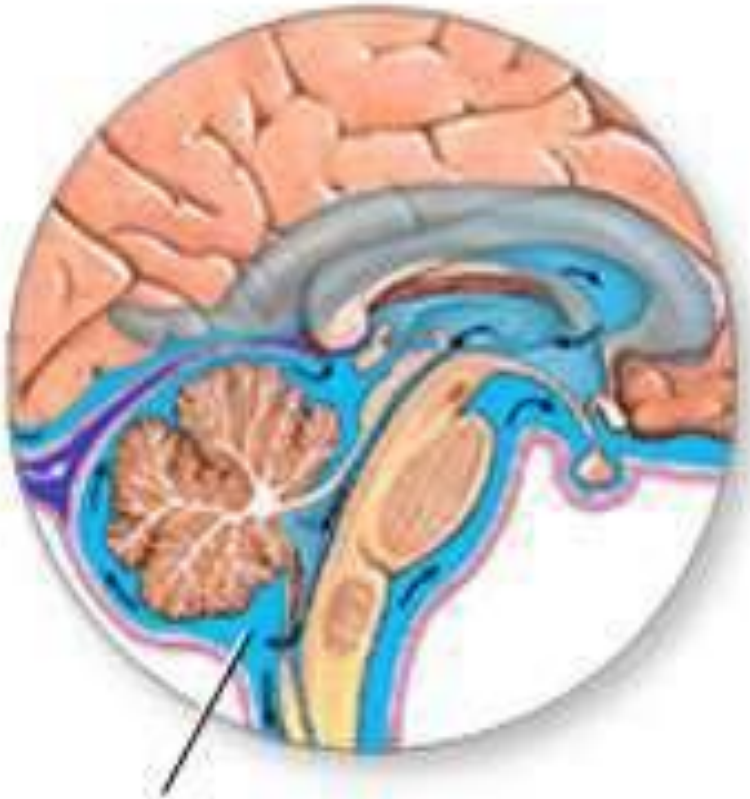

Cerebrospinal fluid (CSF)

SPINAL CORD

- Structure of the spinal cord
  - Lies within the spinal cavity and extends from the foramen magnum to the lower border of the first lumbar vertebra
  - Oval-shaped cylinder that tapers slightly from above downward
  - Two bulges, one in the cervical region and one in the lumbar region

SPINAL CORD

- Nerve roots
  - Fibers of dorsal nerve root
    - Carry sensory information into the spinal canal
  - Fibers of ventral nerve root
    - Carry motor information out of the spinal cord

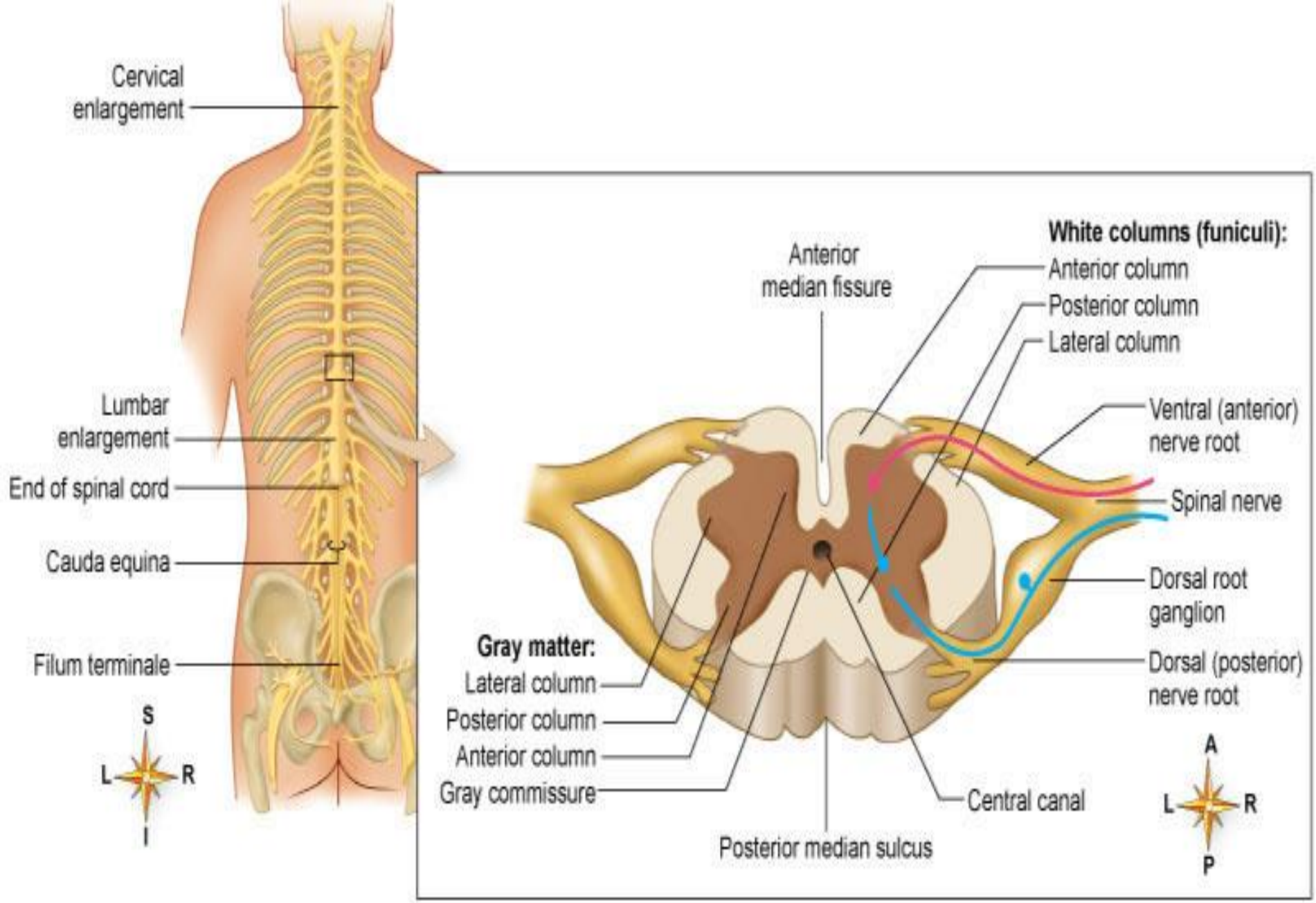

Fig. 13-6. **Spinal cord.** The inset illustrates a transverse section of the spinal cord shown in the broader view.

SPINAL CORD

- Interneurons are located in the spinal cord's gray matter core
- Spinal nerve: a single mixed nerve on each side of the spinal cord where the dorsal and ventral nerve roots join together
- Cauda equina: bundle of nerve roots extending (along with the filum terminale) from the conus medullaris (inferior end of spinal cord)

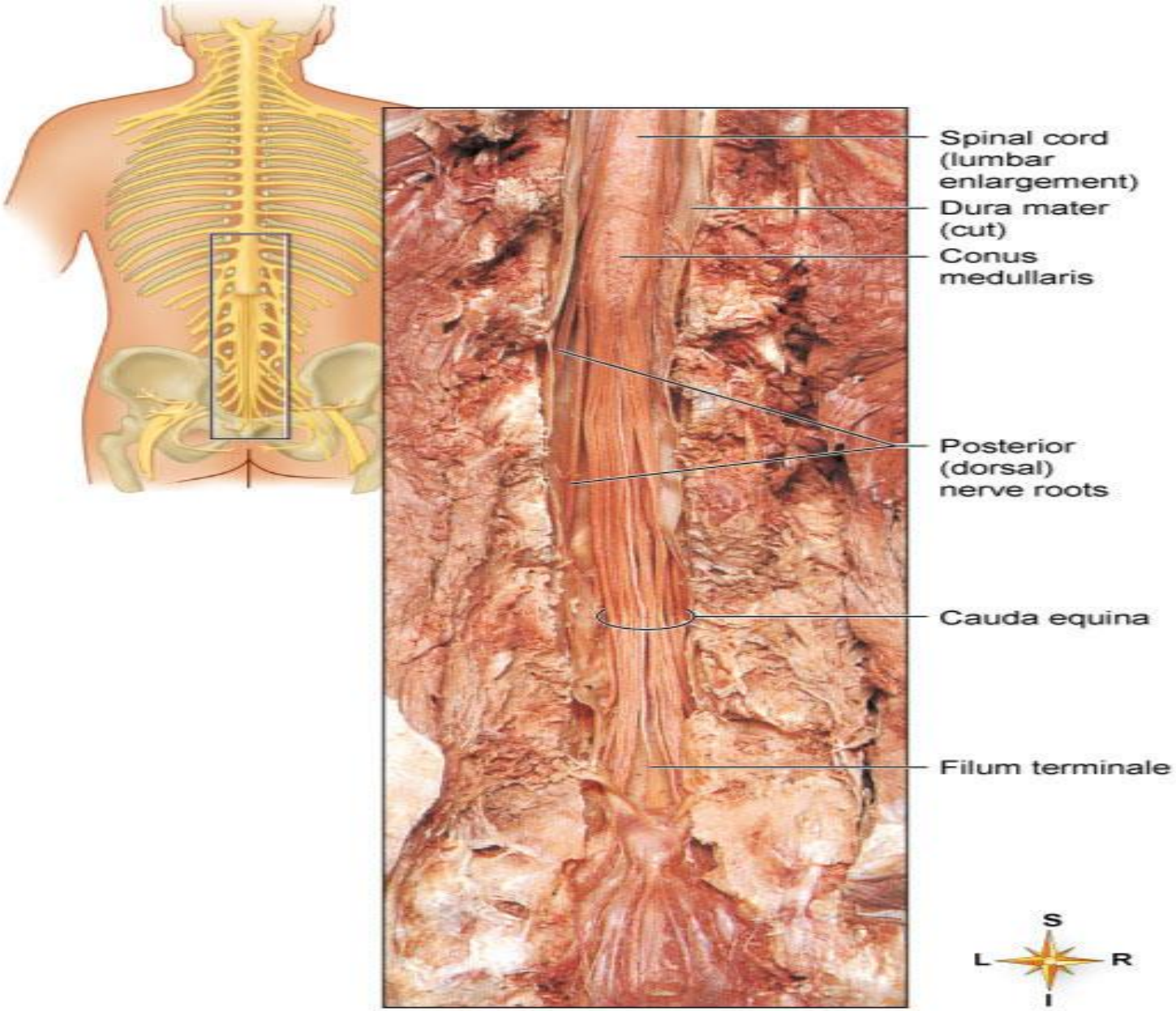

From Gosling J, Harris P, Whitmore I, Willan P: *Human anatomy*, ed 4, Philadelphia, 2002.

Fig. 13-7. **Cauda equina.** Photograph shows the inferior portion of the dura mater dissected posteriorly, revealing the cauda equine and nearby structures.

SPINAL CORD

- Gray matter
  - Columns of gray matter extend the length of the cord
  - Consists predominantly of cell bodies of interneurons and motor neurons
- White matter
  - Surrounds the gray matter and is subdivided in each half on the cord into three funiculi: anterior, posterior, and lateral white columns
  - Each funiculus consists of a large bundle of axons divided into tracts
  - Names of spinal tracts indicate the location of the tract, the structure in which the axons originate, and the structure in which they terminate

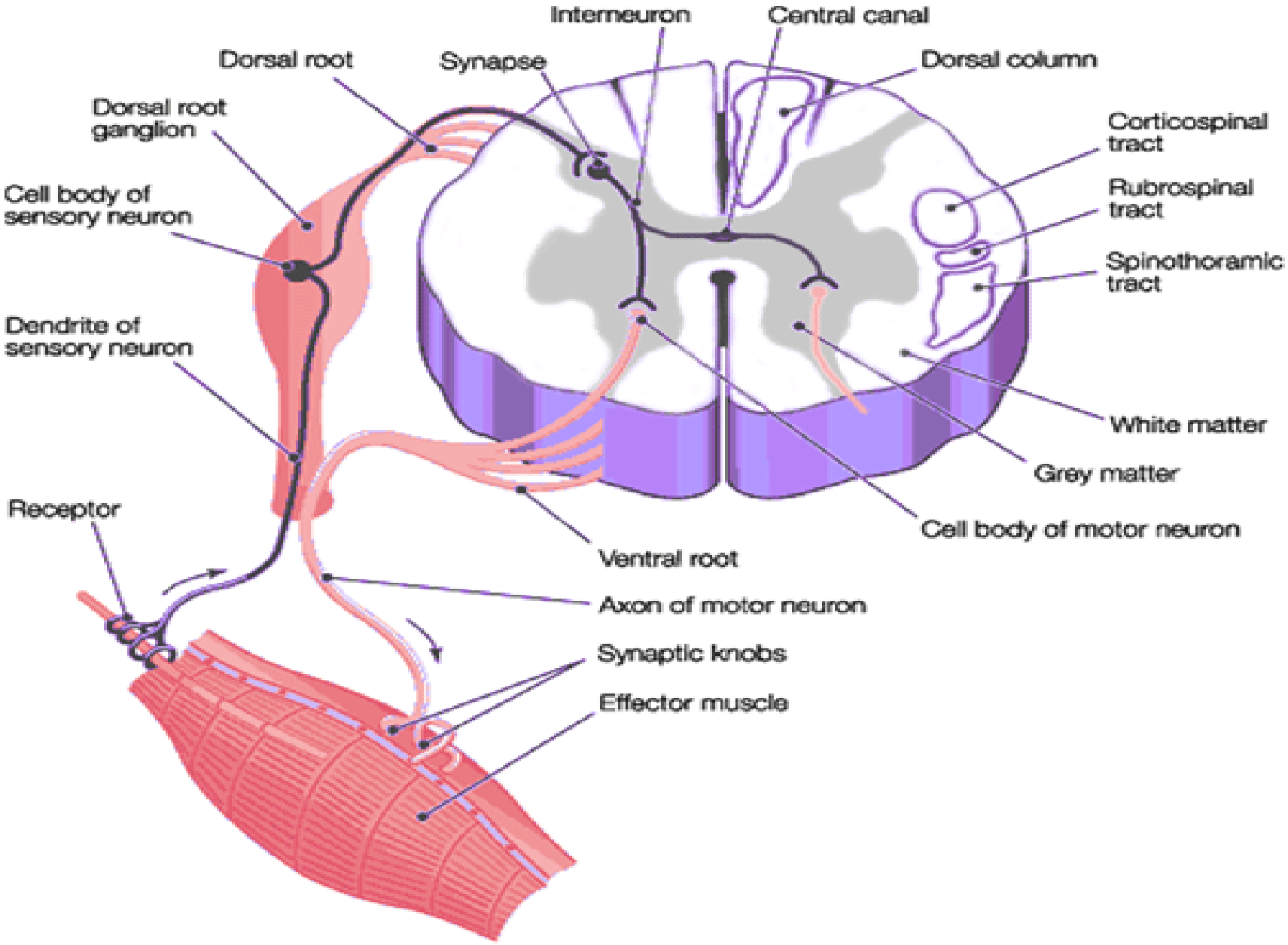
Interneuron
Central canal
Dorsal root
Synapse
Dorsal column
Dorsal root ganglion
Corticospinal tract
Cell body of sensory neuron
Rubrospinal tract
Spinothoramic tract
Dendrite of sensory neuron
White matter
Grey matter
Receptor
Cell body of motor neuron
Ventral root
Axon of motor neuron
Synaptic knobs
Effector muscle

Functions of the Spinal Cord

- Spinal cord: reflex center for all spinal reflexes, which are located in the gray matter of the cord
- Provides conduction routes to and from the brain
  - Ascending tracts conduct impulses up the cord to the brain
  - Descending tracts conduct impulses down the cord from the brain

- Important ascending (sensory) tracts
  - Lateral spinothalamic tracts: crude touch, pain, and temperature
  - Anterior spinothalamic tracts: crude touch, pressure
  - Fasciculi gracilis and cuneatus: discriminating touch and conscious kinesthesia
  - Spinocerebellar tracts: subconscious kinesthesia
  - Spinotectal: touch

- Important descending (motor) tracts
  - Lateral corticospinal tracts: voluntary movements on opposite side of the body
  - Anterior corticospinal tracts: voluntary movements on same side of body
  - Reticulospinal tracts: maintain posture during movement
  - Rubrospinal tracts: transmit impulses that coordinate body movements and maintenance of posture
  - Tectospinal tracts: head and neck movements during visual reflexes
  - Vestibulospinal tracts: coordination of posture and balance

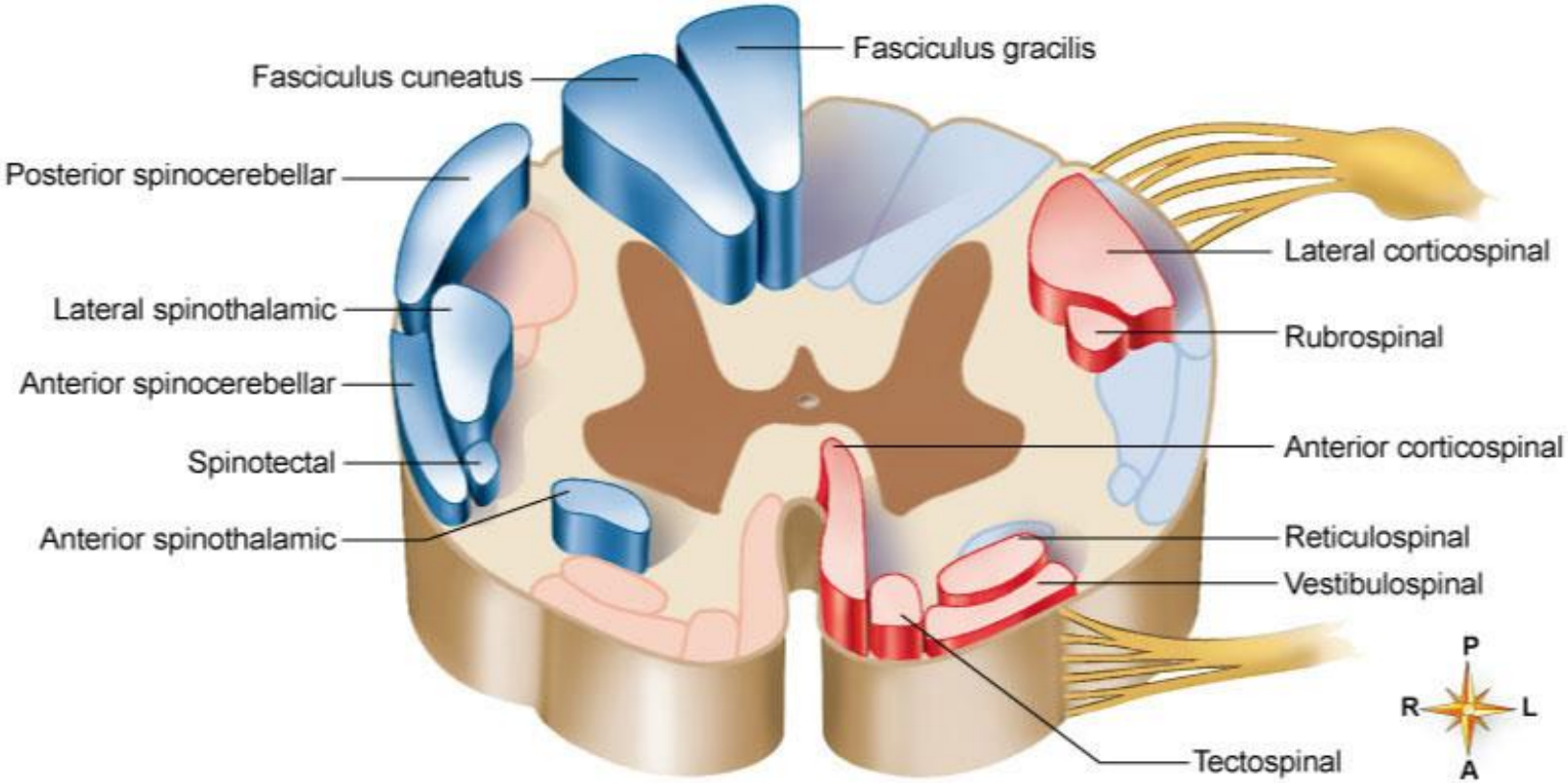

Fig. 13-8. **Major tracts of the spinal cord.** The major ascending (sensory) tracts are highlighted in blue. The major descending (motor) tracts are highlighted in red.

Review of Reflexes

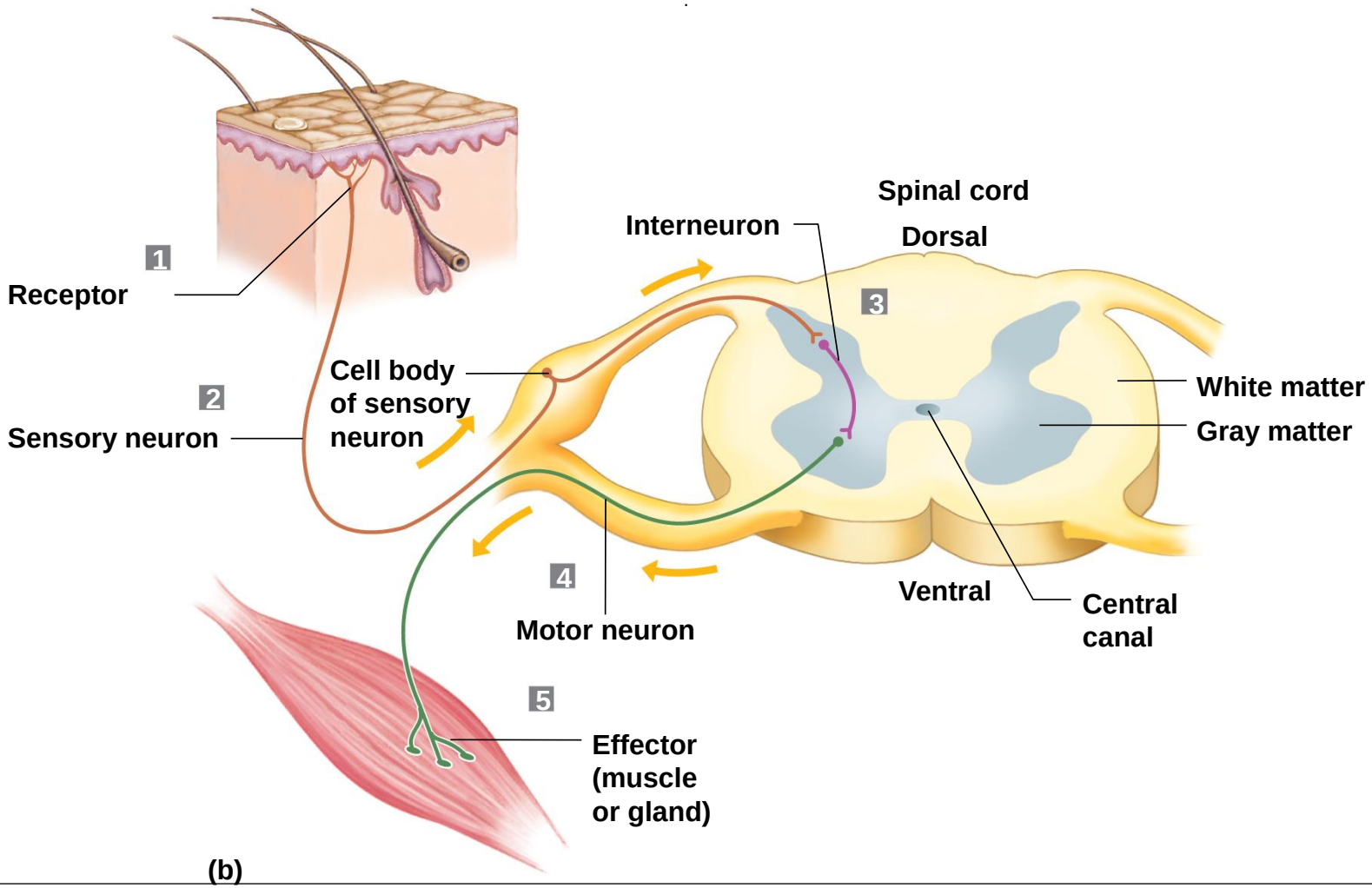

Reflex Behavior

Example is the *knee-jerk reflex*
Helps maintain an upright posture

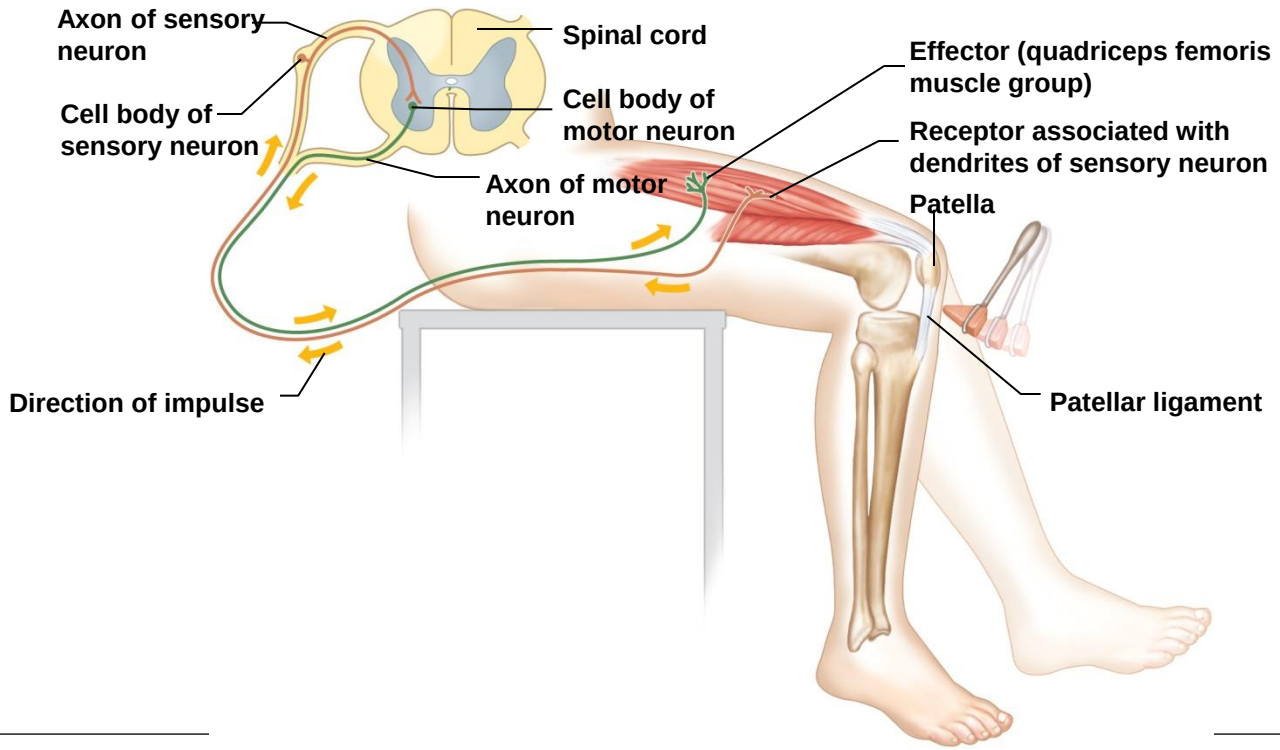

Example is a *withdrawal reflex* (flexor reflex)
Prevents or limits tissue damage

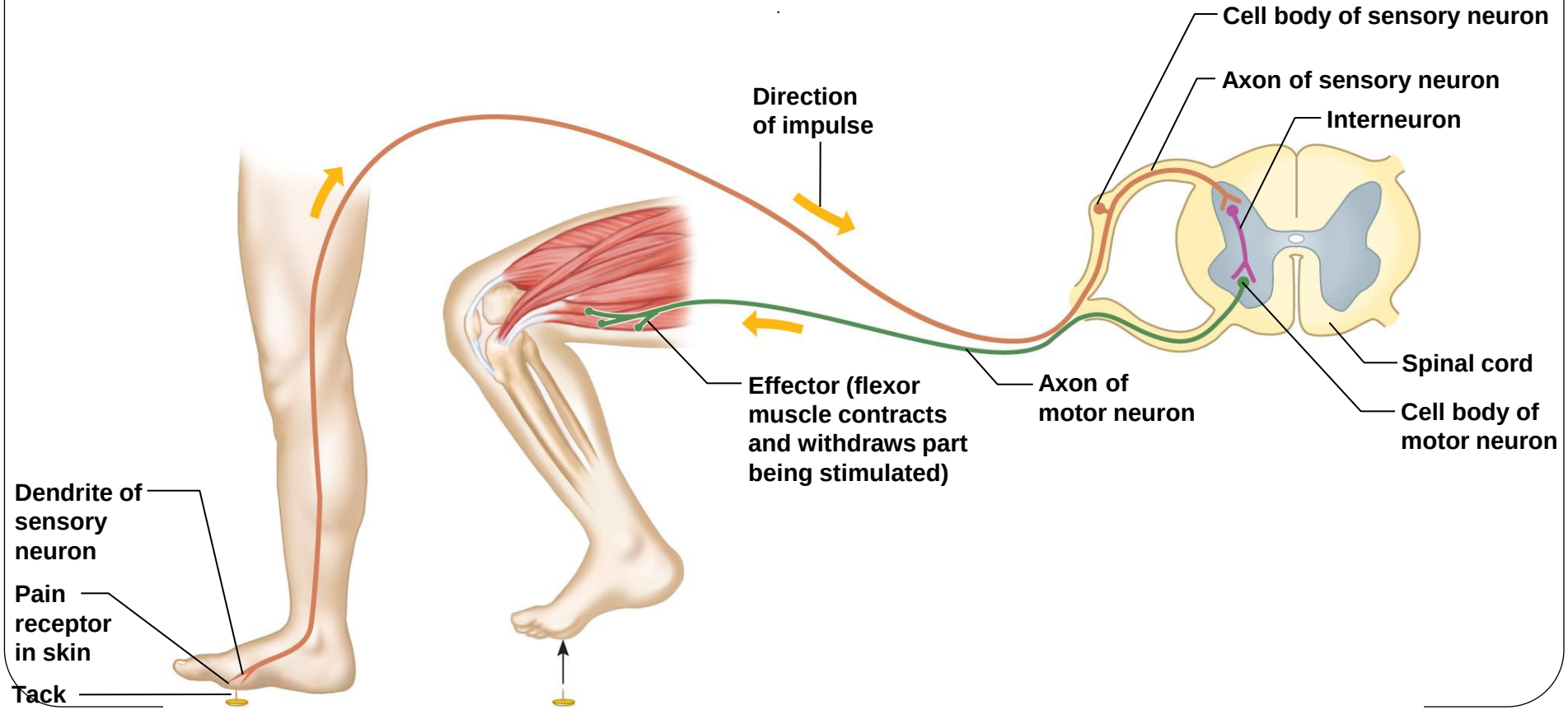

Example *crossed extensor reflex*

Crossing of sensory impulses within the reflex center to produce an opposite effect

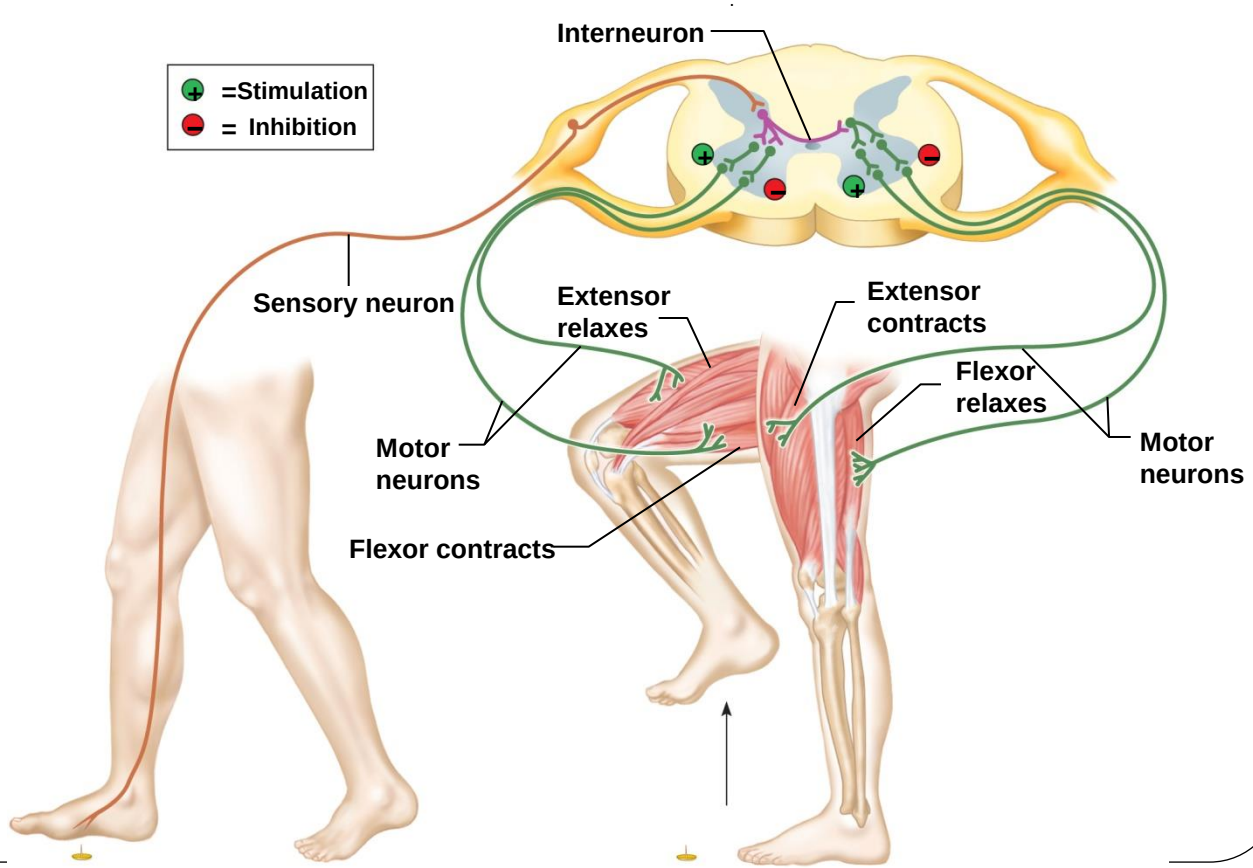

Directional Terms and Landmarks

- rostral - toward the forehead
- caudal - toward the spinal cord
- brain weighs about 1600 g (3.5 lb) in men, and 1450 g in women
- three major portions of the brain - cerebrum, cerebellum, brainstem

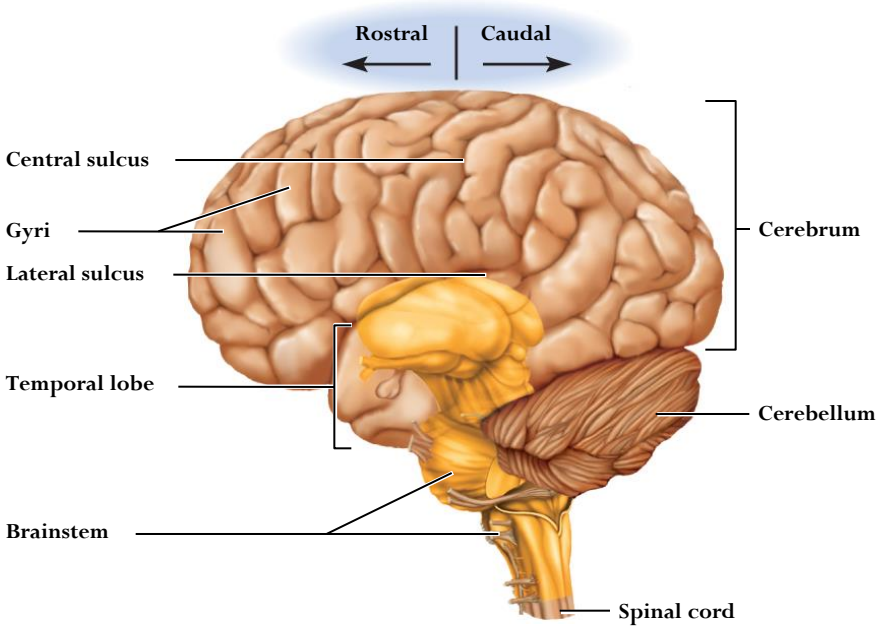

(b) Lateral view

Brain Functions

- Interprets sensations
- Determines perception
- Stores memory
- Reasoning
- Makes decisions
- Coordinates muscular movements
- Regulates visceral activities
- Determines personalities

Cerebrum

- 80-85% of brain volume
- longitudinal fissure – deep groove that separates cerebral hemispheres
- gyri - thick folds
- sulci - shallow grooves
- corpus callosum – thick nerve bundle at bottom of longitudinal fissure that connects hemispheres

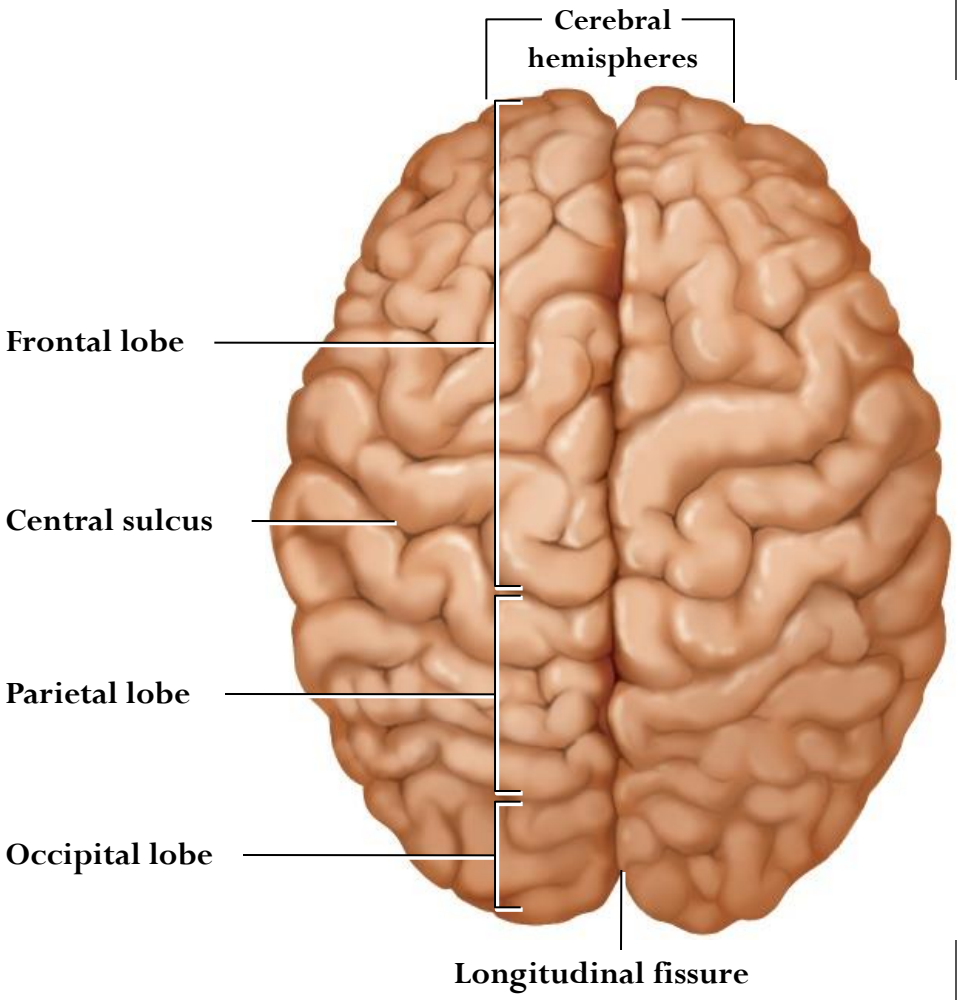

(a) Superior view

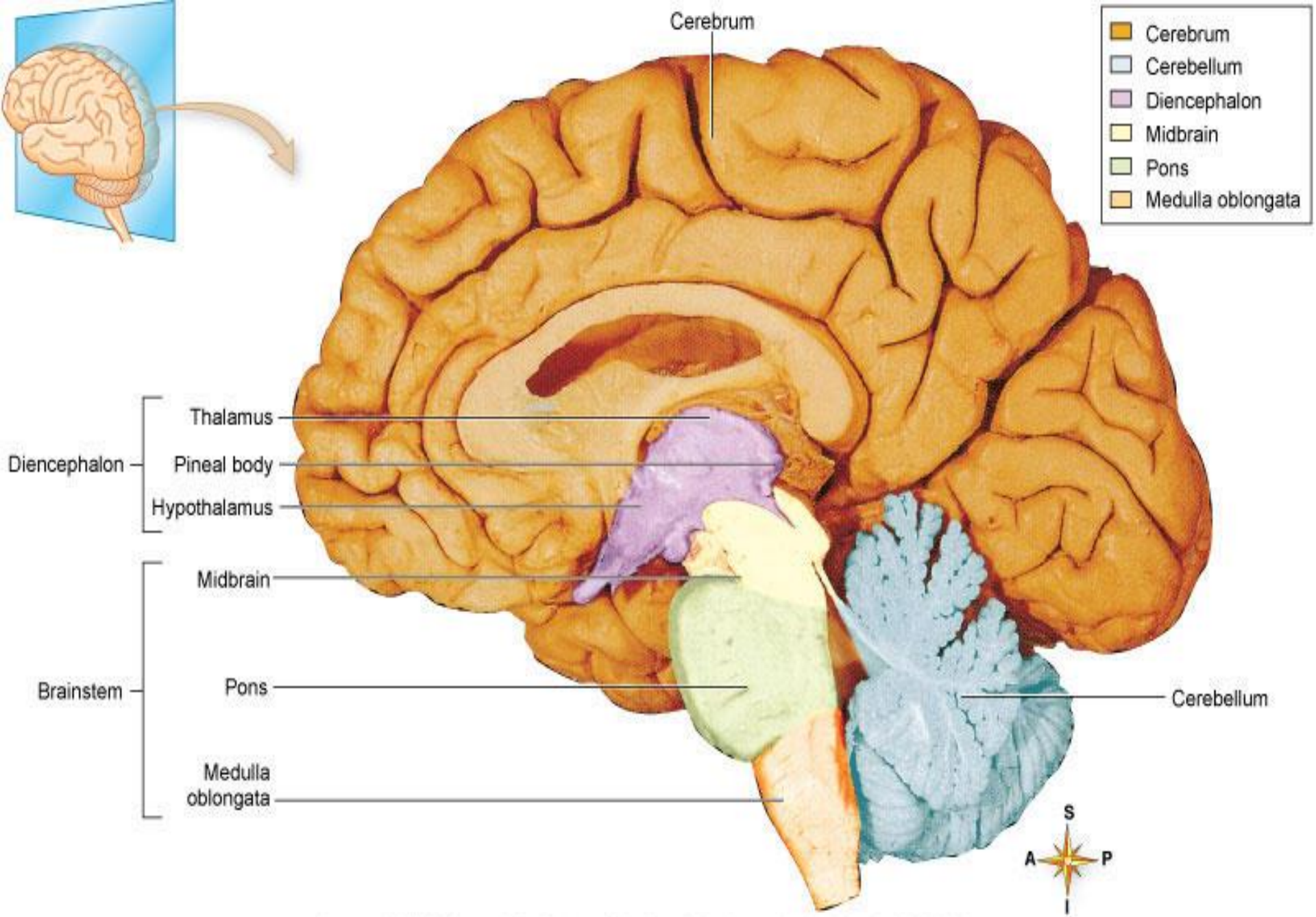

Courtesy Vidic B, Suarez FR: *Photographic atlas of the human body*, St Louis, 1984, Mosby.

Fig. 13-9. **Divisions of the brain.** A midsagittal section of the brain reveals features of its major divisions.

Internal structure of the brain

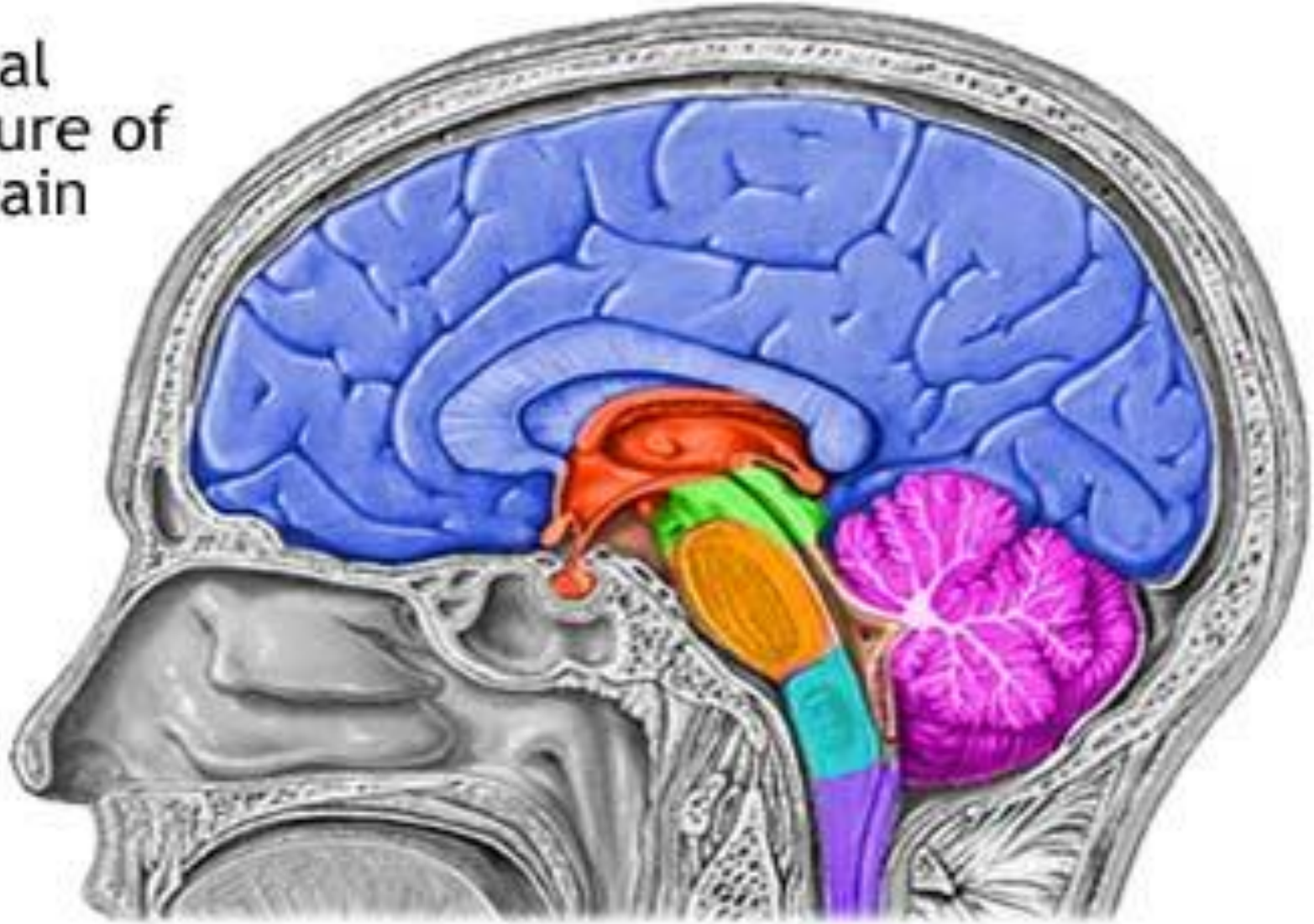

- Spinal cord
- Medulla Oblongata
- Cerebellum
- Midbrain
- Diencephalon
- Cerebral hemisphere
- Pons

Median Section of the Brain

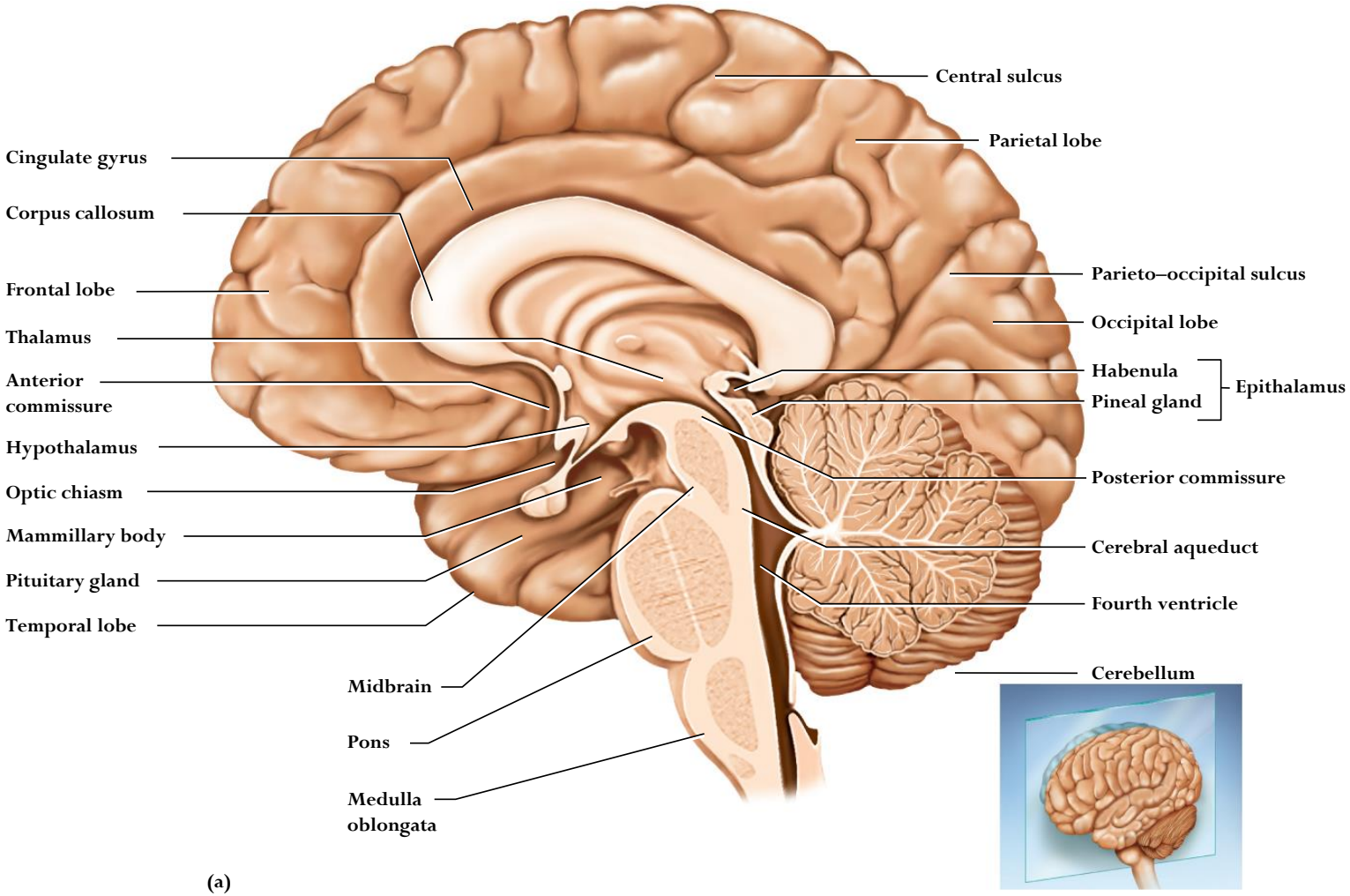

(a)

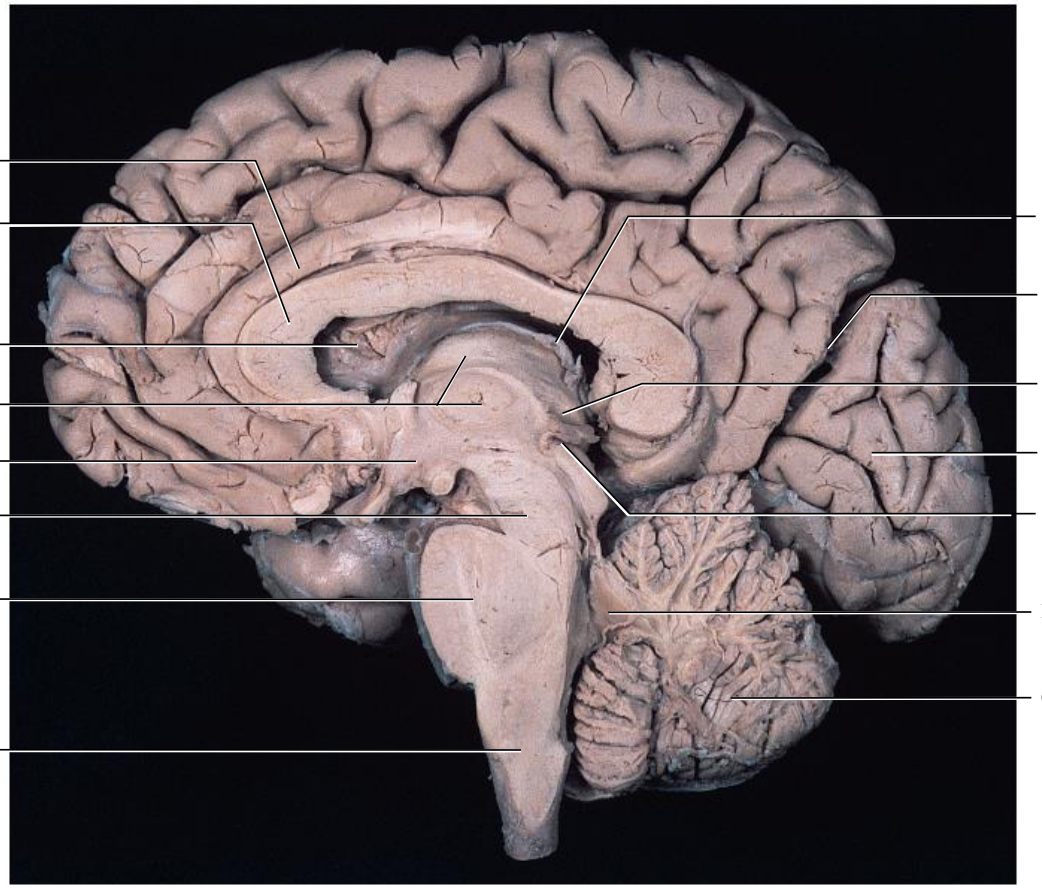
Cingulate gyrus
Corpus callosum
Choroid plexus
Thalamus
Hypothalamus
Midbrain
Pons
Medulla oblongata
Lateral ventricle
Parieto–occipital sulcus
Pineal gland
Occipital lobe
Posterior commissure
Fourth ventricle
Cerebellum

(b)

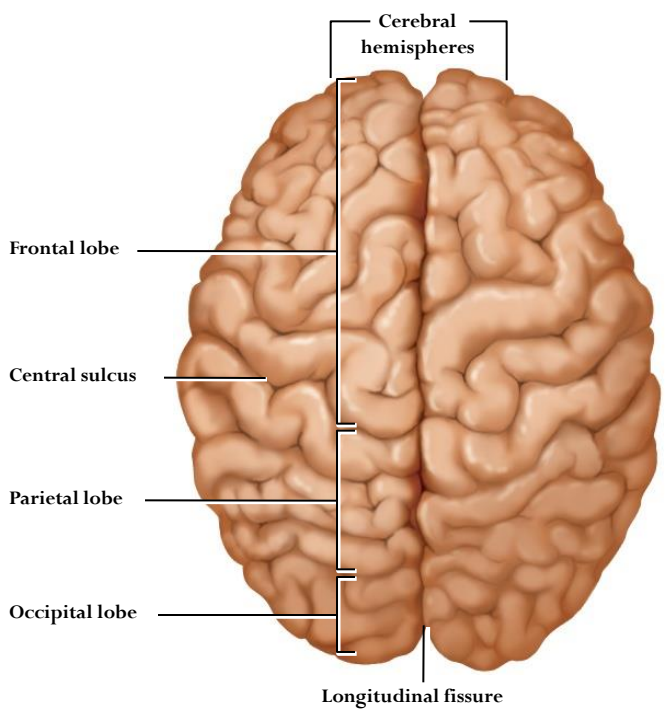

(a) Superior view

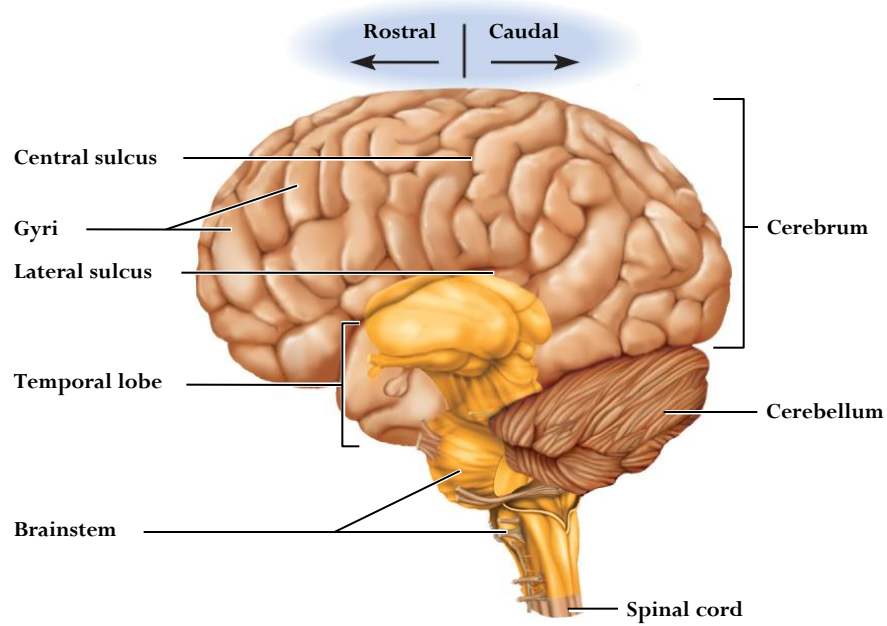

(b) Lateral view

- two cerebral hemispheres divided by longitudinal fissure
  - connected by white fibrous tract the corpus callosum
  - gyri and sulci – increases amount of cortex in the cranial cavity
  - gyri increases surface area for information processing capability
  - some sulci divide each hemisphere into lobes named for the cranial bones that overly them

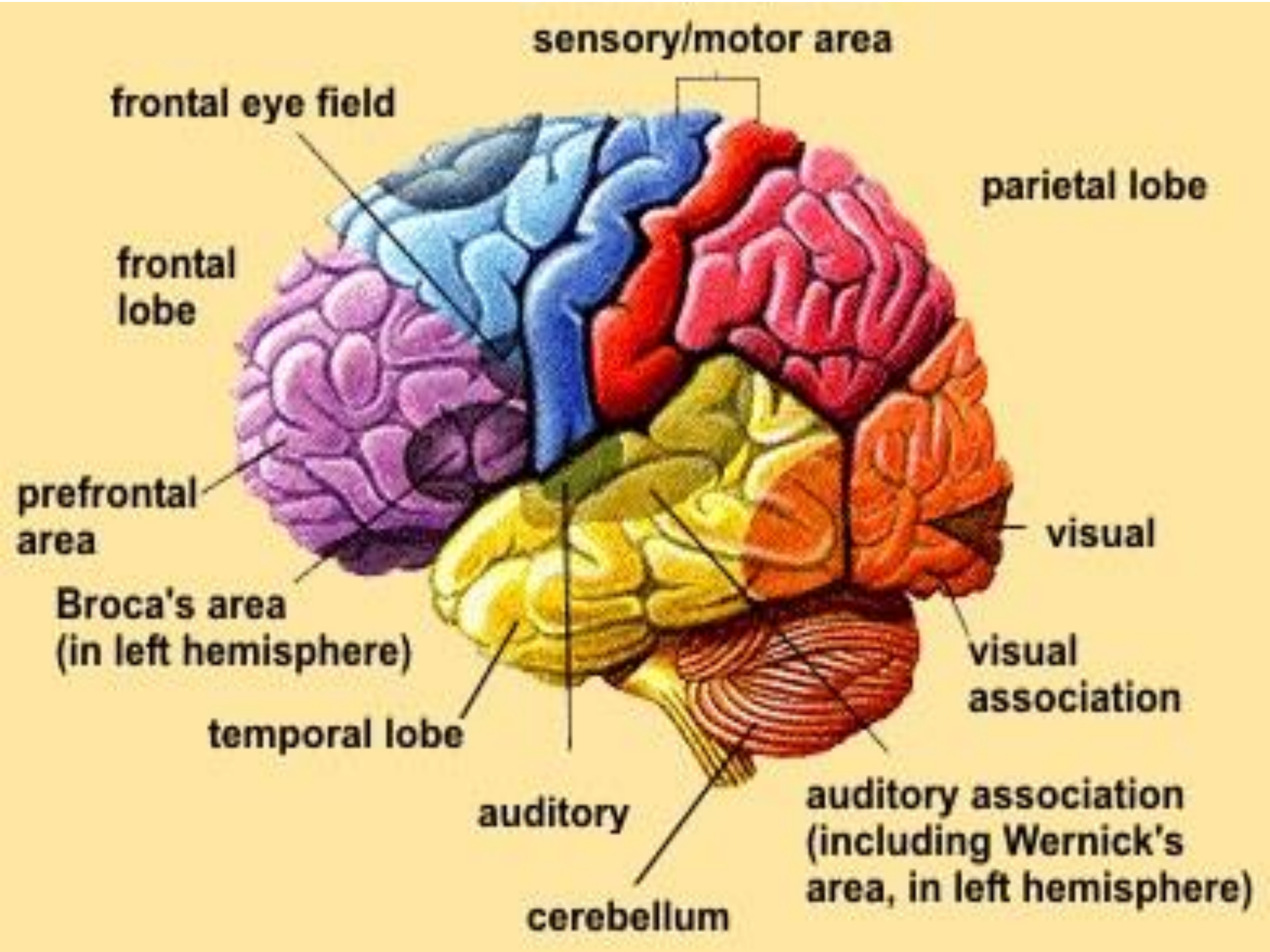
sensory/motor area
frontal eye field
parietal lobe
frontal lobe
prefrontal area
visual
Broca's area (in left hemisphere)
visual association
temporal lobe
auditory
auditory association (including Wernick's area, in left hemisphere)
cerebellum

Functions of Cerebrum - Lobes

- frontal lobe
  - voluntary motor functions
  - motivation, foresight, planning, memory, mood, emotion, social judgment, and aggression
- parietal lobe
  - receives and integrates general sensory information, taste and some visual processing
- occipital lobe
  - primary visual center of brain
- temporal lobe
  - areas for hearing, smell, learning, memory, and some aspects of vision and emotion
- insula (hidden by other regions)
  - understanding spoken language, taste and sensory information from visceral receptors

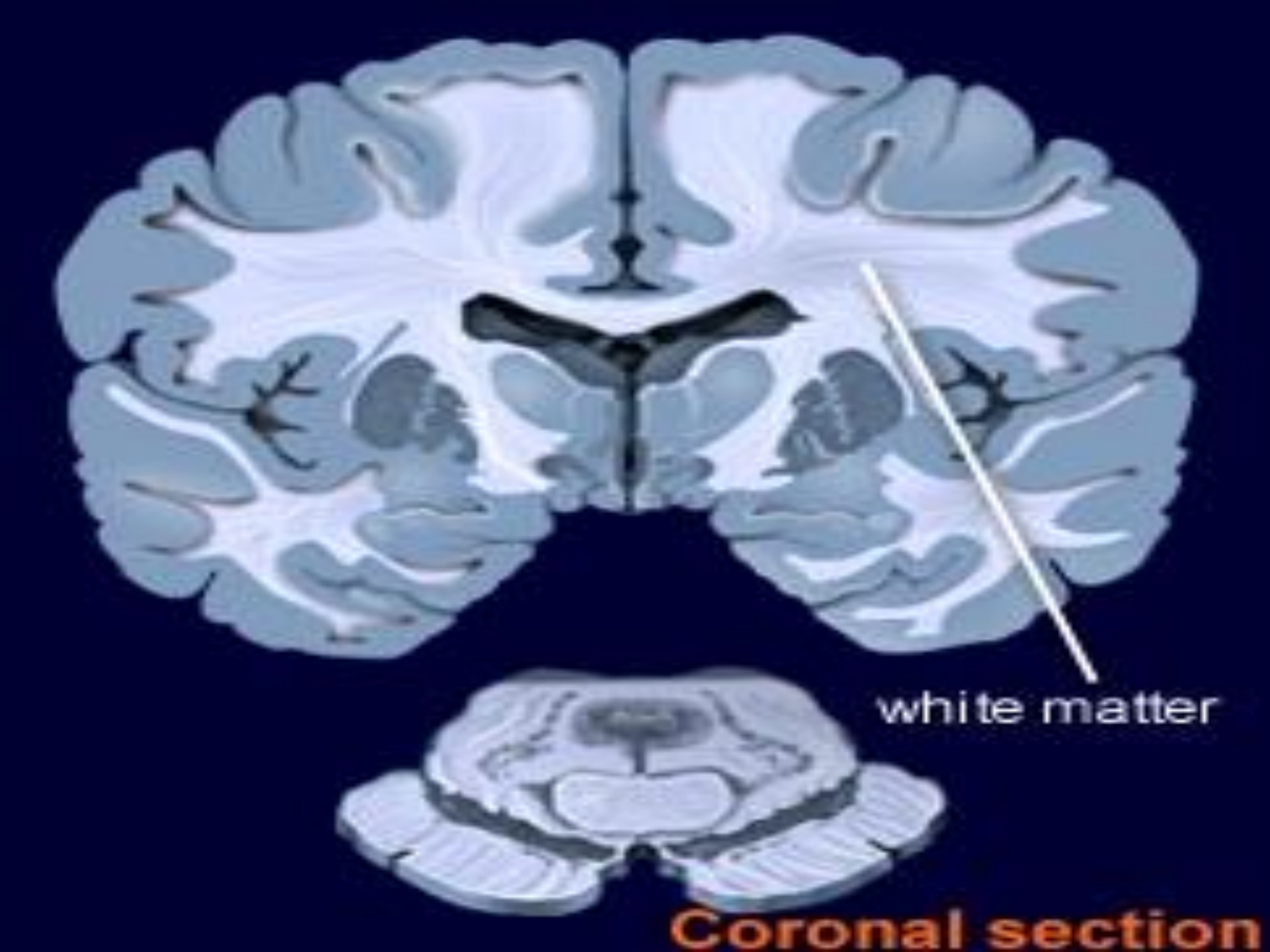
white matter
Coronal section

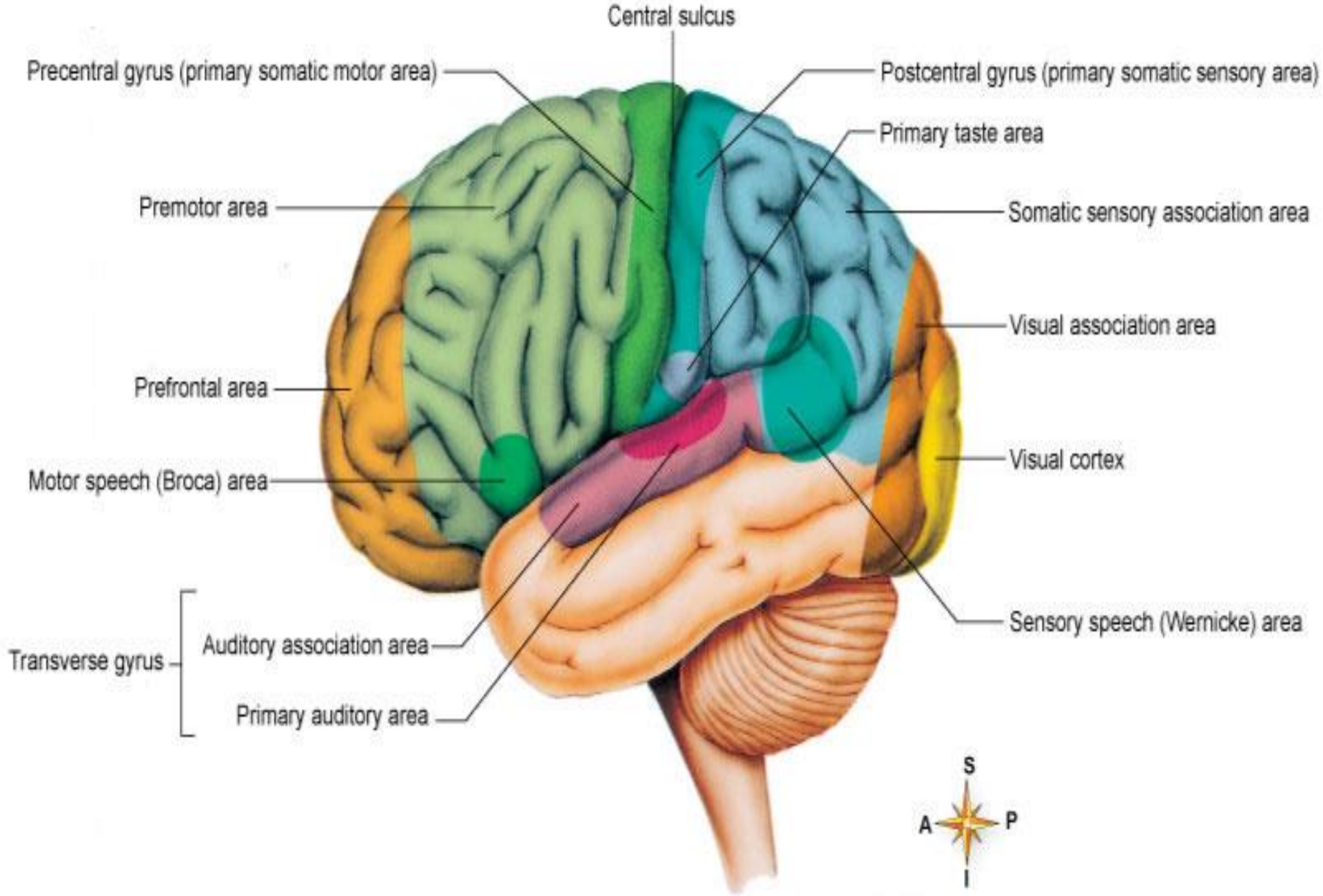

Fig. 13-19. **Functional areas of the cerebral cortex.**

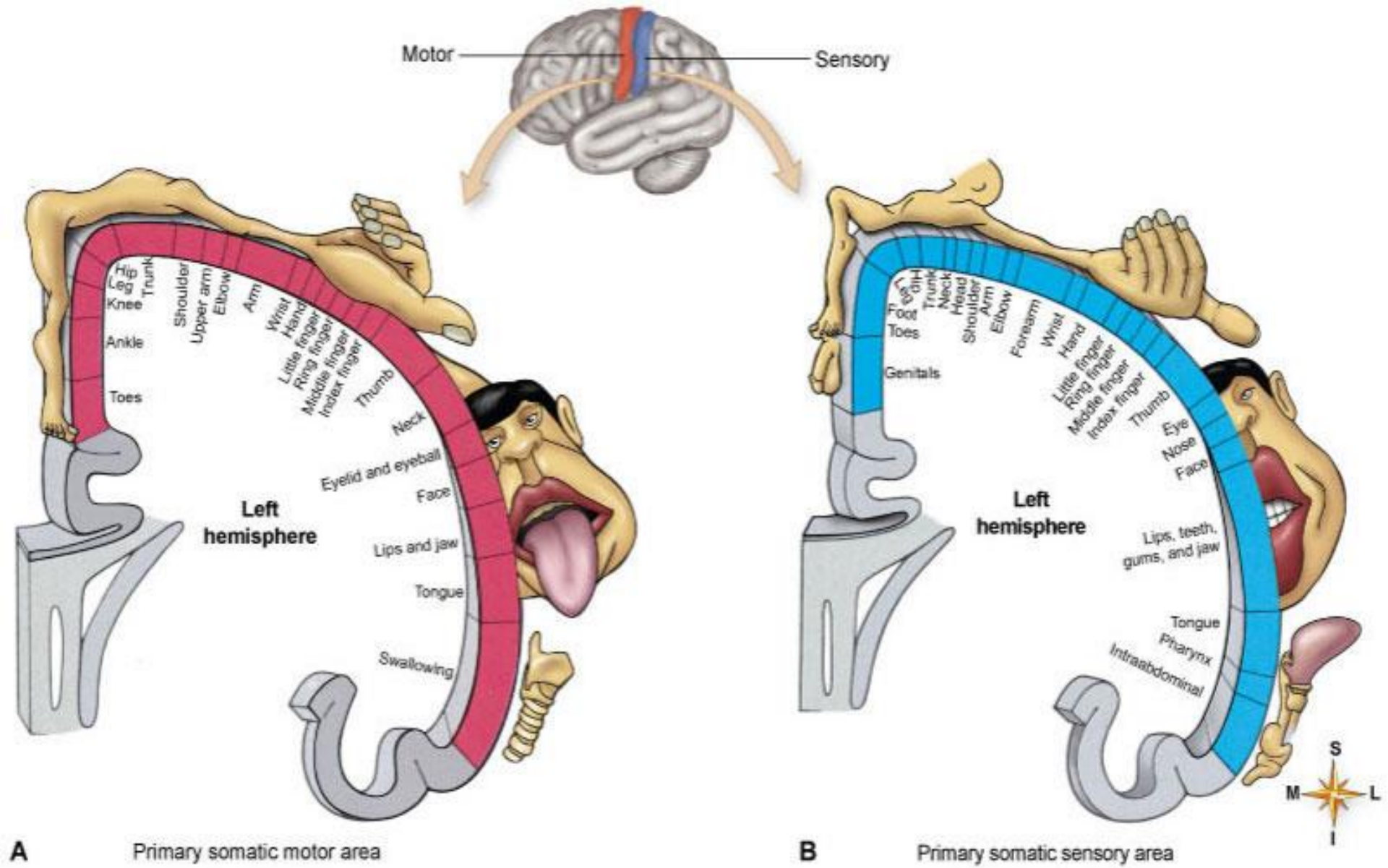

Fig. 13-20. **Primary somatic sensory (A) and motor (B) areas of the cortex.** The body parts illustrated here show which parts of the body are "mapped" to specific areas of each cortical area. The exaggerated face indicates that more cortical area is devoted to processing information to and from the many receptors and motor units of the face than for the leg or arm, for example.

BRAIN: CEREBRAL CORTEX

- Sensory functions of the cortex
  - Somatic senses: sensations of touch, pressure, temperature, proprioception, and similar perceptions that require complex sensory organs
  - Cortex contains a somatic sensory map of the body
  - Information sent to primary sensory areas is relayed to sensory association areas and other parts of the brain
  - The sensory information is compared and evaluated, and the cortex integrates separate bits of information into whole perceptions
- Motor functions of the cortex
  - For normal movements to occur, many parts of the nervous system must function

Cerebral Lateralization

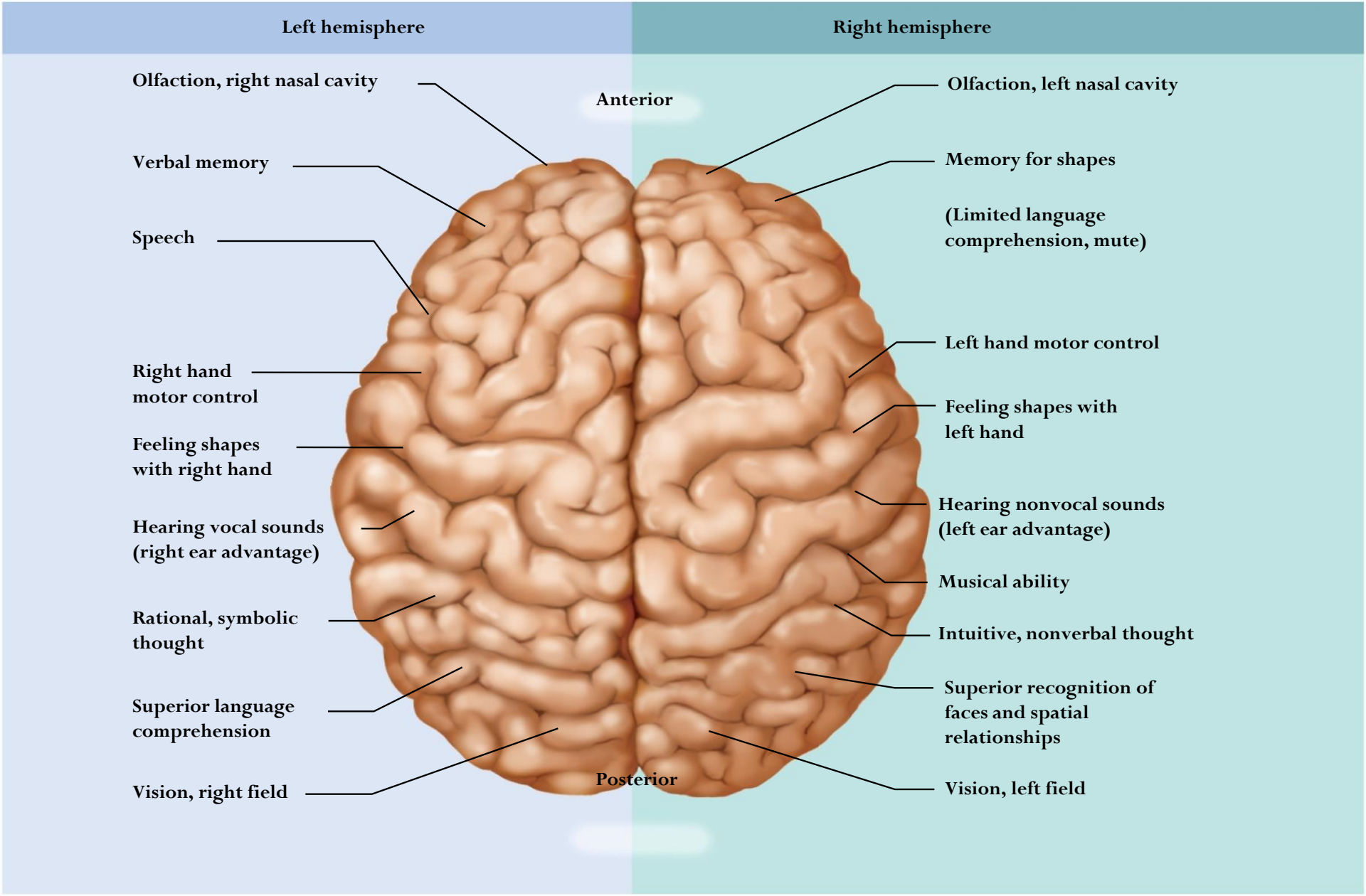

- cerebral lateralization – the difference in the structure and function of the cerebral hemispheres
- left hemisphere - *categorical hemisphere*
  - specialized for spoken and written language
  - sequential and analytical reasoning (math and science)
- right hemisphere - *representational hemisphere*
  - perceives information in a more integrated holistic way
  - musical and artistic skill
  - comparison of sights, sounds, smells, and taste
- lateralization develops with age
  - males exhibit more lateralization than females and suffer more functional loss when one hemisphere is damaged

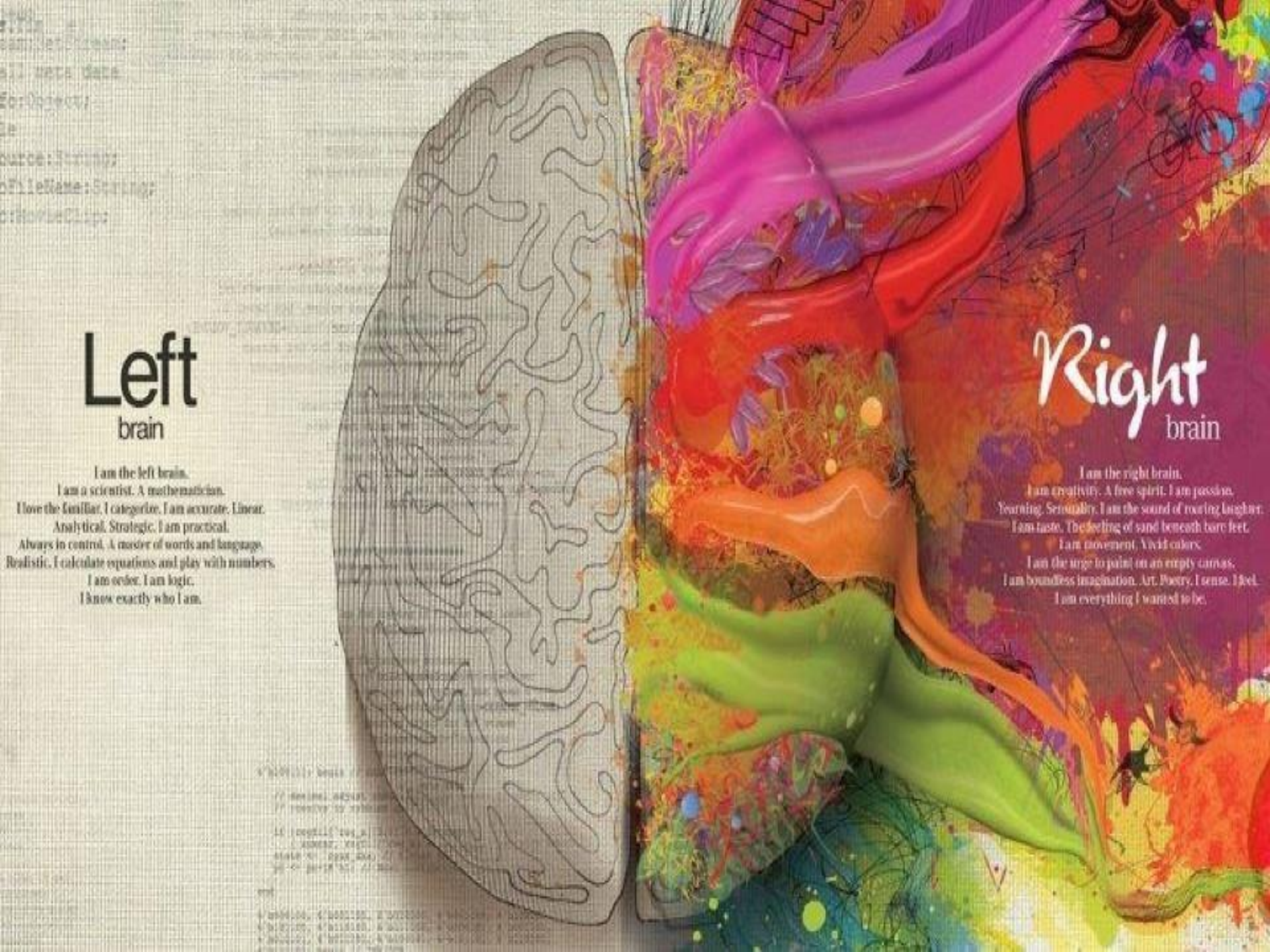
Left
brain
I am the left brain.
I am a scientist. A mathematician.
I love the familiar. I categorize. I am accurate. Linear.
Analytical. Strategic. I am practical.
Always in control. A master of words and language.
Realistic. I calculate equations and play with numbers.
I am order. I am logic.
I know exactly who I am.
Right
brain
I am the right brain.
I am creativity. A free spirit. I am passion.
Yearning. Sensuality. I am the sound of roaring laughter.
I am taste. The feeling of sand beneath bare feet.
I am movement. Vivid colors.
I am the urge to paint on an empty canvas.
I am boundless imagination. Art. Poetry. I sense. I feel.
I am everything I wanted to be.

FEMALE BRAIN

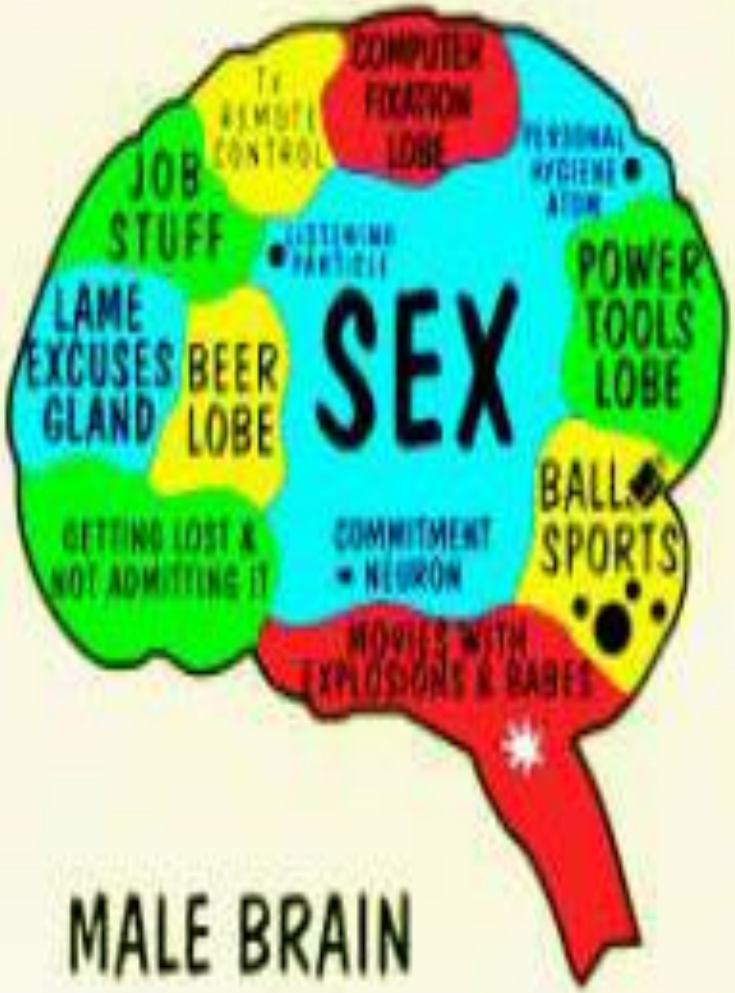

MALE BRAIN

http://pointriderrepublican.typepad.com/brain_fart.gif

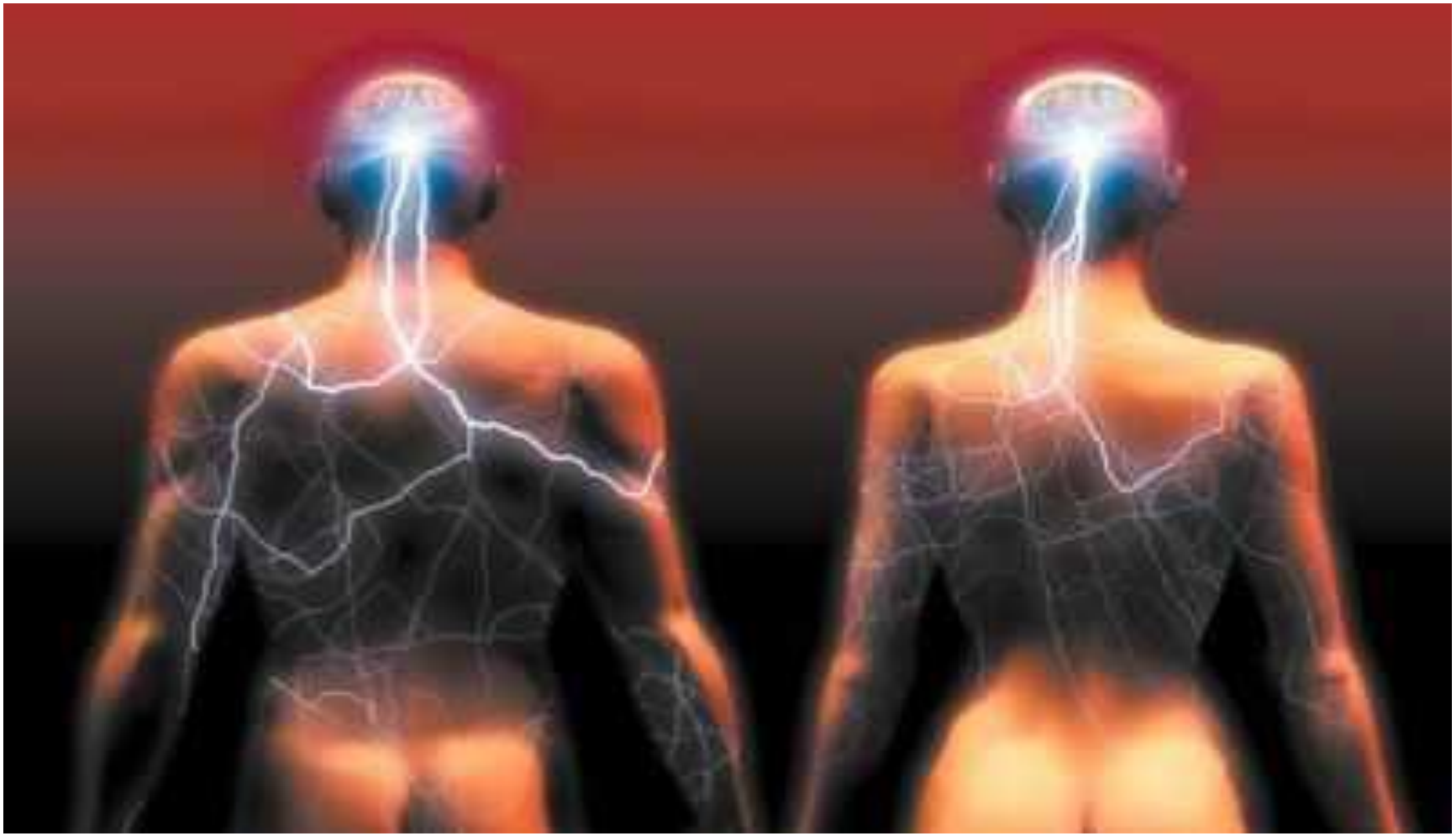

CONSCIOUSNESS

- State of awareness of one's self, one's environment, and other human beings
- Depends on excitation of cortical neurons by impulses conducted to them by the reticular activating system
- Two current concepts about the reticular activating system
  - Functions as arousal system for the cerebral cortex
  - Functioning is crucial for maintaining consciousness

Cognition

- cognition – the range of mental processes by which we acquire and use knowledge
  - such as sensory perception, thought, reasoning, judgment, memory, imagination, and intuition
- association areas of cerebral cortex has above functions
  - constitutes about 75% of all brain tissue
- studies of patients with brain lesions, cancer, stroke, and trauma yield information on cognition
  - parietal lobe association area – perceiving stimuli
  - temporal lobe association area – identifying stimuli
    - agnosia – inability to recognize, identify, and name familiar objects
    - prosopagnosia – person cannot remember familiar faces
  - frontal lobe association area – planning our responses and personality – inability to execute appropriate behavior

Memory

- information management requires
  - learning – acquiring new information
  - memory – information storage and retrieval
  - forgetting – eliminating trivial information; as important as remembering
- amnesia – defects in declarative memory – inability to describe past events
- procedural memory – ability to tie your shoes
  - anterograde amnesia – unable to store new information
  - retrograde amnesia – cannot recall things they knew before the injury
- hippocampus – important memory-forming center
  - does not store memories
  - memory consolidation – the process of “teaching the cerebral cortex” until a long-term memory is established
  - long-term memories are stored in various areas of the cerebral cortex
- cerebellum – helps learn motor skills
- amygdala - emotional memory

Lobotomy of Phineas Gage

- severe injury with metal rod
- injury to the ventromedial regior of both frontal lobes
- extreme personality change
  - fitful, irreverent, grossly profane
  - opposite of previous personality
- prefrontal cortex functions
  - planning, moral judgment, an emotional control

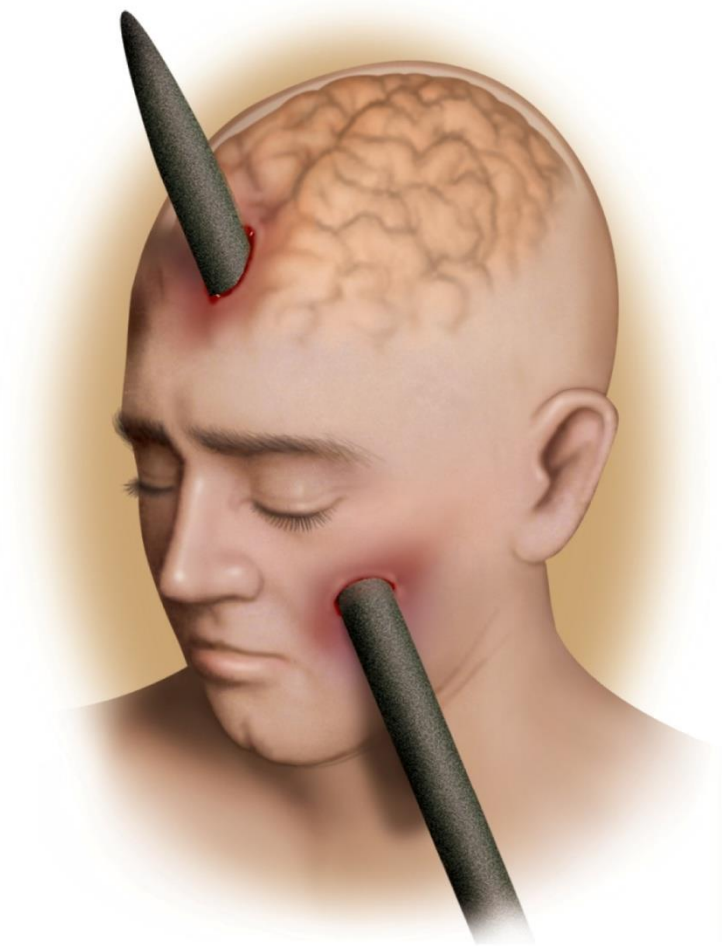

Emotion

- prefrontal cortex - seat of judgment, intent, and control over expression of emotions
- feelings come from hypothalamus and amygdala
- amygdala receives input from sensory systems
  - role in food intake, sexual behavior, and drawing attention to stimuli
  - one output goes to hypothalamus influencing somatic and visceral motor systems
  - other output to prefrontal cortex important in controlling expression of emotions
- behavior shaped by learned associations between stimuli, our responses to them, and the reward or punishment that results

Cerebellum

- marked by gyri, sulci, and fissures
- about 10% of brain volume
- contains over 50% of brain neurons

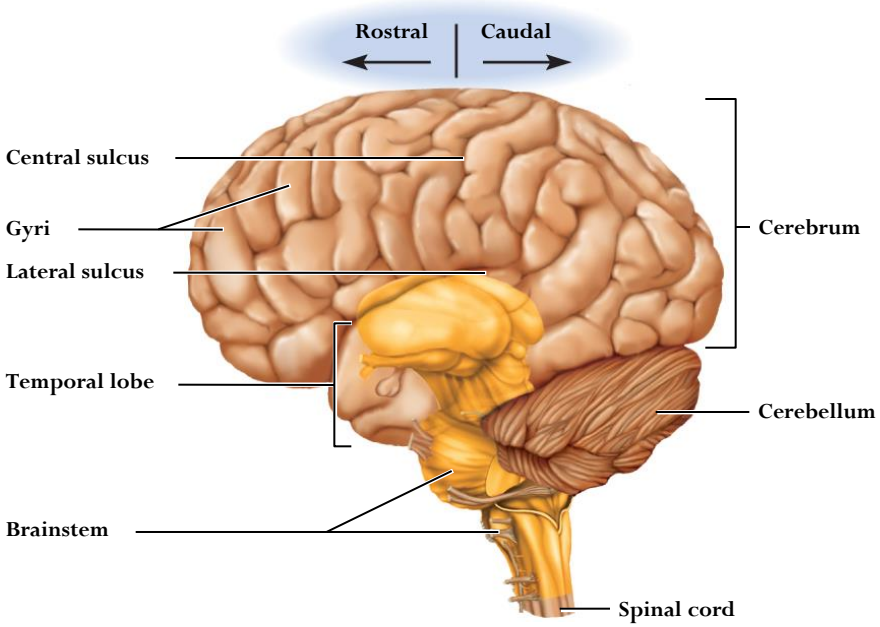

(b) Lateral view

Structure of the Cerebellum

- Second largest part of the brain; contains more neurons than the rest of the nervous system
- Located just below the posterior portion of the cerebrum
- Gray matter makes in cortex & white matter interior

Structure of the Cerebellum

- Internal white matter: composed of short and long tracts
  - Shorter tracts conduct impulses from cerebellar cortex to interior of the cerebellum
  - Longer tracts conduct impulses to and from the cerebellum
- Dentate nuclei
  - Important pair of cerebellar nuclei, one in each hemisphere
  - Nuclei connected with thalamus and motor areas of the cerebral cortex by tracts
  - Through the tracts, cerebellar impulses influence the motor cortex and the motor cortex influences the cerebellum

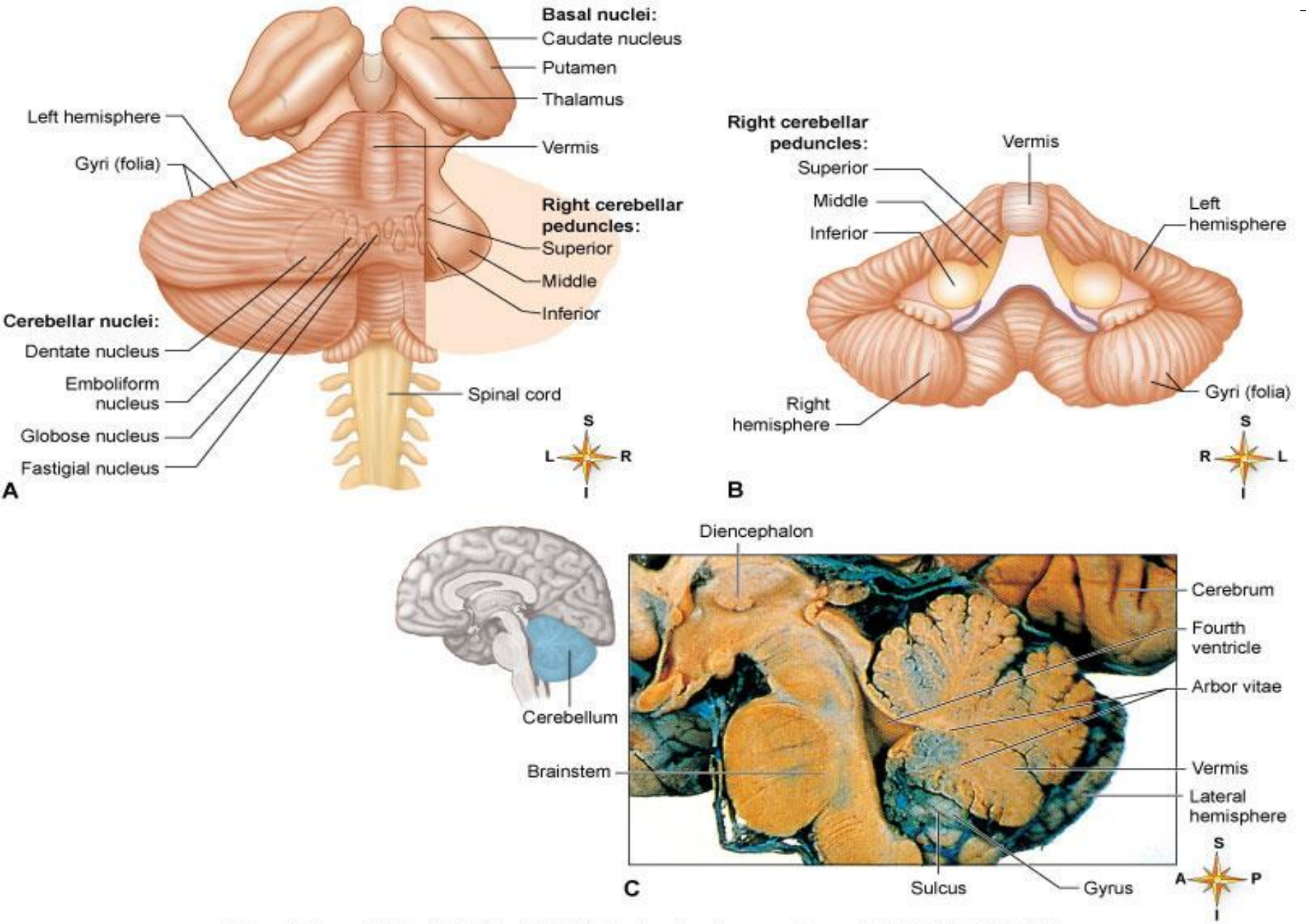

C: From Abrahams P, Marks S, Hutchings R: *McMinn's color atlas of human anatomy*, ed 5, Philadelphia, 2003, Mosby.

Fig. 13-11. **Cerebellum. A,** Posterior view of the surface of the cerebellum. **B,** Anterior view of the cerebellum (with the brainstem removed). **C,** Photograph of midsagittal brain section shows internal features of the cerebellum and surrounding structures of the brain.

Brainstem

- major components
  - diencephalon
  - midbrain
  - pons
  - medulla oblongata

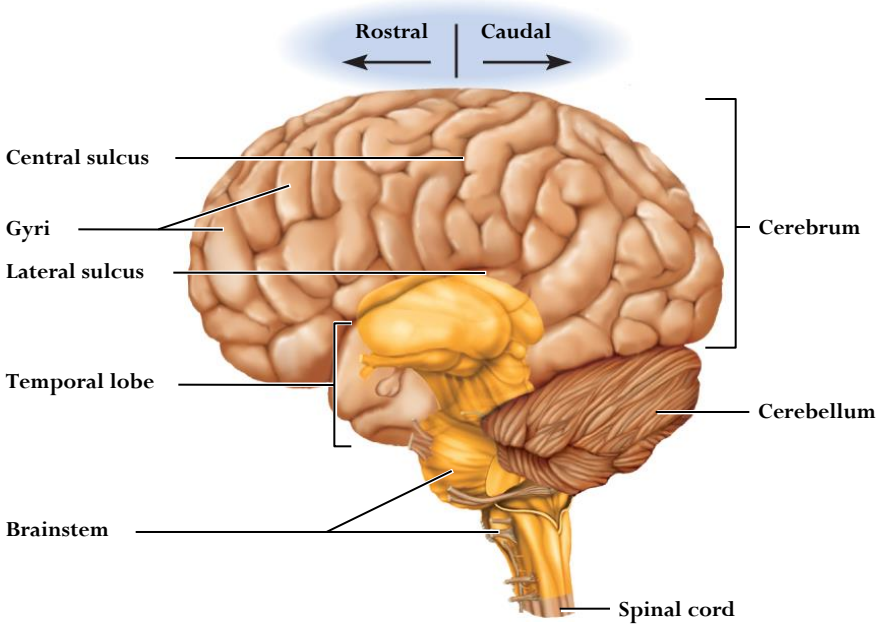

(b) Lateral view

Internal structure of the brain

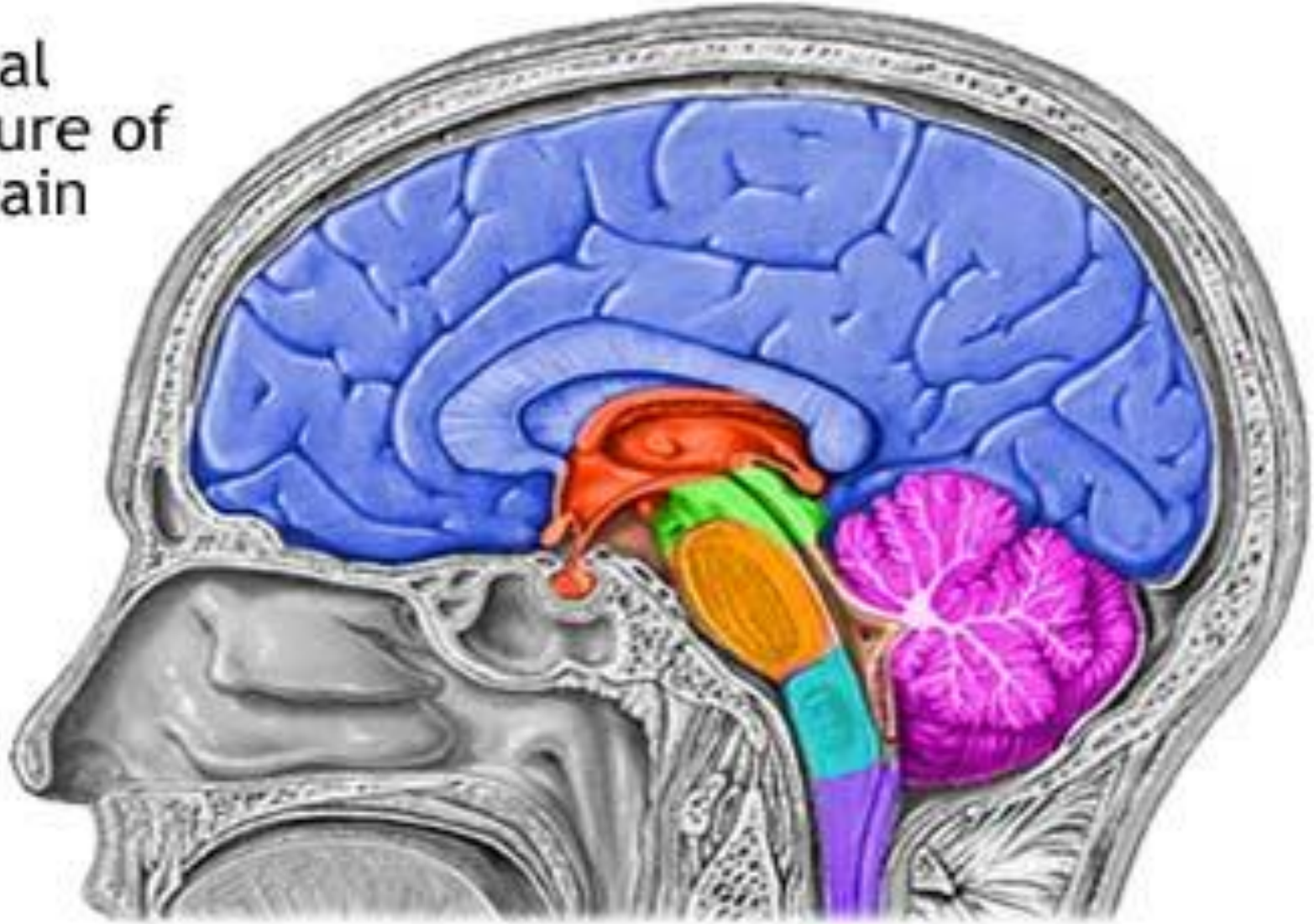

- Spinal cord
- Medulla Oblongata
- Cerebellum
- Midbrain
- Diencephalon
- Cerebral hemisphere
- Pons

Structures of the Brainstem

- Medulla oblongata
  - Lowest part of the brainstem
  - Part of the brain that attaches to spinal cord; located just above the foramen magnum
  - Composed of white matter and a network of gray and white matter called the *reticular formation network*
  - *Waterboy Medulla Oblongata*
- Pons
  - Located above the medulla and below the midbrain
  - Composed of white matter and reticular formation
- Midbrain
  - Located above the pons and below the cerebrum
  - Composed of white tracts and reticular formation

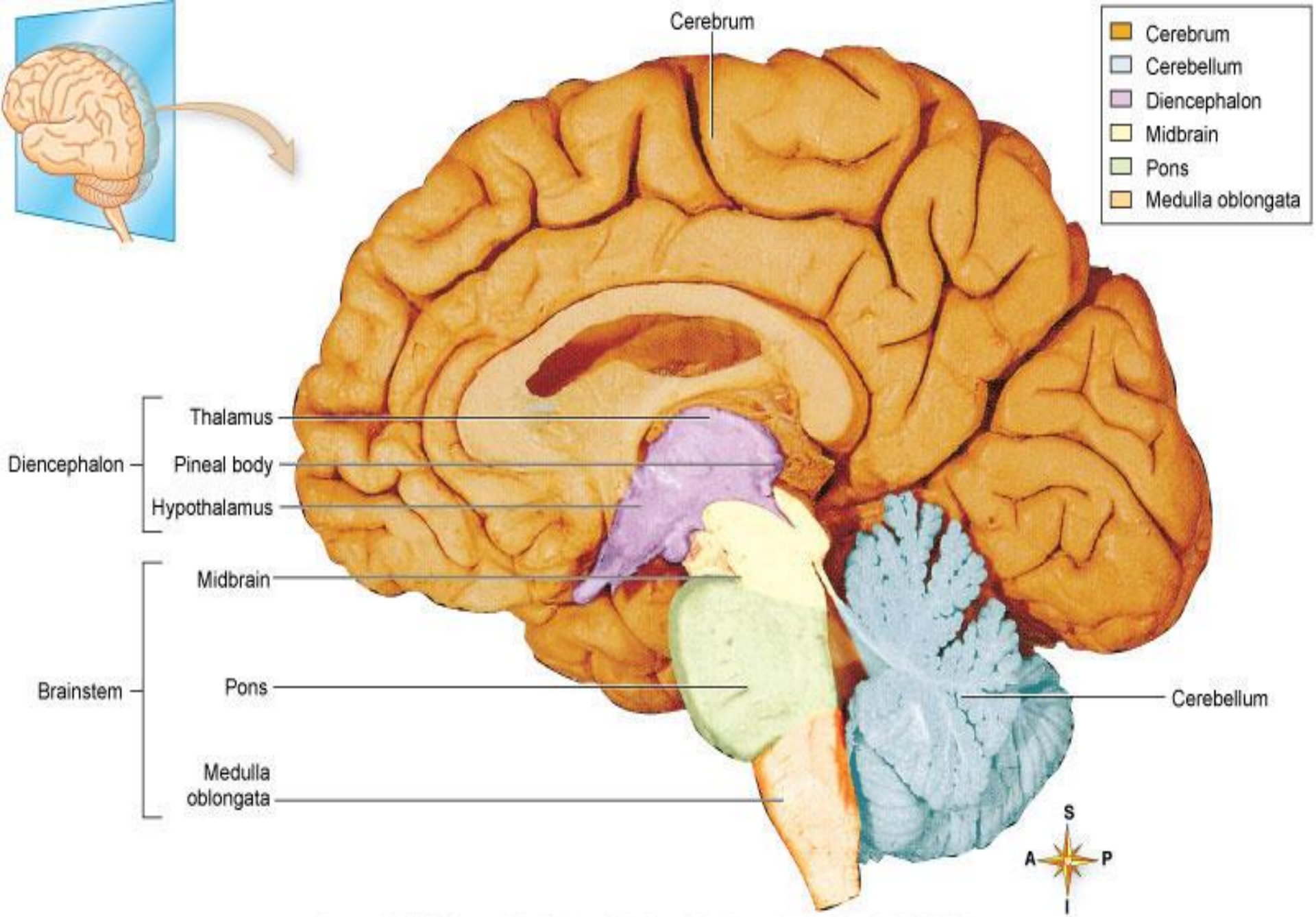

Courtesy Vidic B, Suarez FR: *Photographic atlas of the human body*, St Louis, 1984, Mosby.

Fig. 13-9. **Divisions of the brain.** A midsagittal section of the brain reveals features of its major divisions.

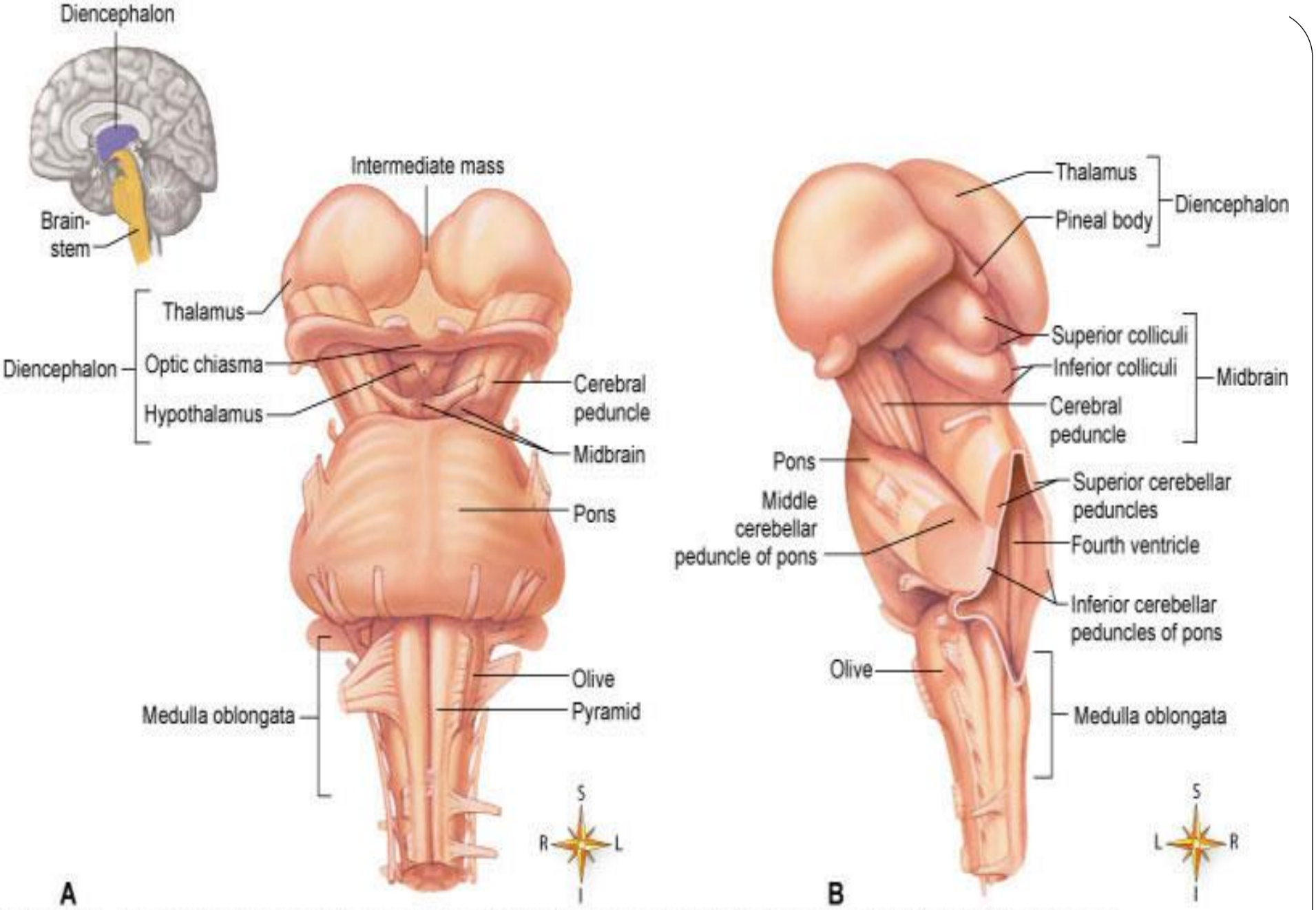

Fig. 13-10. **The brainstem and diencephalon. A,** Anterior aspect. **B,** Posterior aspect (shifted slightly to lateral).

Functions of the Brainstem

- Performs sensory, motor, and reflex functions
- Important sensory tracts that pass through the brainstem
- Sensory tracts terminate in the brainstem
- Nuclei in medulla contain reflex centers
  - Vital importance: cardiac, vasomotor, and respiratory centers
  - Nonvital reflexes: vomiting, coughing, sneezing, etc.
- Pons contains reflexes mediated by fifth, sixth, seventh, and eighth cranial nerves and pneumotaxic centers that help regulate respiration

Thalamus

- ovoid mass on each side of the brain perched at the superior end of the brainstem beneath the cerebral hemisphere
- composed of at least 23 nuclei
- the "**gateway to the cerebral cortex"** – nearly all input to the cerebrum passes by way of synapses in the thalamic nuclei, filters information on its way to cerebral cortex
- plays key role in motor control by relaying signals from cerebellum to cerebrum
- involved in the memory and emotional functions of the limbic system

Thalamus

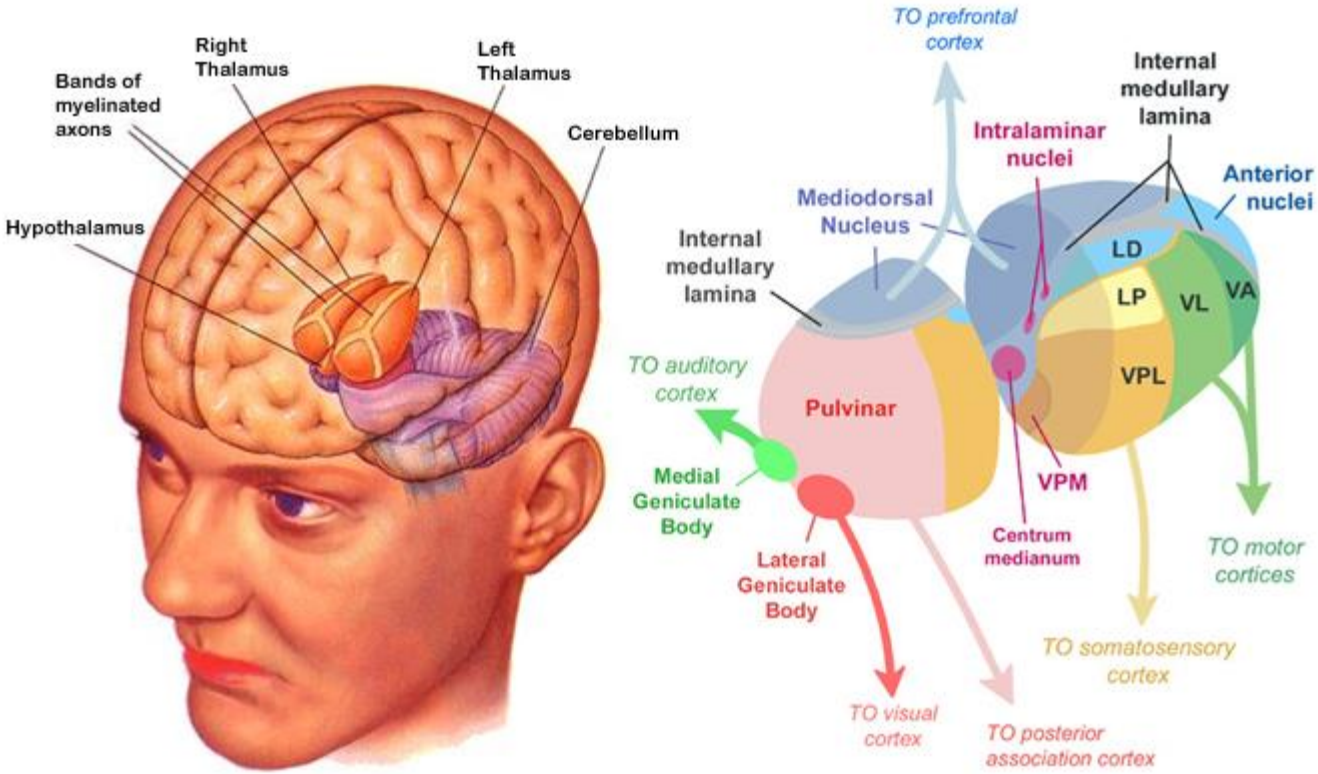
Right Thalamus
Left Thalamus
Bands of myelinated axons
Cerebellum
Hypothalamus
TO prefrontal cortex
Internal medullary lamina
Intralaminar nuclei
Anterior nuclei
Mediodorsal Nucleus
Internal medullary lamina
LD
LP
VL
VA
VPL
TO auditory cortex
Pulvinar
Medial Geniculate Body
VPM
Centrum medianum
Lateral Geniculate Body
TO motor cortices
TO somatosensory cortex
TO visual cortex
TO posterior association cortex

Hypothalamus

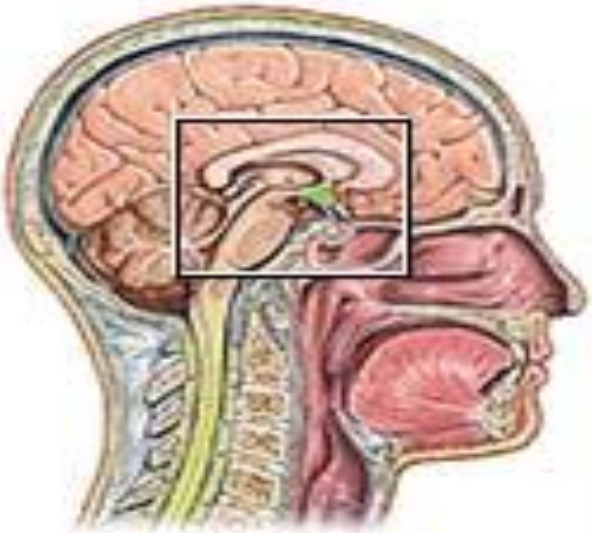

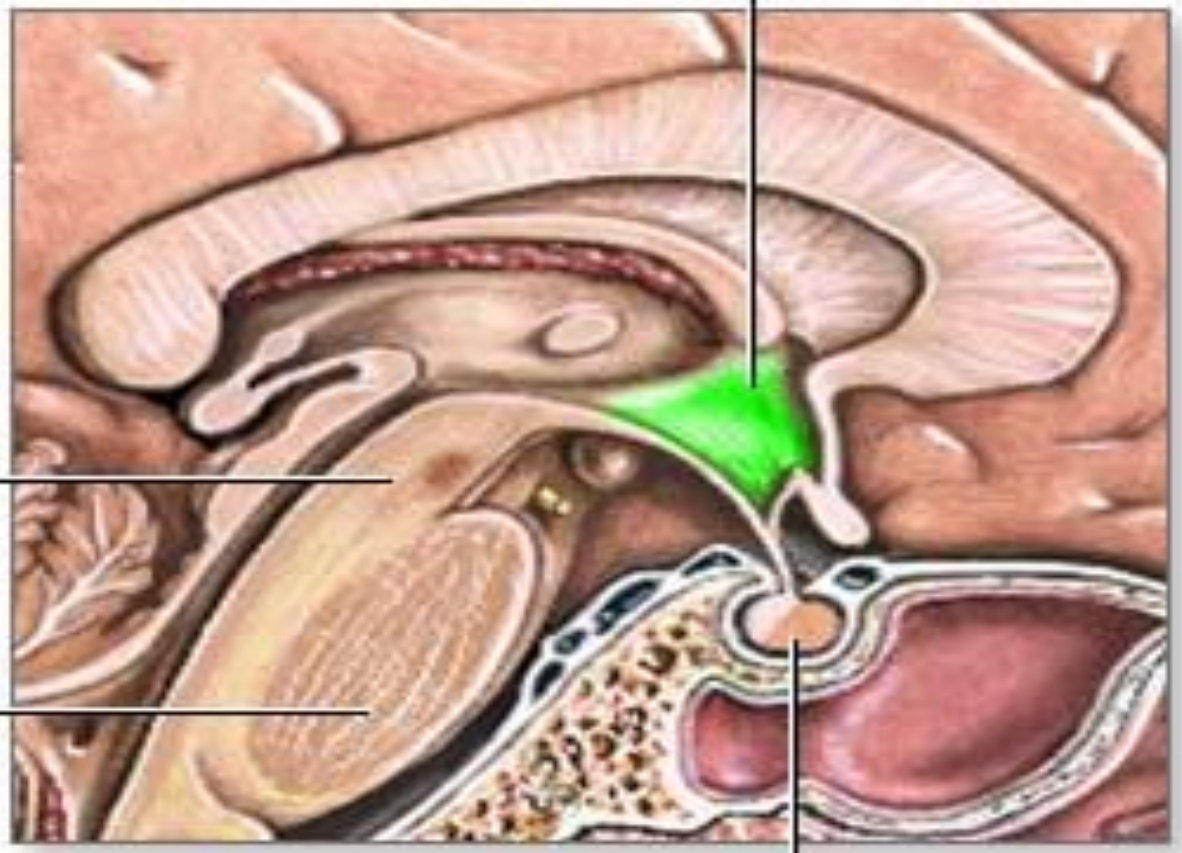

Hypothalamus

- extends anteriorly to optic chiasm and posteriorly to the paired mammillary bodies
- infundibulum – a stalk that attaches the pituitary gland to the hypothalamus
- major control center of autonomic nervous system and endocrine system
  - plays essential roll in homeostatic regulation of all body systems

Functions of Hypothalamic Nuclei

- hormone secretion
  - controls anterior pituitary
  - regulates growth, metabolism, reproduction ,and stress responses
- autonomic effects
  - major integrating center for the autonomic nervous system
  - influences heart rate, blood pressure, gastrointestinal secretions and motility, and others
- thermoregulation
  - hypothalamic thermostat monitors body temperature
  - activates heat-loss center when temp is too high
  - activates heat-promoting center when temp is too low

- food and water intake
  - hunger and satiety centers monitor blood glucose and amino acid levels
    - produce sensations of hunger and satiety
  - thirst center monitors osmolarity of the blood
- rhythm of sleep and waking
  - controls 24 hour circadian rhythm of activity
- memory
- emotional behavior
  - anger, aggression, fear, pleasure, and contentment

Pineal Gland

- Pineal gland
  - Located just above the corpora quadrigemina of the midbrain
  - Involved in regulating the body's biological clock
  - Produces melatonin as a "timekeeping" hormone
    - Melatonin is made from the neurotransmitter serotonin
    - Levels increase when sunlight is absent and decrease when sunlight is present, thus regulating the circadian (daily) biologic clock
    - Melatonin is the "sleep hormone"

    - Parts of the brain

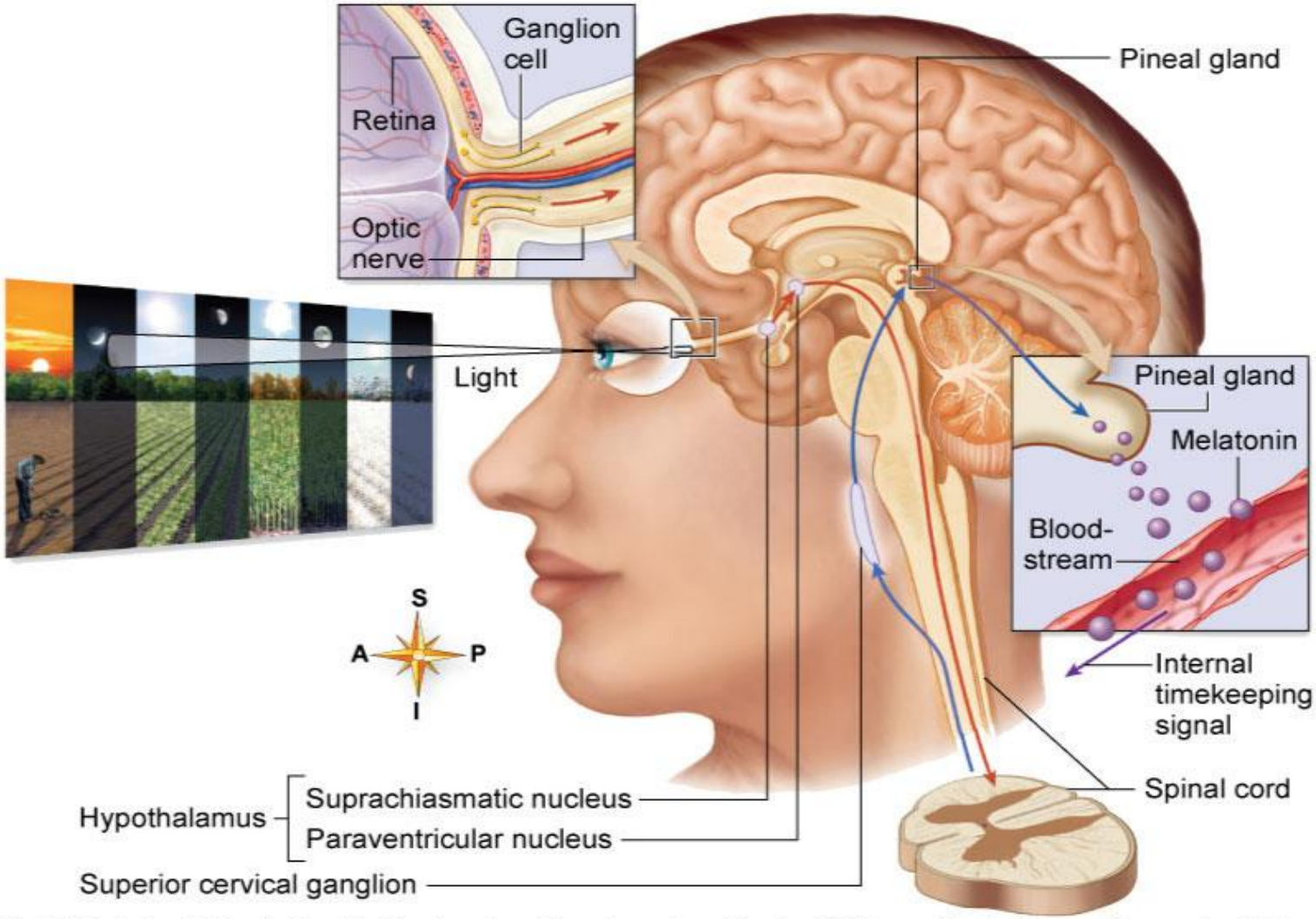

Fig. 13-14. **Role of pineal gland in timekeeping.** Changing external levels of light are detected by special receptors in the retina of the eye, and the information is relayed to the suprachiasmatic nucleus (SCN) of the hypothalamus. When light levels decrease, signals from the SCN increase, triggering the paraventricular nucleus and a pathway of nervous system signals that eventually result in the release of increased amounts of melatonin from the pineal gland. The changing levels of melatonin throughout the day serve as an internal timekeeping signal.