Male Reproductive System

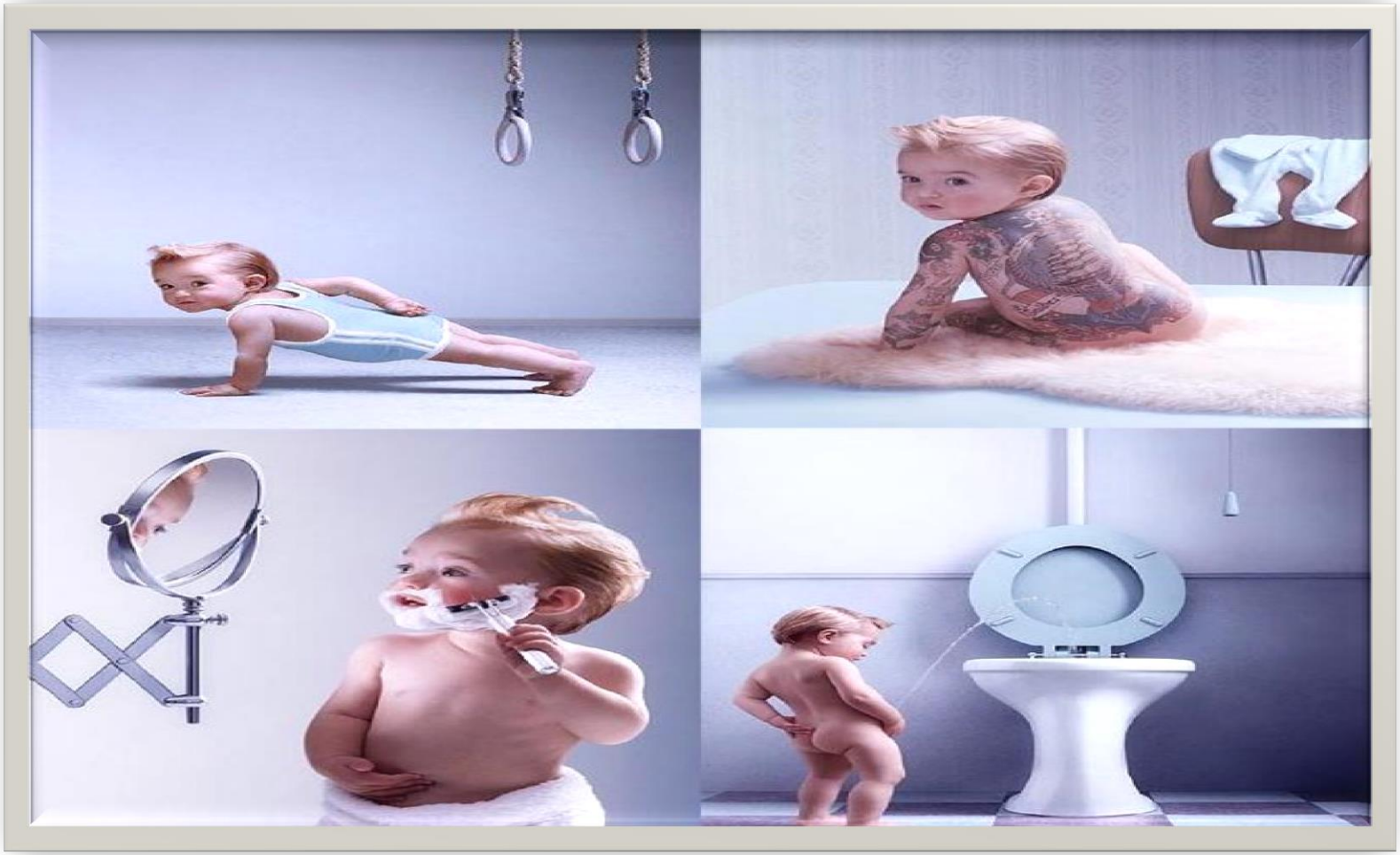

Dr. Mumaugh – Circa 1950

Reproductive System Basics

- Primary sex organs (gonads) – testes in males, ovaries in females
- Gonads produce sex cells called gametes (gametes means spouses) and secrete sex hormones
- Accessory reproductive organs – ducts, glands, and external genitalia
- Sex hormones – androgens (males), and estrogens and progesterone (females)

Reproductive System Basics

- Sex hormones play roles in:
  - The development and function of the reproductive organs
  - Sexual behavior and drives
  - The growth and development of many other organs and tissues

Reproductive System Basics

- Functioning of the reproductive system ensures the survival of the genetic characteristics of a species
- Male reproductive system consists of organs whose functions are to produce, transfer, and introduce mature sperm into the female reproductive tract, where fertilization can occur

Male Reproductive System

- The male gonads (testes) produce sperm and lie within the scrotum
- Sperm are delivered to the exterior through a system of ducts: epididymis, vas deferens, ejaculatory duct, and the urethra
- Accessory sex glands:
  - Empty their secretions into the ducts during ejaculation
  - Include the seminal vesicles, prostate gland, and bulbourethral glands

MALE REPRODUCTIVE SYSTEM

TESTES (♂ GONADS) PRODUCE SPERM
- SPERMATOGENESIS

SPERM DELIVERED TO EXTERIOR VIA SYSTEM OF DUCTS

EPIDIDYMIS
↓
VAS DEFERENS
↓
EJACULATORY DUCT
↓
URETHRA

ACCESORY GLANDS EMPTY SECRETIONS INTO DUCTS DURING EJACULATION
- SEMINAL VESICLES
- PROSTATE GLAND
- BULBOURETHRAL GLANDS

Male Reproductive System

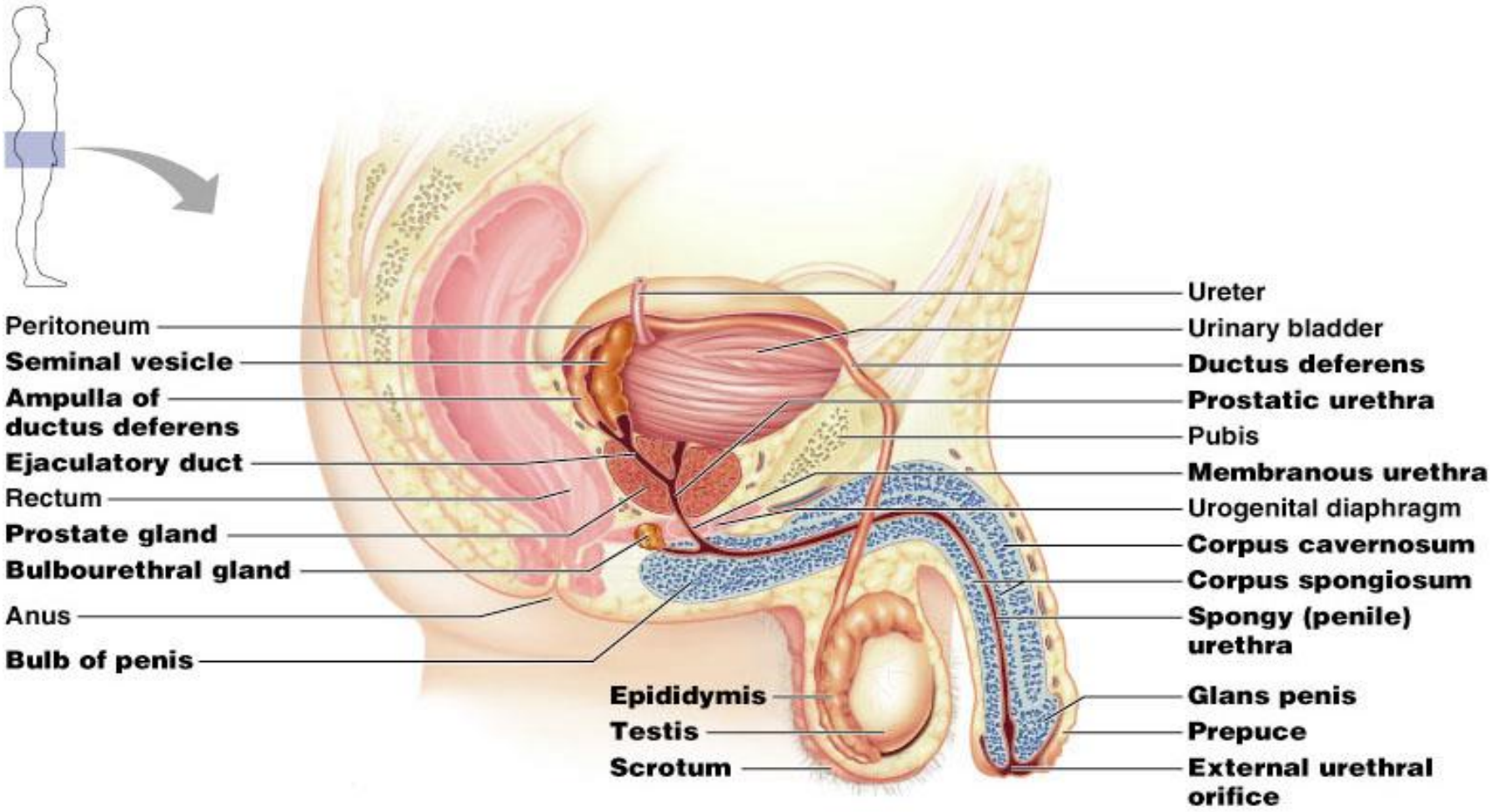

Male Reproductive Organs

- Essential organs
  - For production of gametes
  - Gonads of male – testes
- Accessory organs
  - Support the reproductive process
  - Genital ducts convey sperm outside the body
    - pair of epididymides
    - paired vasa deferentia,
    - pair of ejaculatory ducts, and the
    - urethra

- Accessory glands
  - produce secretions that nourish, transport, and mature sperm
    - pair of seminal vesicles, the prostate, and pair of bulbourethral glands
- Supporting structures
  - Scrotum
  - Penis
  - Pair of spermatic cords

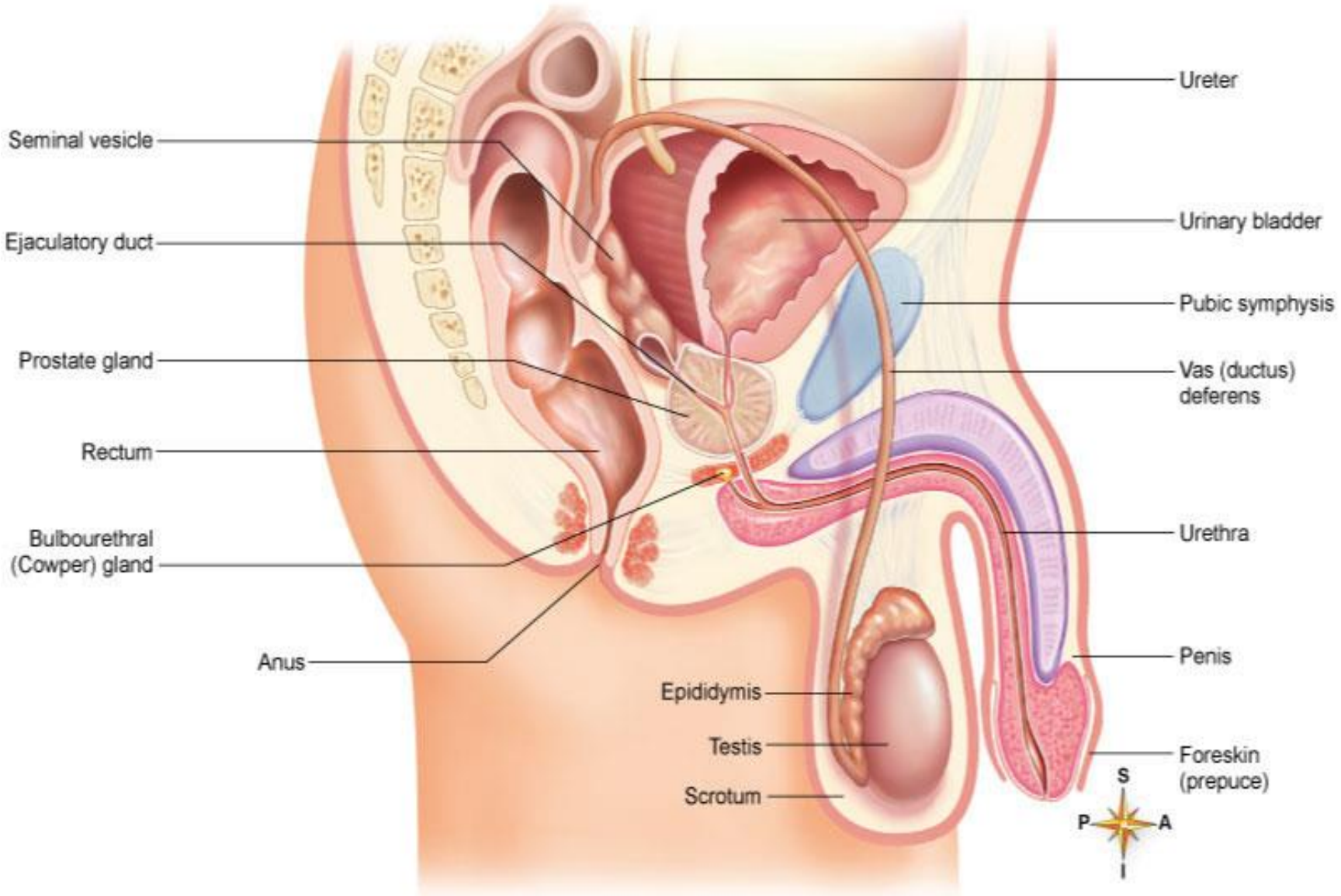
Ureter
Seminal vesicle
Urinary bladder
Ejaculatory duct
Pubic symphysis
Prostate gland
Vas (ductus) deferens
Rectum
Urethra
Bulbourethral (Cowper) gland
Penis
Anus
Epididymis
Testis
Foreskin (prepuce)
Scrotum
S
P
A
I

SPERM TRAVEL

VASECTOMY
VS.
VASOVASOTOMY (50%)

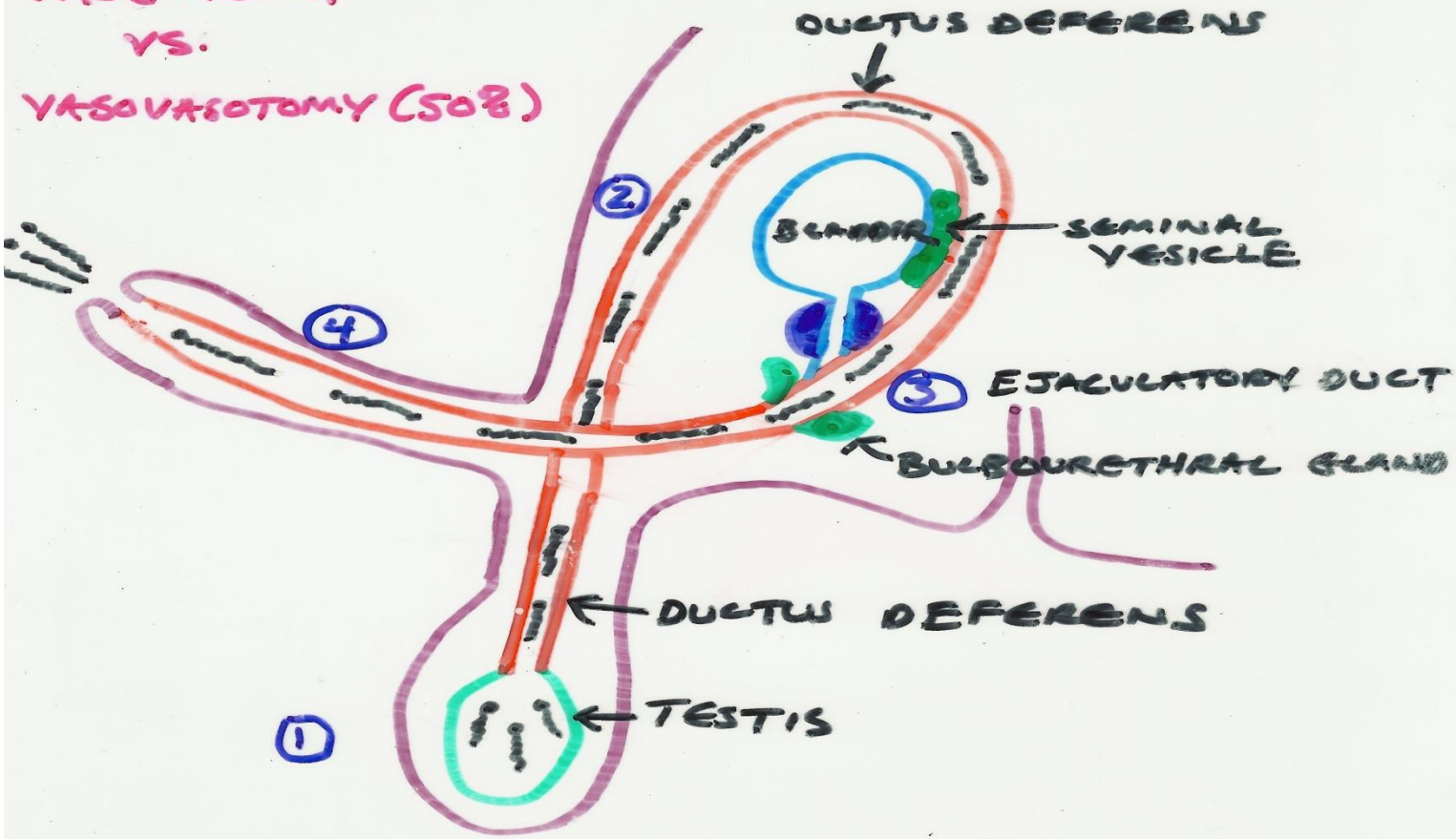

1. EPIDIDYMIS →
2. VAS DEFERENS →
3. EJACULATORY DUCT →
4. URETHRA

- Male – Perineum
  - Roughly diamond-shaped area between thighs
  - Extends from pubic symphysis to coccyx
  - Lateral boundary is the ischial tuberosity bilateral Divided into the urogenital triangle and the anal triangle

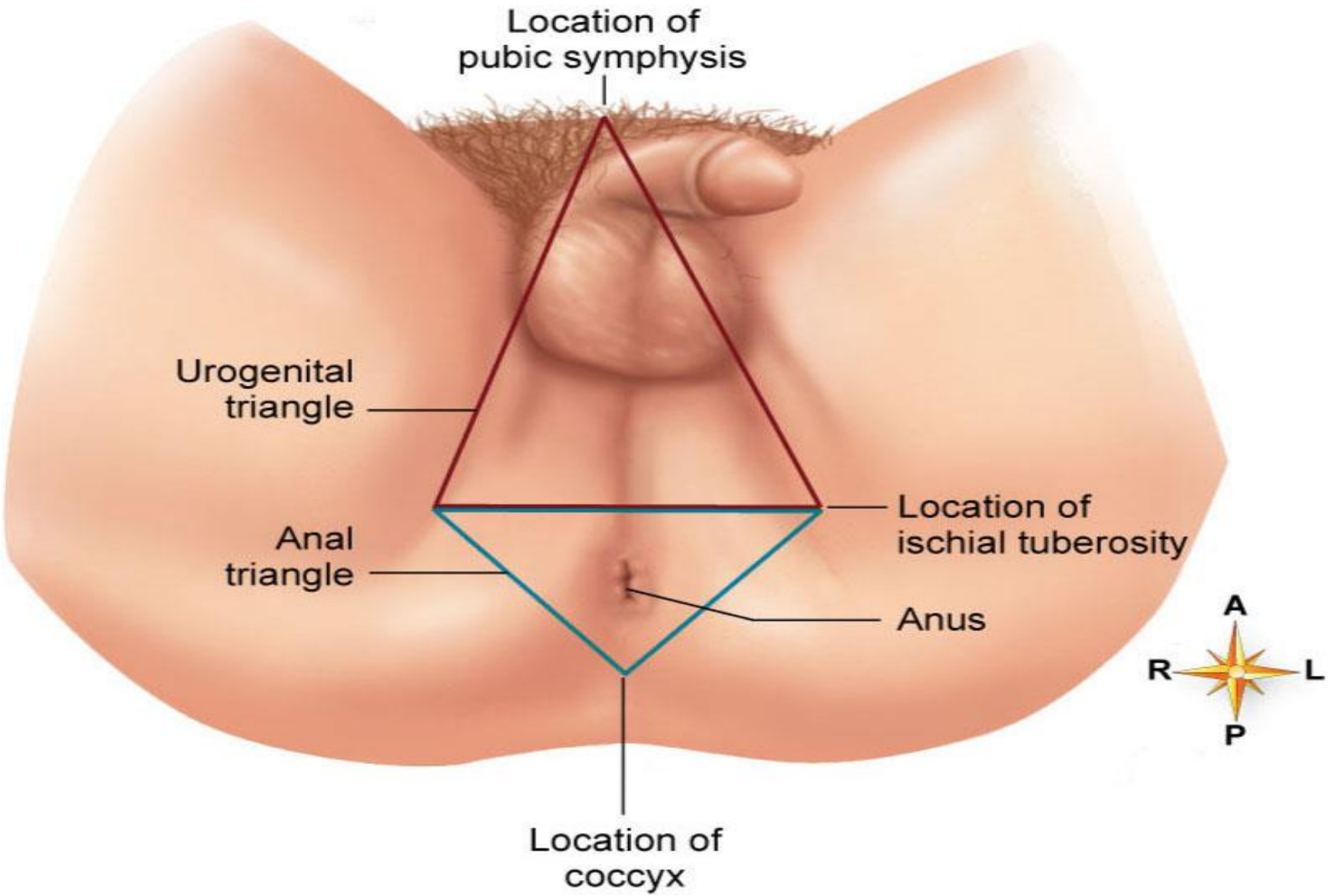
Location of
pubic symphysis
Urogenital
triangle
Anal
triangle
Location of
ischial tuberosity
Anus
Location of
coccyx
A
R
L
P

The Scrotum

- Sac of skin (scrotum = “pouch”) and superficial fascia that hangs outside the abdominopelvic cavity at the root of the penis
- Divided into two compartments - contains paired testicles separated by a midline septum
- Contains testis, epididymis, and lower part of a spermatic cord
- Dartos and cremaster muscles elevate the scrotal pouch
- Its external positioning keeps the testes 3°C lower than core body temperature (needed for sperm production)

The Scrotum

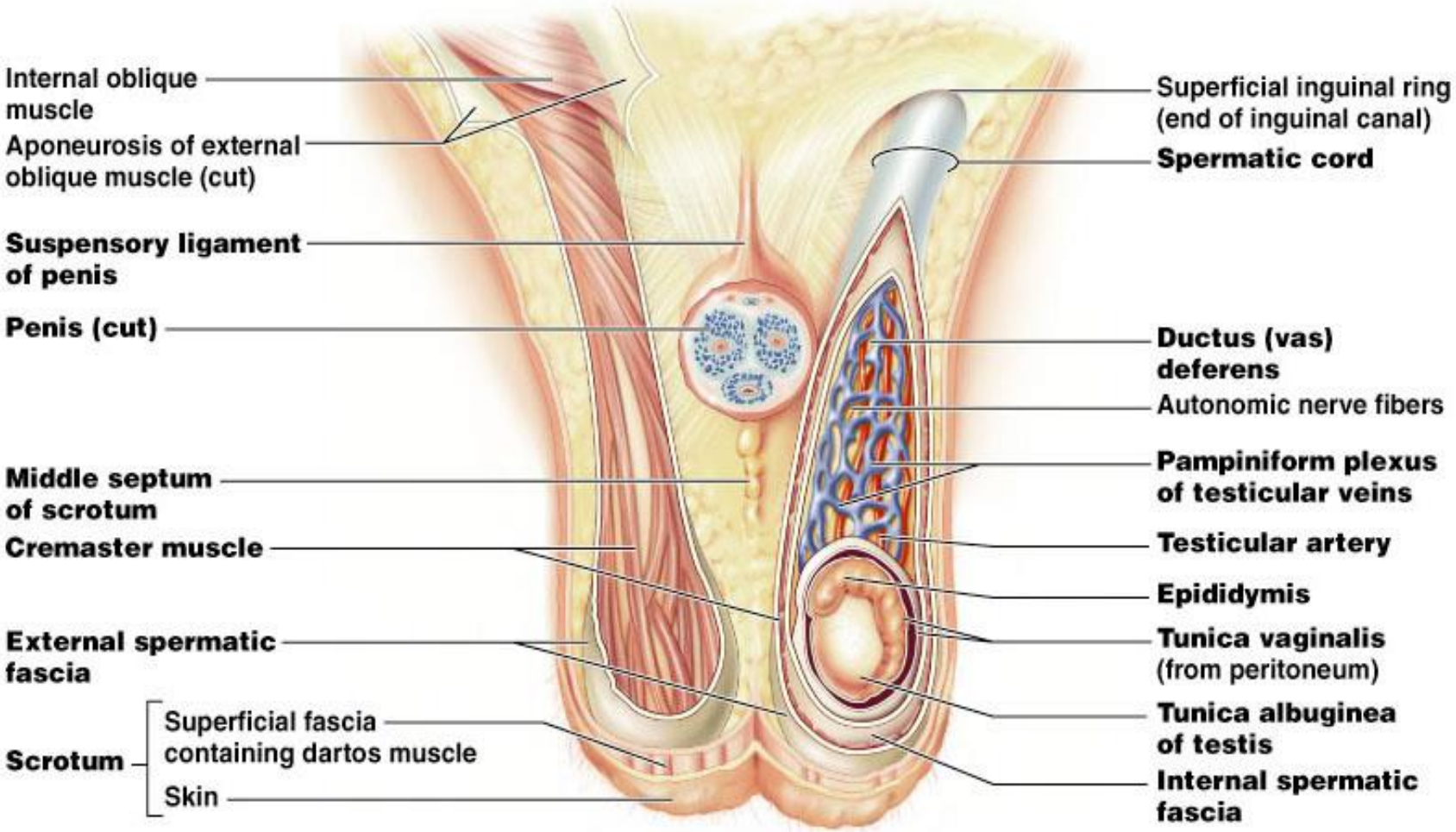
Internal oblique muscle
Aponeurosis of external oblique muscle (cut)
Suspensory ligament of penis
Penis (cut)
Middle septum of scrotum
Cremaster muscle
External spermatic fascia
Scrotum
Superficial fascia containing dartos muscle
Skin
Superficial inguinal ring (end of inguinal canal)
Spermatic cord
Ductus (vas) deferens
Autonomic nerve fibers
Pampiniform plexus of testicular veins
Testicular artery
Epididymis
Tunica vaginalis (from peritoneum)
Tunica albuginea of testis
Internal spermatic fascia

Penis & Scrotum

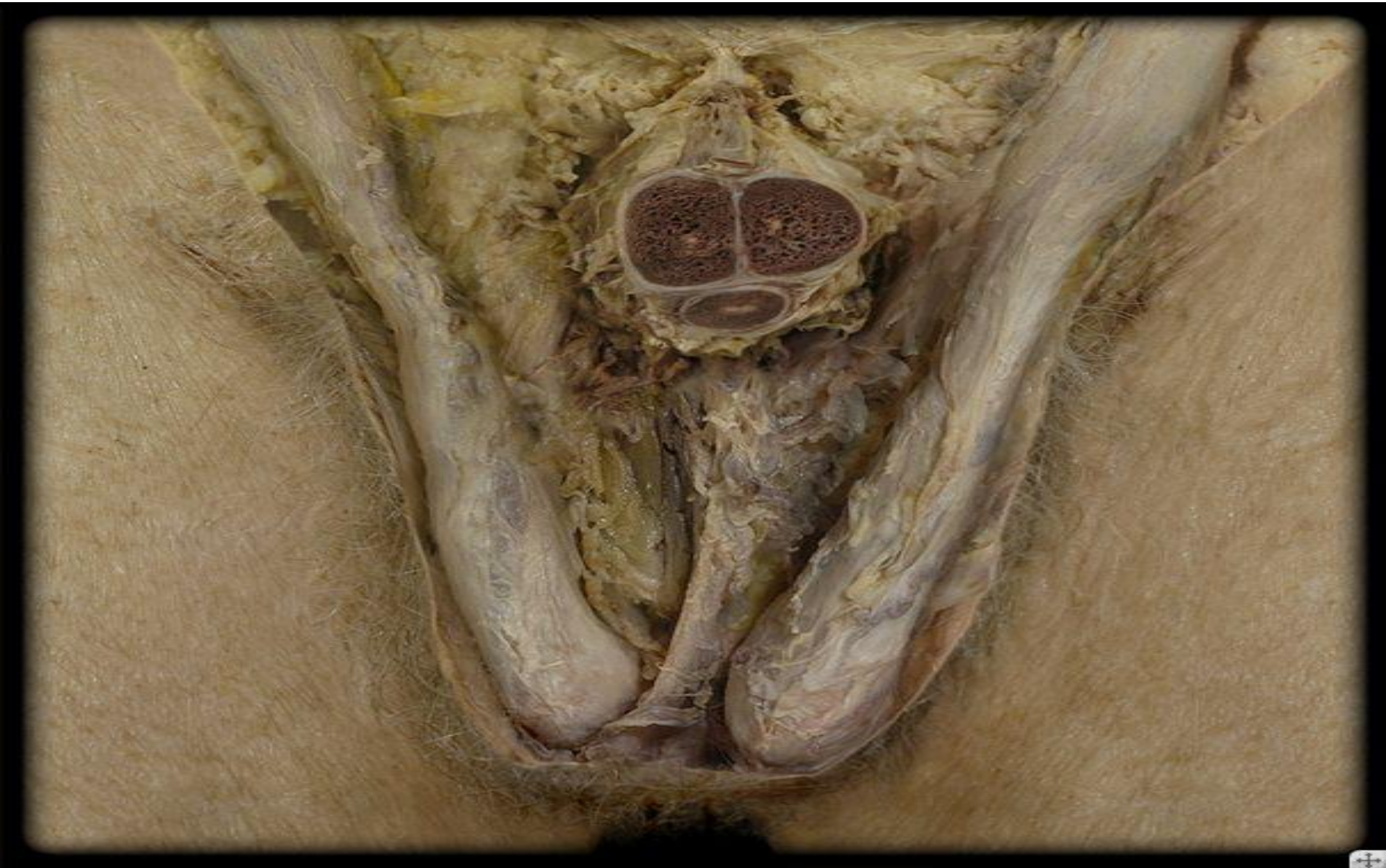

Penis & Scrotum - Cutaway

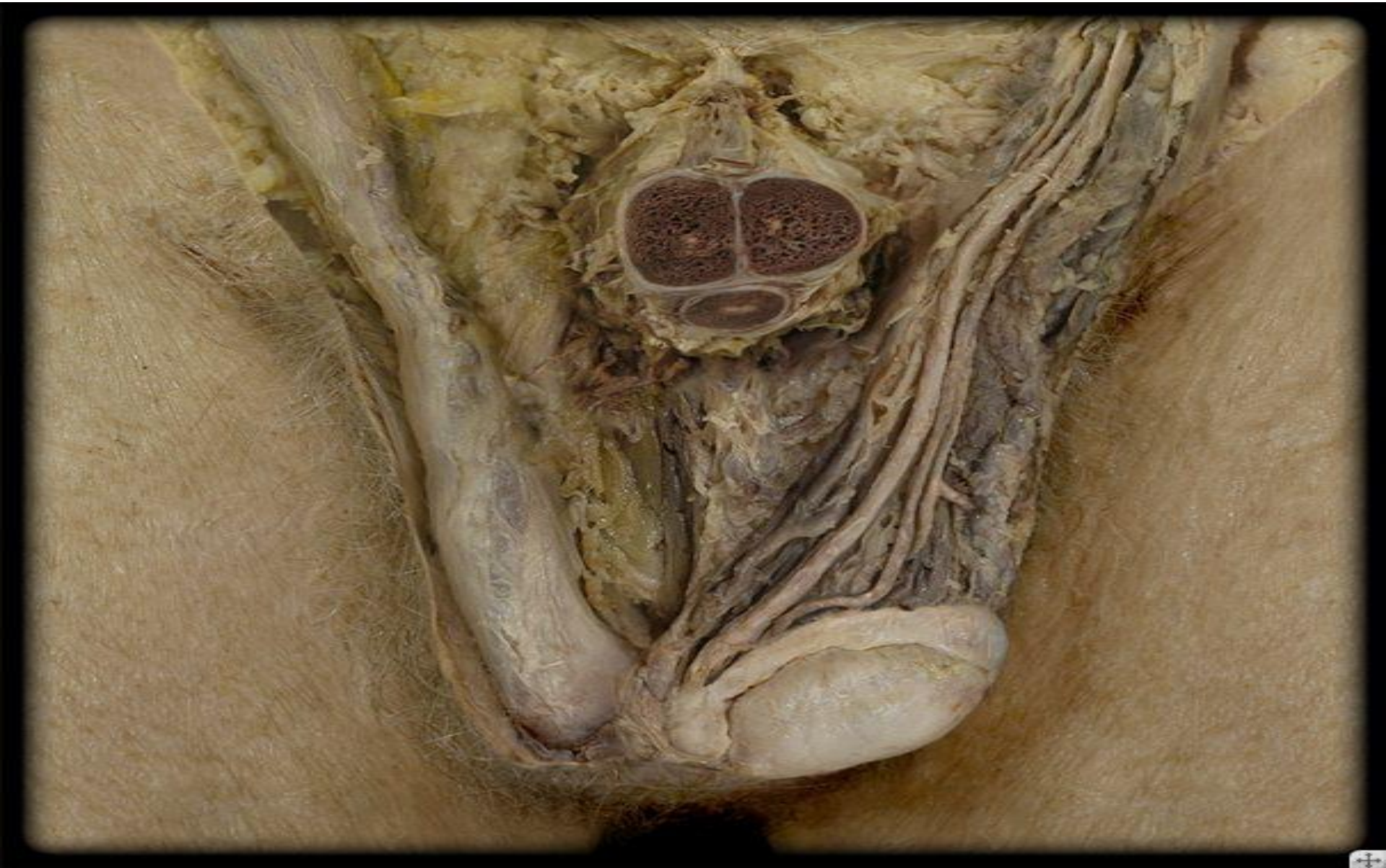

The Testes

- Located in scrotum, one testis in each of two scrotal compartments
- Each testis is surrounded by two tunics or layers
  - Tunica vaginalis – outer layer that is an outpocket of the peritoneum
  - Tunica albuginia – “white coat” is deep serous layer
- Septa (walls) divide the testis into 250-300 lobules, each containing 1-4 seminiferous tubules
  - Produce and carry the sperm

- The microscopic structure of the seminiferous tubules contains interstitial cells called Leydig cells
  - The interstitial cells produce androgens
- The seminiferous tubules are encased in fibrous capsule called the tunica albuginea
- Seminiferous tubules in testis open into a plexus called rete testis
- From the rete testis, the sperm:
  - Leave the testis via efferent ductules
  - Enter the epididymis

Brain Testicular Axis

- ***Hormonal regulation of spermatogenesis and testicular production***
  - ***Involves hypothalamus, ant pituitary and testis***
- ***Involves three hormones***
  - ***GnRH – gonadothrophic releasing hormoned stimulates testes***
  - ***FSH – causes tubules to produce sperm. Produces sertolli cells which supply nutrients and maintains hormone levels for developing sperm***
  - ***LH – acts on interstitial cells to produce testosterone***
- ***Maturation of the brain-testicular axis takes about 3 years and then stays fairly constant throughout life***

The Testes

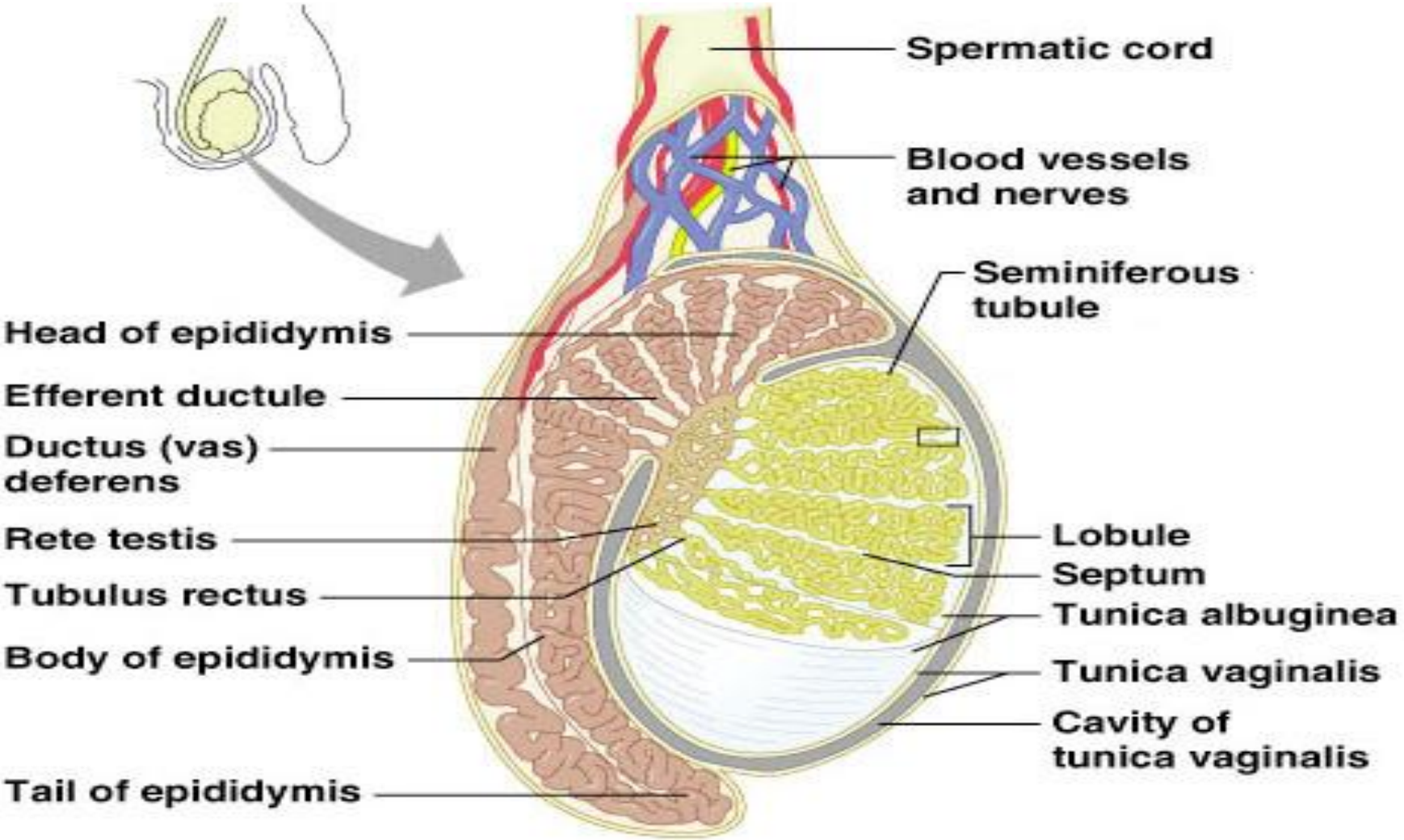
Spermatic cord
Blood vessels and nerves
Seminiferous tubule
Head of epididymis
Efferent ductule
Ductus (vas) deferens
Rete testis
Tubulus rectus
Body of epididymis
Tail of epididymis
Lobule
Septum
Tunica albuginea
Tunica vaginalis
Cavity of tunica vaginalis

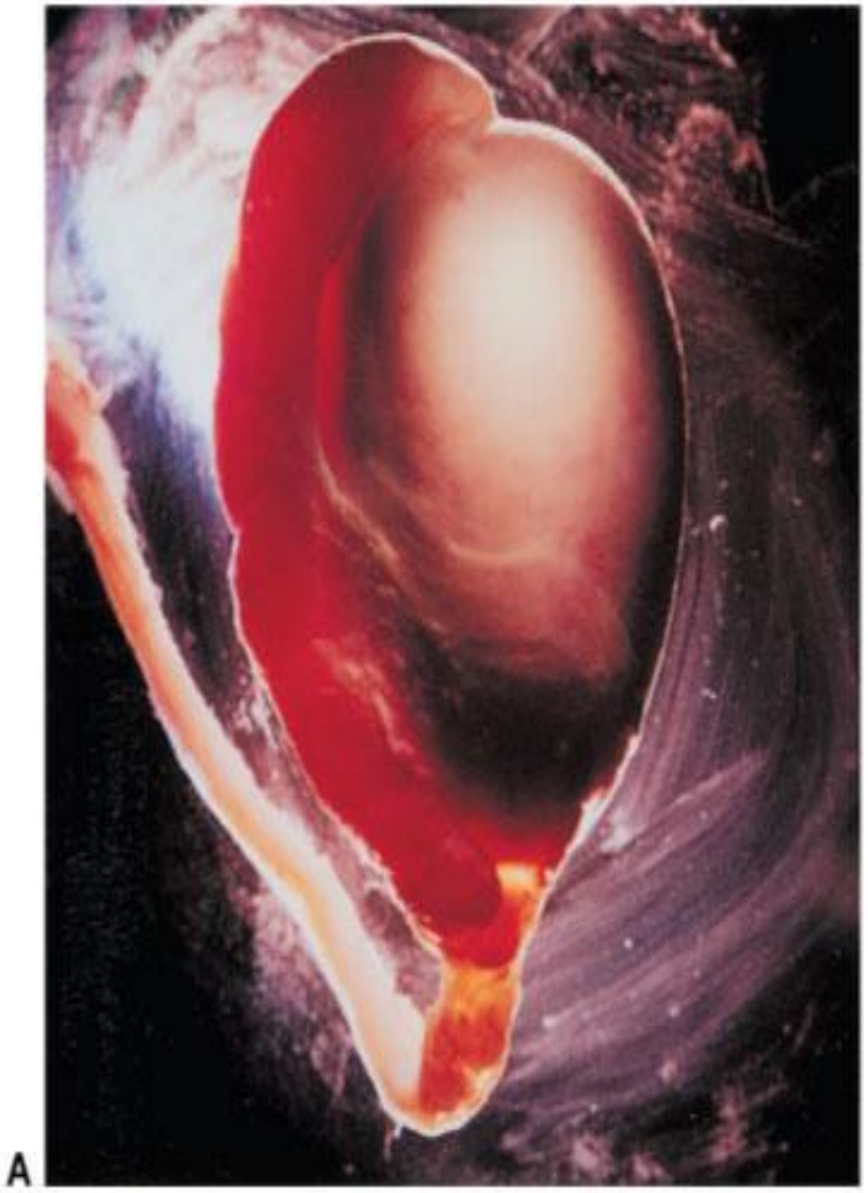

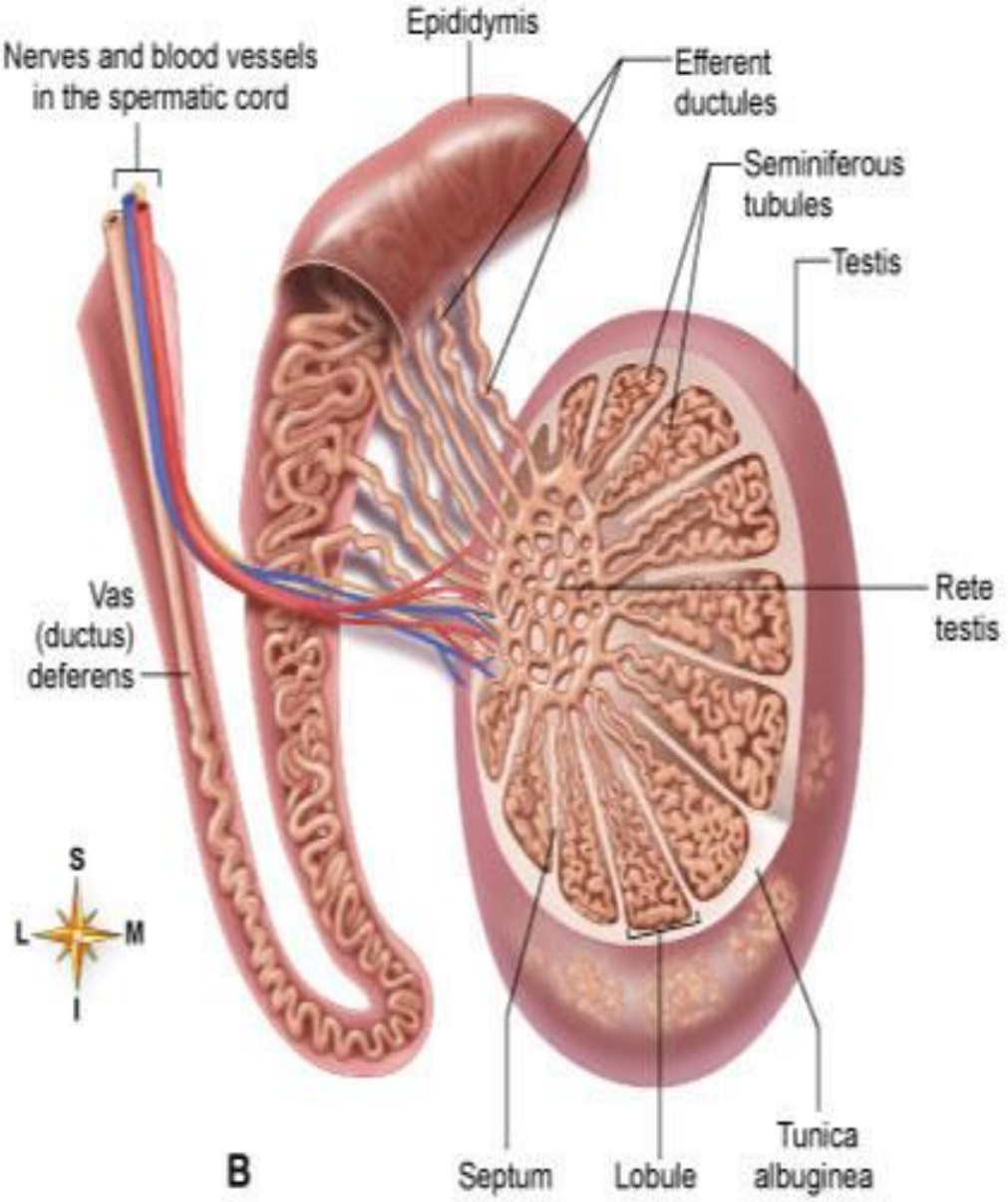

A: Lennart Nilsson.

Functions of Testes

- Spermatogenesis - formation of mature male gametes (spermatozoa) by seminiferous tubules
  - stimulated by FSH from the anterior pituitary
- Secretion of hormones by interstitial cells
  - Testosterone
  - Inhibin
  - Estrogen

- Testicular androgenic hormones
  - Testosterone
    - Type of androgen: maleness hormone
    - Secondary male sexual characteristics
    - Regulated by LH from anterior pituitary
  - Inhibin
    - Inhibits release of FSH by anterior pituitary
    - Allows the testis some control over spermatogenesis
  - Estrogen
    - Small amounts secreted by interstitial cells, liver, and other organs
    - Role in males uncertain but may influence spermatogenesis and other functions

Testicular Cancer

- Very rare cancer (<1% of all cancers), but most common cancer of young men
- Most common risk factor – cryptorchidism (undesended testicle)
- 7000 cases per year with 300 death per year
- 90% success rate with orchidectomy

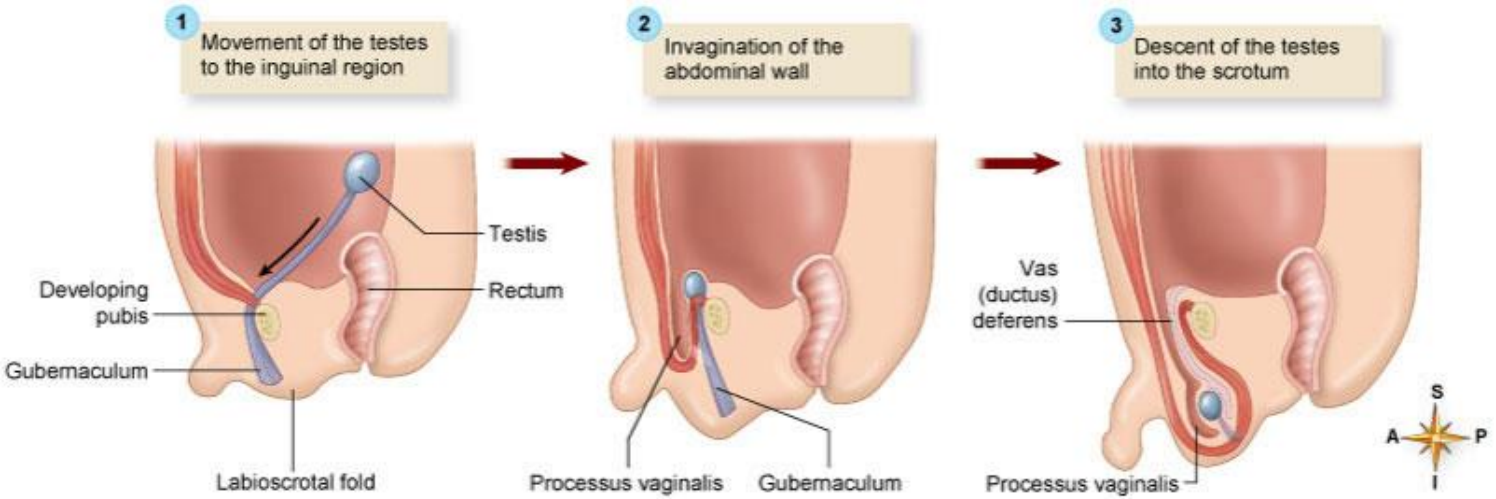

Adapted from Boron W, Boulpaep E: *Medical physiology*, updated version, ed 1, Philadelphia, 2005, Saunders.

Fig. 31-16. **Descent of the testes.** Prior to birth, the testes move from their retroperitoneal location near the kidneys and through the inguinal canal to the scrotum.

Testes & Spermatic Cord

Testes & Spermatic Cord - Cutaway

Spermatogenesis

- The sequence of events that produces sperm in the seminiferous tubules of the testes
- Each cell has two sets of chromosomes (one maternal, one paternal)
- Humans have 23 pairs of chromosomes
- Spermatogenesis begins at puberty and continues throughout life
- Healthy adult male produces 400 million sperm per day

ACROSOME
- BURROUGHS INTO EGG

HEAD
- CONTAINS DNA
- REPRESENTS NUCLEUS

BODY
- CONTAINS MITOCHONDRIA
- PROVIDES ENERGY FOR TAIL MOVEMENT

TAIL
- PROPELS SPERM
- 3 MM PER HOUR

Spermatogenesis

- Sperm have three major regions
  - Head – contains DNA and has a helmetlike acrosome containing hydrolytic enzymes that allow the sperm to penetrate and enter the egg
  - Midpiece – contains mitochondria spiraled around the tail filaments
  - Tail – a typical flagellum produced by a centriole



Spermatogenesis

Takes 64 to 72 Days

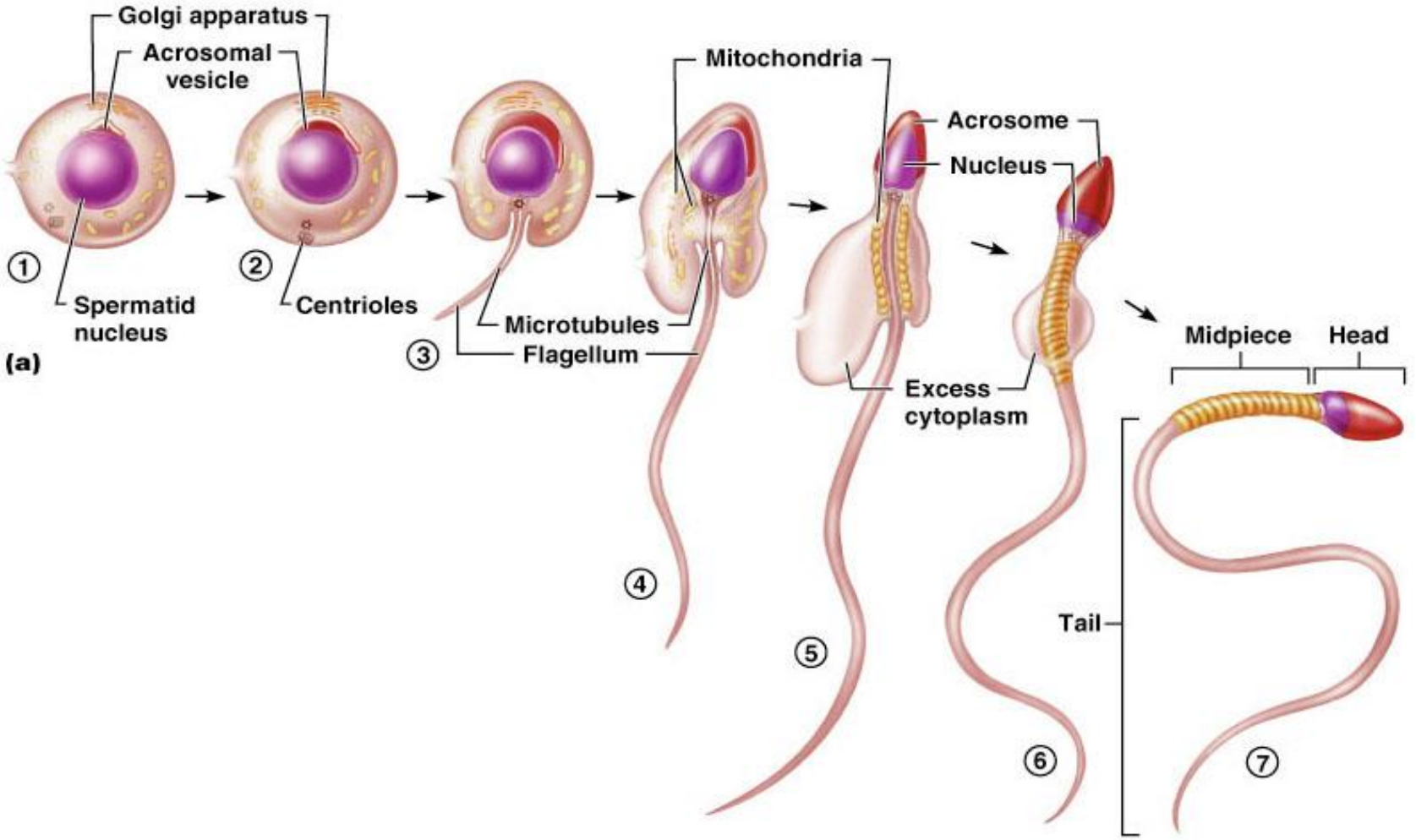

SPERM FORMATION & TRAVEL

SEMINIFEROUS TUBULES

↓

TUBULUS RECTUS

↓

RETE TESTES

↓

EFFERENT DUCTULE

↓

EPIDIDYMIS "UPON TESTIS"
- 20' LONG & WOUND UP 1½"
- STORES & NOURISHES SPERM

↓

VAS DEFERENS - DUCTUS DEFERENS
- 18" LONG
- STRONG MUSCULAR TUBE THATS CONTRACTS WITH EJACULATION

↓

EJACULATORY DUCT

↓

PROSTATIC URETHRA

Male Secondary Sex Characteristics

- Male hormones make their appearance at puberty and induce changes in nonreproductive organs, including
  - Appearance of pubic, axillary, and facial hair
  - Enhanced growth of the chest and deepening of the voice
  - Skin thickens and becomes oily
  - Bones grow and increase in density
  - Skeletal muscles increase in size and mass
- Testosterone is the basis of libido in both males and females

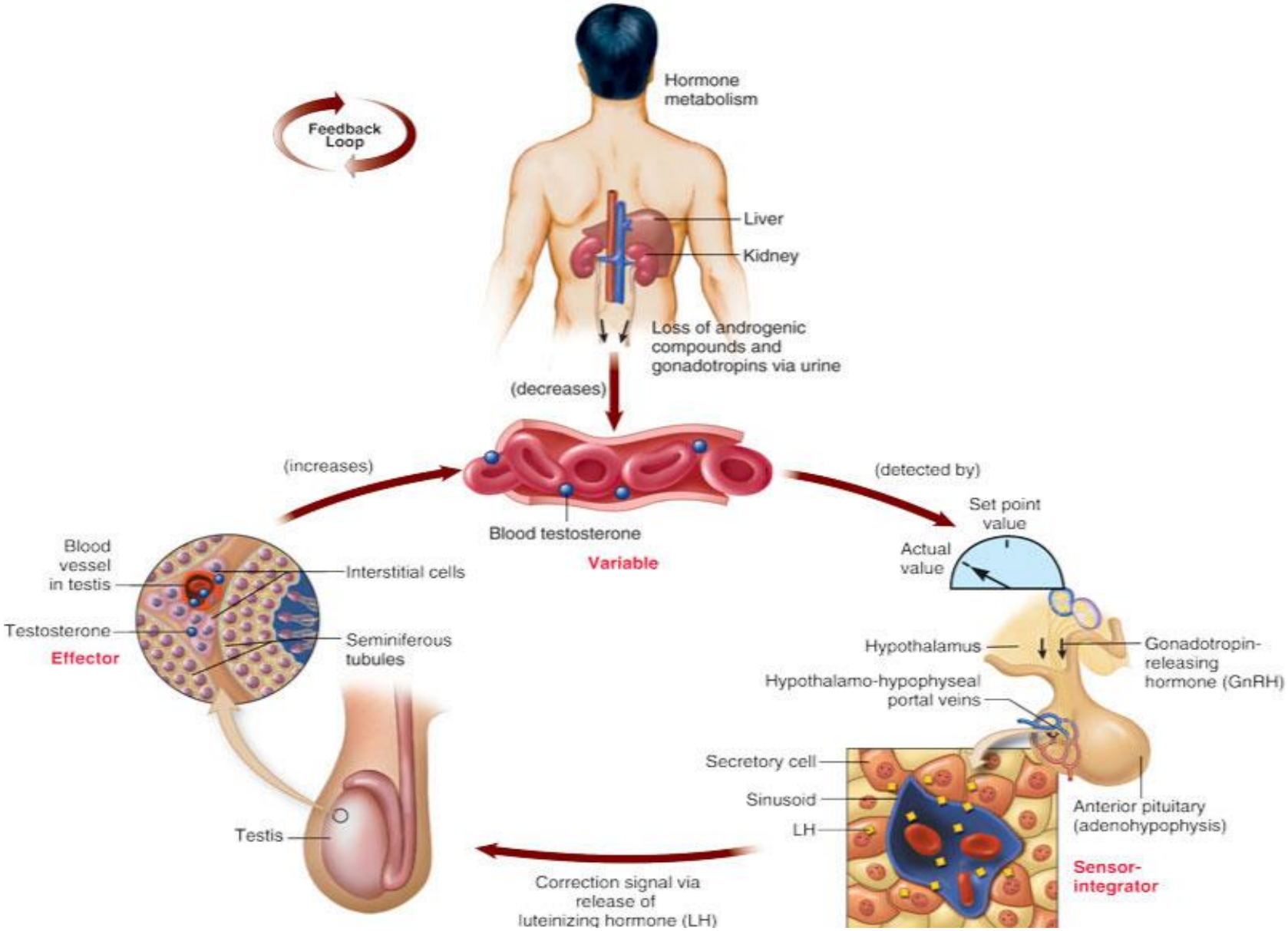
Feedback Loop
Hormone metabolism
Liver
Kidney
Loss of androgenic compounds and gonadotropins via urine
(decreases)
(increases)
(detected by)
Blood testosterone
Variable
Set point value
Actual value
Blood vessel in testis
Interstitial cells
Testosterone
Effector
Seminiferous tubules
Hypothalamus
Gonadotropin-releasing hormone (GnRH)
Hypothalamo-hypophyseal portal veins
Secretory cell
Sinusoid
LH
Anterior pituitary (adenohypophysis)
Sensor-integrator
Testis
Correction signal via release of luteinizing hormone (LH)

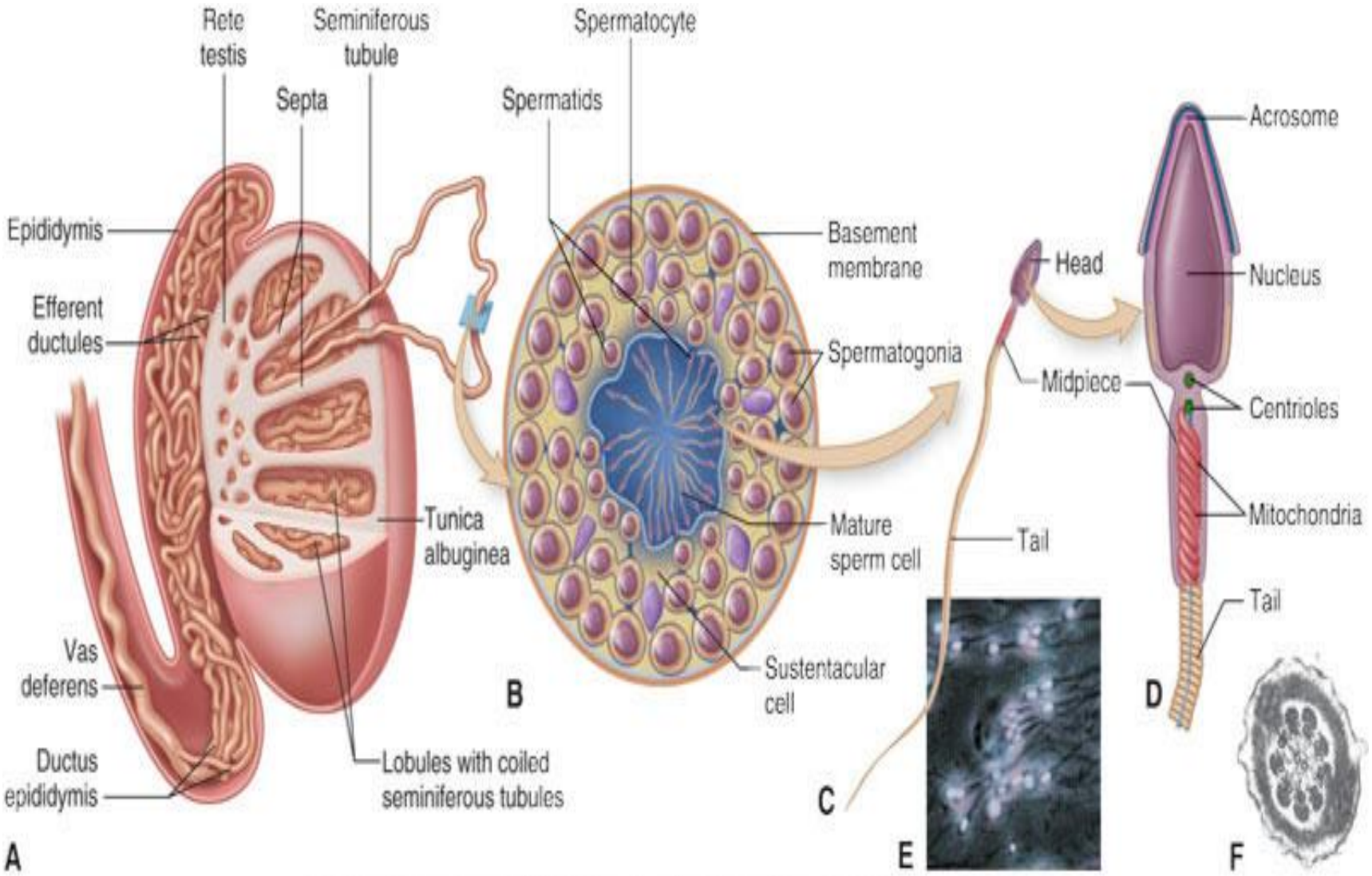
Rete testis
Seminiferous tubule
Septa
Epididymis
Efferent ductules
Tunica albuginea
Vas deferens
Ductus epididymis
Lobules with coiled seminiferous tubules
A
Spermatocyte
Spermatids
Basement membrane
Spermatogonia
Mature sperm cell
Sustentacular cell
B
Head
Midpiece
Tail
C
Acrosome
Nucleus
Centrioles
Mitochondria
Tail
D
E
F


I take it you haven't had sex for a while
NORMAL SPERM
YOUR SPERM

The Penis

- Composed of three cylindrical masses of erectile tissue, one of which contains urethra
- Functions
  - Contains the urethra, the terminal duct for both urinary and reproductive tracts
  - Penetrating copulatory organ during sexual intercourse

The Penis

- Consists of an attached root and a free body that ends in the glans penis or head
- Prepuce, or foreskin – cuff of skin covering the distal end of the penis
- Internal penis – the urethra and three cylindrical bodies of erectile tissue
- Erectile tissue – spongy network of connective tissue and smooth muscle riddled with vascular spaces
- Corpus spongiosum – surrounds the urethra and expands to form the glans and bulb of the penis

The Penis

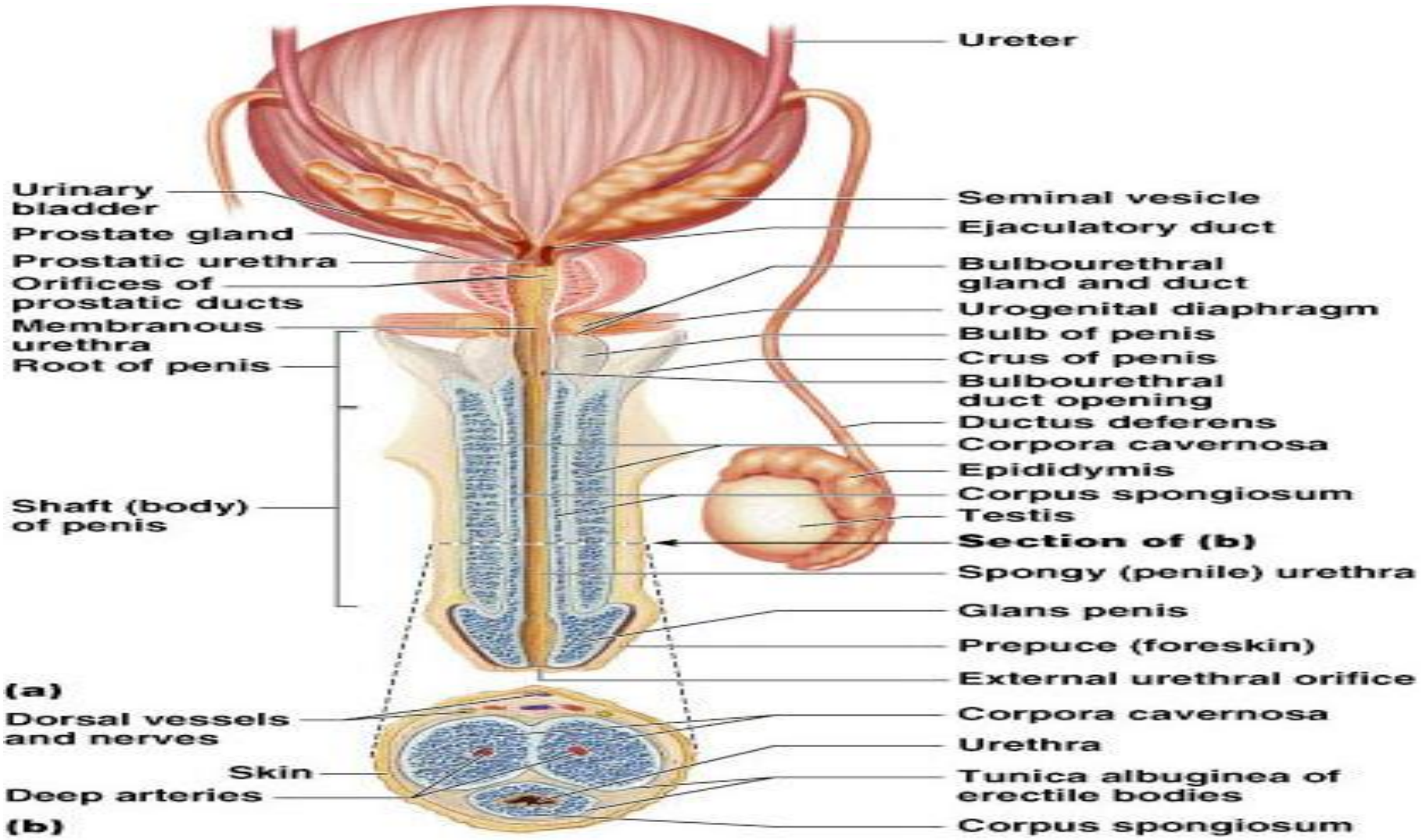
Ureter
Urinary bladder
Prostate gland
Prostatic urethra
Orifices of prostatic ducts
Membranous urethra
Root of penis
Shaft (body) of penis
(a)
Dorsal vessels and nerves
Skin
Deep arteries
(b)
Seminal vesicle
Ejaculatory duct
Bulbourethral gland and duct
Urogenital diaphragm
Bulb of penis
Crus of penis
Bulbourethral duct opening
Ductus deferens
Corpora cavernosa
Epididymis
Corpus spongiosum
Testis
Section of (b)
Spongy (penile) urethra
Glans penis
Prepuce (foreskin)
External urethral orifice
Corpora cavernosa
Urethra
Tunica albuginea of erectile bodies
Corpus spongiosum

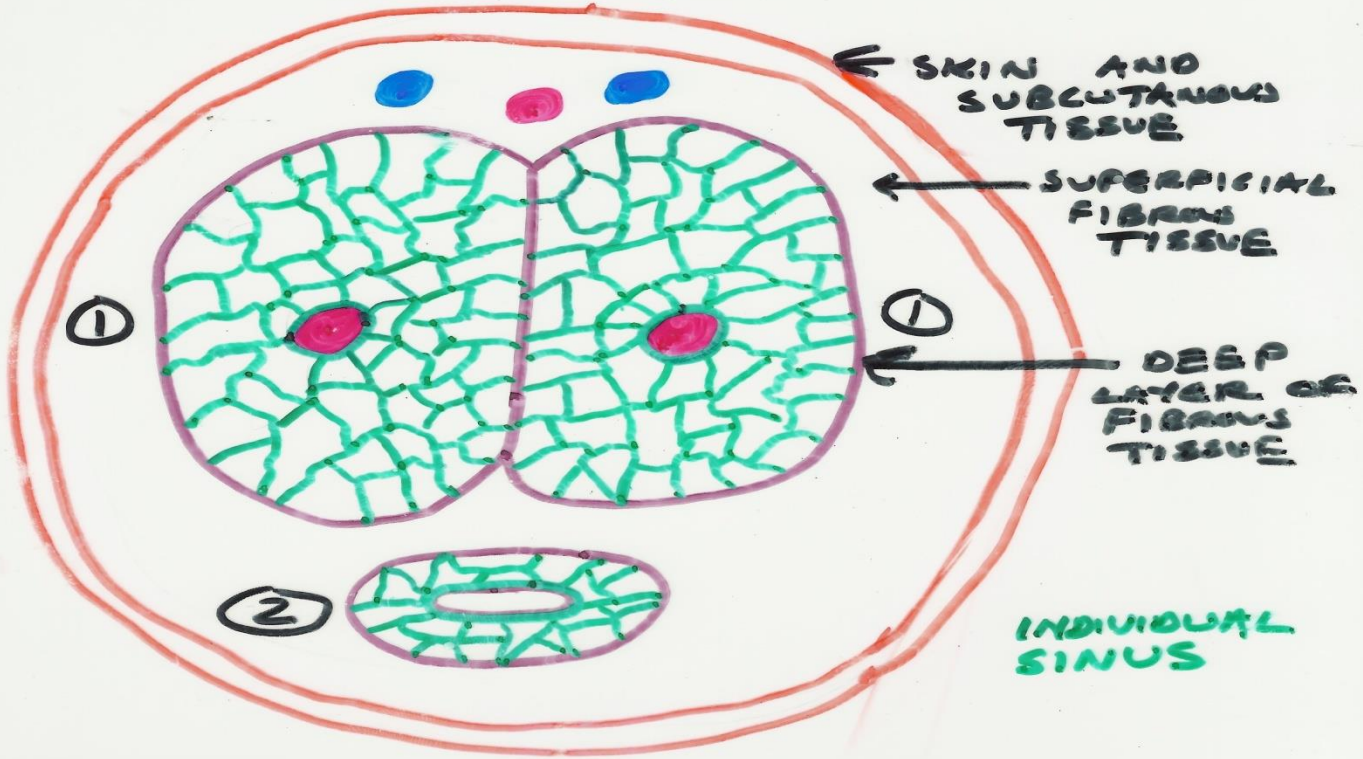

1. CORPORA CAVERNOSA
   - WITH DEEP ARTERY OF PENIS
2. CORPORA SPONGIOSUM
   - WITH LUMEN OF URETHRA

PARASYMPATHETIC STIMULATION

→ 50 cc BLOOD

MALE DUCT SYSTEM

SEMINAL VESICLES
VAS DEFERENS
EJACULATORY DUCTS
PROSTATE GLAND
UROGENITAL DIAPHRAGM

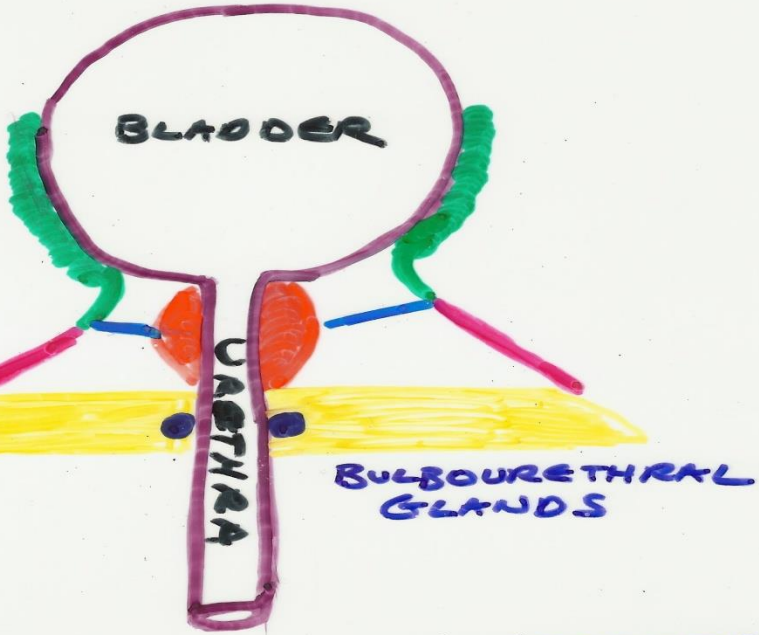

SEMEN IS MADE FROM 3 GLAND SECRETIONS:

SEMINAL VESICLES
- ON POSTERIOR BLADDER
- 60% OF SEMEN
- PROVIDES FRUCTOSE TO NOURISH SPERM

PROSTATE GLAND
- SIZE OF WALNUT
- SURROUNDS PROSTATIC URETHRA
- 15% - 30% OF SEMEN
- ACTIVATES SPERM

BULBOURETHRAL GLANDS
- PEA SIZED
- NEUTRALIZES ACID IN URETHRA

Epididymis

- Structure and location
  - Single tightly coiled tube enclosed in fibrous casing
  - Lies along top and side of each testis
  - Anatomical divisions include head, body, and tail
- Functions
  - Duct for seminal fluid
  - Also secretes part of seminal fluid
  - Sperm become capable of motility while they are passing through the epididymis

Epididymis

- Its head joins the efferent ductules and caps the superior aspect of the testis
- Nonmotile sperm enter, pass through its tubes and become motile (it takes about 20 days)
- If the epididymus ducts were uncoiled, it would be about 20 feet long
- Upon ejaculation the epididymis contracts, expelling sperm into the vas deferens

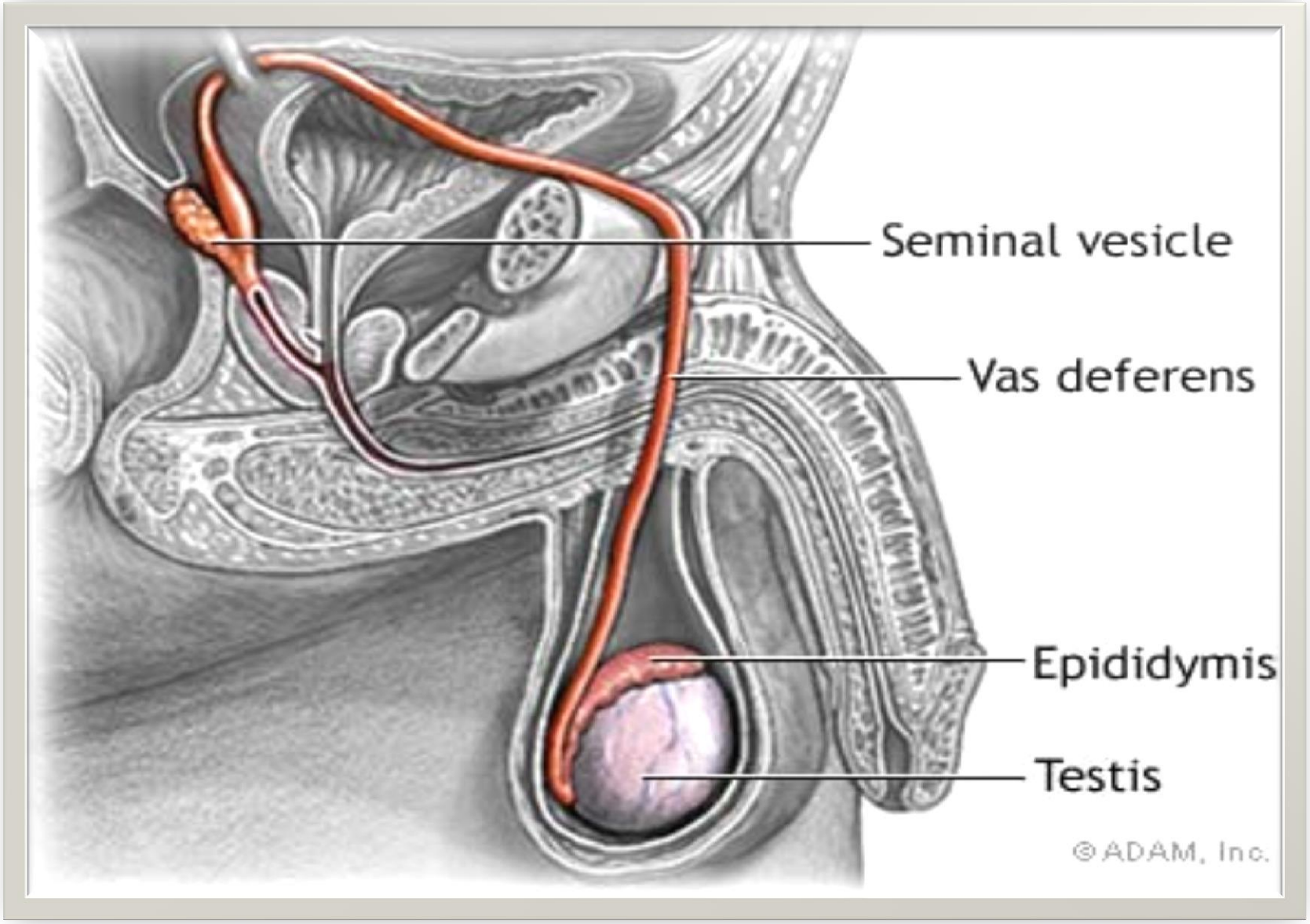
Seminal vesicle
Vas deferens
Epididymis
Testis
©ADAM, Inc.

Vas Deferens
Ductus Deferens

- Runs from the epididymis through the inguinal canal into the pelvic cavity then joins the duct of the seminal vesicle to form the ejaculatory duct
- Is approximately 18 inches long
- Propels sperm from the epididymis to the urethra
- Vasectomy – cutting and ligating the ductus deferens, which is a nearly 100% effective form of birth control
  - Vasovasotomy – vasectomy reversal

Vas Deferens

- Vas deferens (ductus deferens)
  - Structure and location
    - Tube, extension of epididymis
    - Extends through inguinal canal, into abdominal cavity, over top and down posterior surface of bladder
    - Enlarged terminal portion called ampulla; joins duct of seminal vesicle
  - Function
    - Excretory duct for seminal fluid
    - Connects epididymis with ejaculatory duct

Urethra

- Conveys both urine and semen
- Consists of three regions
  - Prostatic – portion surrounded by the prostate
  - Membranous – lies in the urogenital diaphragm
  - Spongy, or penile – runs through the penis and opens to the outside at the external urethral orifice

URETHRA

- CONVEYS BOTH URINE & SEMEN

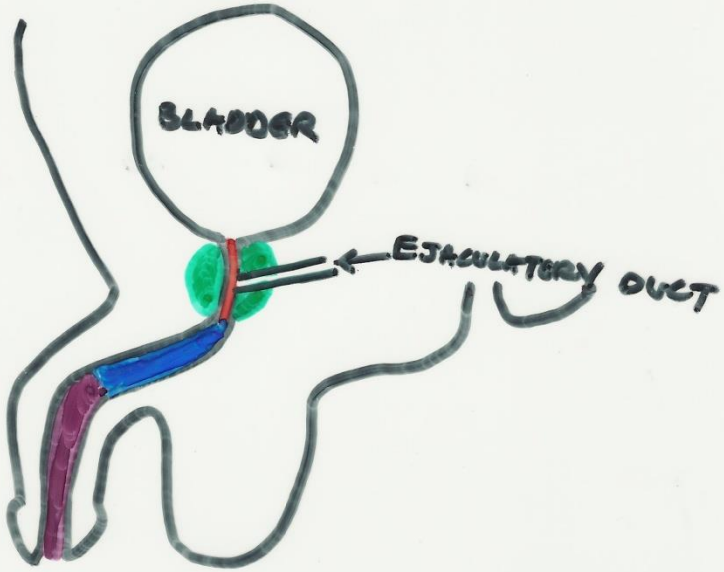

PROSTATIC URETHRA

MEMBRANOUS URETHRA

- LIES IN UROGENITAL DIAPHRAGM

SPONGY OR PENILE URETHRA

- THROUGH PENIS TO EXTERNAL URETHRAL ORIFICE

Accessory Glands

- Seminal Vesicles
  - Secrete 60% of the volume of semen
  - Join the vas deferens to form the ejaculatory duct
  - Sperm and seminal fluid mix in the ejaculatory duct and enter the prostatic urethra during ejaculation
- Prostate Gland
  - Encircles part of the urethra inferior to the bladder
  - Doughnut shaped
  - Plays a role in the activation of sperm
  - Function: adds slightly acidic, watery, milky-looking secretion to seminal fluid (30% of semen volume)

Accessory Glands

- Bulbourethral Glands (Cowper's Glands)
  - Structure and location
    - Small, pea-shaped structures with approximately 2.5-cm long (1 inch) ducts leading into urethra
    - Lie below prostate gland
  - Function: secrete alkaline fluid that is part of semen (5% of semen volume)
  - Produce thick, clear mucus prior to ejaculation that neutralizes traces of acidic urine in the urethra

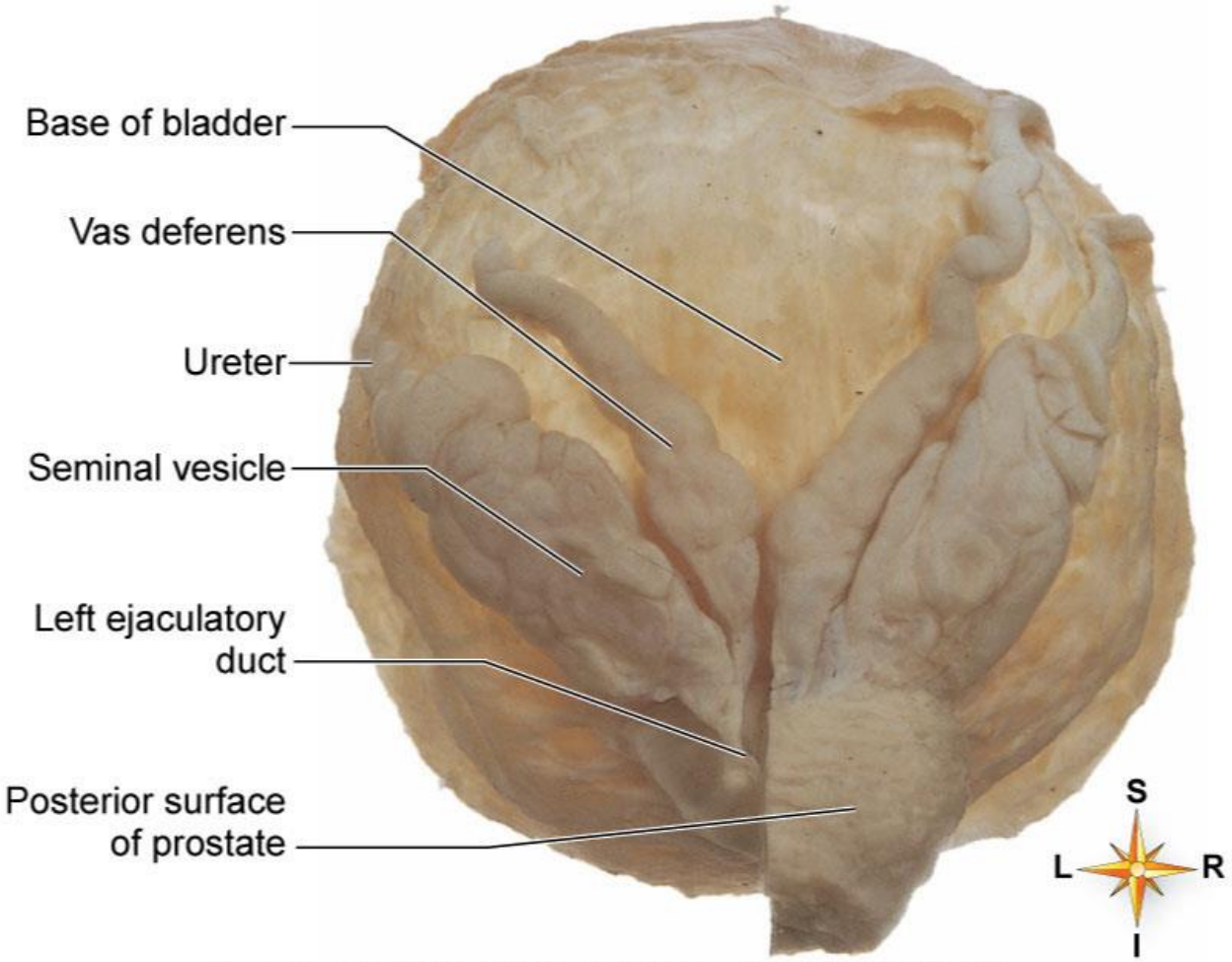

From Abrahams P, Marks S, Hutchings R: *McMinn's color atlas of human anatomy*, ed 5, Philadelphia, 2003, Mosby.

Fig. 31-12. **Prostate and related structures.** Cadaver dissection showing the prostate gland and other male reproductive structures viewed from behind. The prostate has been sectioned on the left side to reveal the ejaculatory duct.

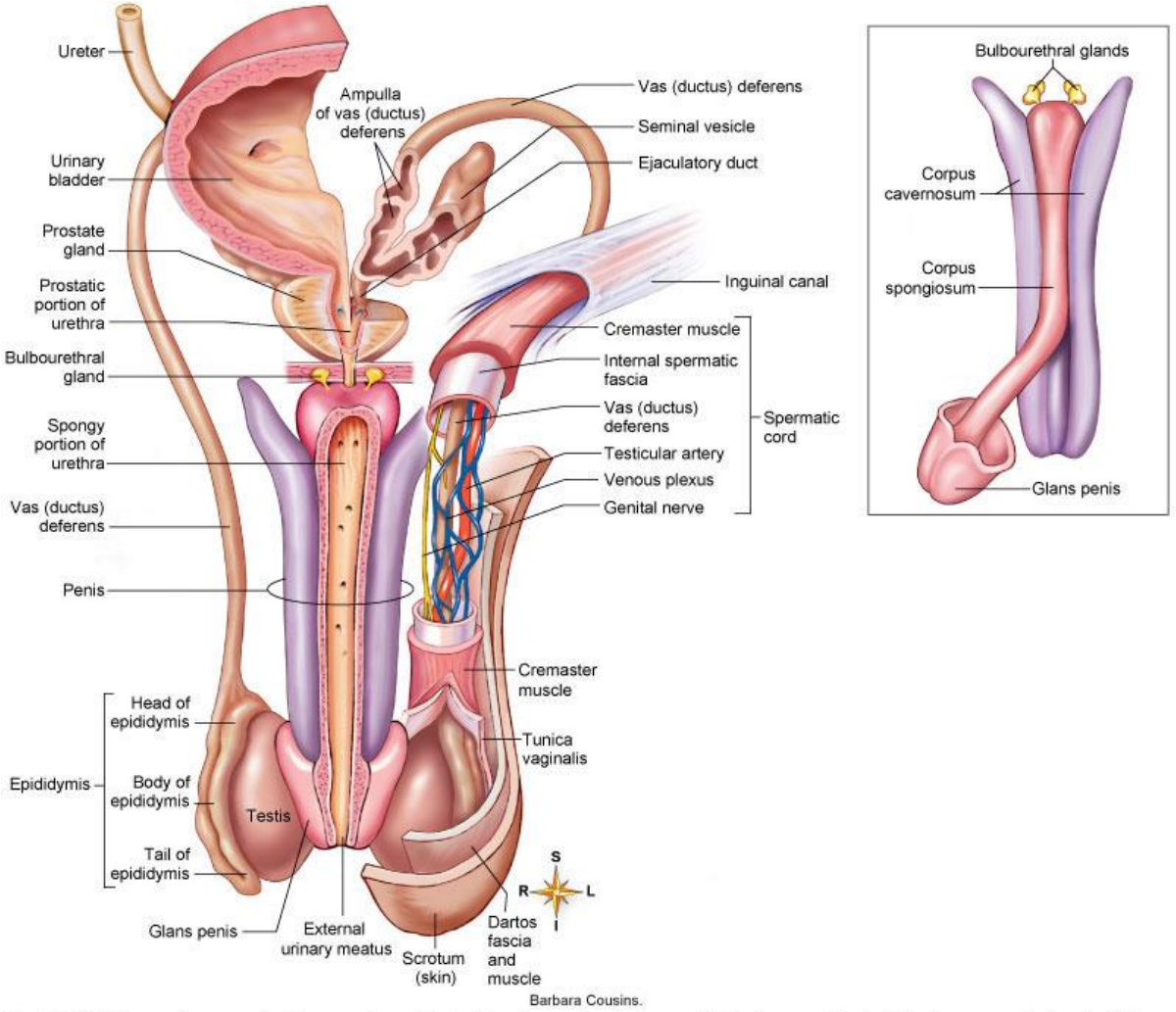

Fig. 31-11. **The male reproductive system.** Illustration shows the testes, epididymis, vas (ductus) deferens, and glands of the male reproductive system in an isolation/dissection format.

Semen

- Provides a transport medium and nutrients, protects and activates sperm, and facilitates their movement
- Prostaglandins in semen:
  - Decrease the viscosity of mucus guarding the cervix
  - Stimulate reverse peristalsis in the uterus
  - Facilitate the movement of sperm through the female reproductive tract
  - The relative alkalinity of semen neutralizes the acid environment found in the male urethra and female vagina
- Only 2-5 ml of semen are ejaculated, but it contains 50-130 million sperm/ml

Erection

- Engorgement of spongy erectile bodies with blood during stimulation
- Under the control of parasympathetic control which releases nitrous oxide (NO_2), which relaxes vascular smooth muscle causing the arterioles to dilate
  - Cavernous bodies fills with 50 cc blood
  - The erection blocks the venous flow from the penis after the cavernous bodies engorge

HEY, LOVER BOY! YOU DROPPED A VIAGRA ON THE FLOOR AGAIN!


Reynolds
That's odd. This bottle of Viagra was full two days ago.

Ejaculation

- The propulsion of semen from the male duct system
- At ejaculation, sympathetic nerves serving the genital organs cause:
  - Reproductive ducts and accessory organs to contract and empty their contents
  - The bladder sphincter muscle to constrict, preventing the expulsion of urine
  - Bulbospongiosus muscles to undergo a rapid series of contractions
  - Propulsion of semen from the urethra

Composition and Course of Seminal Fluid

- Consists of secretions from testes, epididymides, seminal vesicles, prostate, and bulbourethral glands
- Each milliliter contains millions of sperm
- Passes from testes through epididymis, vas deferens, ejaculatory duct, and urethra

Male Fertility

- Relates to many factors: number, size, shape, and motility of sperm
- Infertility may be caused by antibodies some men make against their own sperm
- Male fertility begins at puberty and extends into old age

Cycle of Life: Male Reproductive

- Reproductive functions begin at time of puberty
- Development of organs begins before birth; immature testes descend into scrotum before or shortly after birth
- Puberty: high levels of hormones stimulate final stages of development
- System operates to permit reproduction until advanced old age
- Late adulthood: gradual decline in hormone production may decrease sexual appetite and fertility